



# MONASH University

## The Morphology of an Ideal Trapezial Implant for Base of Thumb Arthritis

Aparna Dasunmalee Ganhewa  
MBChB

A thesis submitted for the degree of Master of surgery at  
Monash University in 2019

Department of Surgery, Monash Medical Centre, Monash Health  
Department of Surgery, Frankston Hospital, Peninsula Health  
Monash University Faculty of Medicine, Nursing and Health Science

## **Copyright notice**

© Aparna Dasunmalee Ganhewa (2019).

I certify that I have made all reasonable efforts to secure copyright permissions for third-party content included in this thesis and have not knowingly added copyright content to my work without the owner's permission.

# TABLE OF CONTENTS

<b>TABLE OF CONTENTS</b> .....	3
ABSTRACT.....	6
DECLARATION .....	8
ACKNOWLEDGEMENTS .....	10
ABBREVIATIONS .....	11
INTRODUCTION: .....	13
Functional significance of the thumb.....	13
Osteoarthritis of the base of the thumb.....	15
Epidemiology .....	15
Signs and symptoms.....	16
Diagnosis and Staging .....	17
Conservative management .....	19
Surgical management.....	20
Systematic review: Failure rates of non-implant arthroplasty surgery for base of thumb arthritis	28
Introduction.....	28
Methods.....	28
Results.....	30
Discussion .....	31
Conclusion.....	32
Trapezial Implants .....	32
Interposition .....	33
Implants post total trapeziectomy.....	33
Implants post partial trapezial resection .....	43
Total joint replacements.....	50
Hemiarthroplasty.....	64
Rationale for Research.....	68
Aims and Research Hypothesis .....	68
CHAPTER 2: Complications of trapeziometacarpal implants: A systematic review .....	70
Introduction .....	71
Methods: .....	72
Inclusion Criteria .....	72
Exclusion Criteria.....	72
Information source and Search strategy.....	72
Study selection .....	72
Data Items .....	73
Data collection process.....	73
Synthesis of results.....	73
Identification of implants with high failure rates and unfavourable morphology.....	74

Results .....	76
Study selection .....	76
Study Characteristics .....	76
Identified implants: .....	79
Complications: .....	81
Discussion .....	120
Aseptic Loosening.....	120
Dislocation .....	121
Persistent pain .....	122
Foreign body reaction .....	123
Implant Fracture.....	124
Subluxation .....	125
Peri-prosthetic Fracture .....	125
Post-operative infection .....	126
Osteolysis, implant subsidence, periprosthetic ossification, radiological loosening, and implant resorption/wear .....	126
All cause failure .....	129
Limitations .....	129
Conclusion .....	132
CHAPTER 3: 3D printing and validation studies.....	135
Introduction .....	135
How to 3D print a trapezium .....	139
Validation studies .....	141
Methods:.....	142
Results.....	147
Discussion .....	152
Conclusion.....	155
CHAPTER 4: Anatomy of the trapezium and individual variation.....	157
Introduction .....	157
Morphology and functional anatomy .....	157
Biomechanics: forces and stability .....	164
Forces.....	166
Anatomical study of the trapezium and carpal bone size .....	168
Methods.....	169
Results.....	172
Discussion .....	188
Conclusion .....	195
CHAPTER 5: Discussion.....	198
Morphology of an ideal implant: A 3D printed trapezium .....	198
Adequate treatment of pain .....	199
Restoration of thumb stability .....	199

Restoration or improvement of thumb strength .....	200
Retention of thumb length .....	200
Correction of adduction deformity .....	201
No implant related complications .....	201
Acceptable failure rates .....	202
Operation technically feasible .....	203
Fast post operation recovery .....	204
Low cost of manufacture .....	205
Conclusion .....	206
REFERENCES: .....	208
Appendix 1 .....	231
Appendix 2 .....	235

## ABSTRACT

Osteoarthritis of the base of the thumb is a commonly encountered surgical problem particularly in the Caucasian, elderly and female populations. Many implant and non-implant-based surgical options are available for patients failing to respond to conservative management. However, each surgical option carries advantages and disadvantages. The main focus of the current thesis is to define the morphology of an ideal trapezial implant which would address the disadvantages of currently available surgical techniques to optimally treat base of thumb arthritis.

A systematic review of trapezial implant arthroplasty literature revealed that the design group with the lowest overall rates of failure were the implants used as a spacer post total trapeziectomy. The leading causes of failure within this group was dislocation and subluxation of the implants. Furthermore, implant failure due to persisting pain was also the lowest in this group of implants. Therefore, the basic morphology of an ideal implant was narrowed to one which should be used as an interposition spacer post total trapeziectomy.

A 3D printed implant with identical morphology to a native trapezium was proposed as an ideal trapezial implant. Such an implant satisfies the required basic design of an interposition spacer post total trapeziectomy. Validation studies were conducted to confirm *3D slicer* as an accurate software program to generate 3D surface models of trapeziums from CT wrist scans, which could then be used to 3D print a trapezial implant.

An anatomical study of the trapezium was conducted to find significant differences in trapezial volume between demographics. Statistically significant differences in trapezial volume was found between genders, increasing age and Eaton stage of Osteoarthritis.

Furthermore, linear regression analysis of the trapezium and other carpal bone volume showed the volume of the lunate was significantly correlated to the volume of the trapezium, and could potentially be used to estimate the volume of the trapezium. Correct implant sizing is crucial to implant stability; therefore, the results of the anatomical study were used to generate an algorithm for optimally sizing a 3D printed trapezium implant.

## DECLARATION

This thesis contains no material which has been accepted for the award of any other degree or diploma at any university or equivalent institution and that, to the best of my knowledge and belief, this thesis contains no material previously published or written by another person, except where due reference is made in the text of the thesis.

**Aparna Dasunmalee Ganhewa**



## **Publications during enrolment**

1. Hunter-Smith DJ, Ganhewa AD, Wu R, Chae MP, Tobin V, Rozen WM. Mechanisms of failure in base of thumb implant arthroplasty: A systematic review. *Journal of Hand Surgery (European Volume)* 2018, Vol. 43(Supplement 2) SS107
2. Ganhewa AD, Wu R, Chae MP, Miller G, Tobin V, Rozen WM, Hunter-Smith DJ. The Complications of Trapeziometacarpal Implants for Base of Thumb Arthritis. *ANZ J. Surg.* 2018; 88(S1) 71-79
3. Ganhewa AD, Wu R, Chae MP, Tobin V, Rozen WM, Hunter-Smith DJ. 3D Printing in Surgical Planning and Research: A Validation Study. *ANZ J. Surg.* 2018; 88(S1) 71-79
4. Ganhewa AD, Chae MP, Tobin V, Rozen WM, Hunter-Smith DJ. Detailed Morphological Anatomy of the Human Trapezium: A Clinical Anatomical Study. *ANZ J. Surg.* 2018; 88(S1) 71-79

## **Accepted**

1. Ganhewa AD, Wu R, Chae MP, Miller G, Tobin V, Smith JA, Rozen WM, Hunter-Smith DJ. Failure rates of base of thumb arthritis surgery: A Systematic Review. *J Hand Surg Am.*

## ACKNOWLEDGEMENTS

Thank you seems too short a phrase to express the gratitude I feel for my much-loved supervisors Professor Warren Rozen, Associate Professor David Hunter-Smith and Professor Julian Smith. I am truly grateful and deeply indebted for their unwavering support, exceptional guidance and for being an endless fountain of inspiration throughout the project. I will always cherish and bring forth to future endeavours all that they have taught me during this research journey. Indeed, I was very lucky to have been their Masters student. Thank you again for everything.

I am deeply grateful for the research team at Frankston Hospital, department of surgery. Wednesday afternoon meetings were often the highlight of my week. Thank you for providing the curious, exciting and thought-provoking environment which allows research to flourish. I would like to especially thank Dr. Vicky Tobin for meticulously and tirelessly doing the statistical analysis for this project but more importantly for being an omnipresent source of encouragement and positivity. A special thank you also to my academic colleague and dear friend Dr. Michael Chae for providing an empathetic ear and motivating me to carry on even when going got tough.

Finally, to my husband, Harman Dhaliwal without the love and support of whom I would likely wither and die, rendering completion of the project completely impossible. I am ever grateful to you for continuously bringing laughter and warmth into my life, but more importantly your wizardry in excel spreadsheet. Thank you my dearest, this would not have been possible without you.

## ABBREVIATIONS

AOANJJR	Australian orthopaedic association national joint replacement registry
ADL	Activities of daily living
APL	Abductor pollicis longus
APB	Abductor pollicis brevis
BMI	Body mass index
CMC	Carpo-metacarpal
CAD	Computer aided design
DASH	Disability of arm, shoulder and hand
ECRL	Extensor carpi radialis longus
EPB	Extensor pollicis brevis
EPL	Extensor pollicis longus
FCR	Flexor carpi radialis
IA	Interposition arthroplasty
ICC	Interclass correlation co-efficient
ICMC	Intercarpo-metacarpal
IP	Interphalangeal
LR	Ligament reconstruction
LRTI	Ligament reconstruction and tendon interposition
MCP	Metacarpophalangeal
MoM	Metal on metal
MRI	Magnetic resonance imaging
NSAID	Non-steroidal anti-inflammatory drug
OA	Osteoarthritis
OCEBM	Oxford centre for evidence-based medicine
PEEK	Polyetheretherekone
PSI	Patient specific implants
PVA	Polyvinyl alcohol
PLLA	L-polylactic acid implant
RCT	Randomised controlled trial
ROA	Radiographic osteoarthritis
ROM	Range of movement
SM	Surface models
STT	Scapho-trapezio-trapezoid
TJR	Total joint replacement
TM	Trapeziometacarpal
TMI	Trapeziometacarpal implant/ Too much information
VAS	Visual analogue scale

# **CHAPTER 1**

## **Introduction**

## INTRODUCTION:

### Functional significance of the thumb

The thumb has been described as 'the intellectual part of the hand'.

~Nikola Tesla, A life from beginning to end

The quote above is best elaborated by the Homunculus. The homunculus is a distorted human figure which represents a neurological map of areas in the brain dedicated to sensory and motor functions of the body. It takes on a grotesque and somewhat comical appearance due its large hands and particularly large thumbs relative to the size of its trunk and lower limbs. The over representation of the thumbs highlights its importance. Relatively large areas of cortex are dedicated to processing its sensory, and especially, motor function. Therefore, the large areas dedicated to thumb movements enables highly dexterous and precise movements to be performed.

From an evolutionary point of view, it is argued that enlargement in brain size in the lineage leading to humans began as a result of using tools. Forceful and precise thumb opposition is essential for creation and manipulation of stone tools. Therefore, a strong and mobile thumb would have conferred a selective advantage. Previously unattainable food sources could now be attained. The thumb alone has been argued as a key element in human evolution and successful civilisation (1, 2).



**Figure 1. The Homunculus. Large hands and thumbs relative to the size of the trunk and lower limbs represent the larger areas of motor cortex dedicated to control of hand and thumbs. (Pixels.com, 13<sup>th</sup> Jan 2019)**

The thumbs carry enormous significance to our function in modern day life. It is relied upon continuously and facilitates all matter of tasks; from texting on a mobile phone, to tying shoe laces, to playing a musical instrument, to flipping a coin toss, to gently squeezing one's nose around an unpleasant aroma, to powerfully grappling an opponent into submission (such as in Greco-Roman wrestling). Although the examples given may go well beyond what constitutes activities of daily living, each demonstrates the range of functions the thumb is capable of, and responsible for: To have high

mobility and dexterity in opposition, precision pinch grip and forceful power grip. It is the manoeuvrability and opposability of the thumb that allows us to perform complex task and grasp objects of varying size and contour (3).

As such, injury or disease affecting the thumb leaves an individual with a significant functional impairment. An impairment which is of utmost importance to restore; the responsibility of which partly lies with the hand surgeon.

## Osteoarthritis of the base of the thumb

### Epidemiology

#### *Prevalence and associations*

Base of thumb Osteoarthritis (OA) is one of the most common diseases which effects the thumb. It poses a significant burden of disease and has a prevalence of 8% to 12% in the general population (4-6). It is the second most common site of degenerative joint disease in the hand and the most common site of arthritis in the thumb (7, 8). Base of thumb OA has a higher prevalence with increasing age, female gender, Caucasian ethnicity and increased BMI. It is strongly associated with increasing age, and as life expectancy increases base of thumb OA can be considered a normal part of aging. The radiographic evidence of base of thumb OA increases steadily from the age of 31 onwards. The prevalence study by Becker et al found that a 100% of women over 90 years, and 93% of men over 81 years had radiographic changes of basal thumb OA. Severity of arthritis also increased with age; 35% of women and 34% of men aged 81 years or older showing severe OA changes on x-ray. This increases to 50% of women over 90 years who have severe OA. Women are 1.3 times more likely to have radiographic evidence of OA, show earlier onset and greater severity of disease and have bilateral disease as compared to men (4, 9). An Increased prevalence of base of thumb OA is reported in Caucasian population. The study by Haara et al reports a prevalence of 15% in women and 7% in men in a Finnish population. In the same population, a higher body mass index (BMI) was directly correlated with the prevalence of base of thumb OA.

Obese (BMI > 35kg/m<sup>2</sup>) individuals had more than twice the risk as compared to individuals with a normal (20 -24.9kg/m<sup>2</sup>) BMI (4).

### *Clinically relevant disease*

It is apparent that the radiographic presence of OA is a common finding with majority of the population showing some changes with age. Therefore, a mismatch exists between radiologically and clinically significant disease. The study by Armstrong et al found only one third of post-menopausal women with radiologic OA had associated pain (10). The study by Dahaghin et al, showed only a modest association between the presence of radiographic OA and hand pain. However, individuals with hand pain were two times more likely to also have radiographic base of thumb OA. Similarly, the presence of radiologic OA has not been or only weakly shown to be associated with disability or work disability (4, 8, 9). Therefore, it is a subset of patients who present with symptoms and disability secondary to base of thumb OA requiring treatment or intervention.

### *Signs and symptoms*

Although it is a fraction of patients who suffer from symptoms of base of thumb OA, if present, they can range from intermittent aching to severe pain causing weakness and disability. Typically, patients present with diffuse pain at the base of thumb over the volar aspect over the thenar musculature (11, 12). The onset of pain may range from months to years and maybe exacerbated by certain activities requiring a pinch grip or thumb opposition, such as turning a key or using scissors (13). Instability of the thumb may also be present. Patients with instability may recall a loss of ability to do certain tasks such as twisting open the lid of a jar or using a manual can opener (14). The clinical findings on observation may include a dorso-radial prominence at the base of the thumb due to radial subluxation of the first-metacarpal, osteophyte formation and mild joint effusion. Patients with advanced disease may also have an adduction deformity with first web-space contracture. Secondary hyperextension of the metacarpophalangeal joint may develop in order to compensate for decreased abduction at the trapeziometacarpal (TM) joint. The combination of adduction deformity, metacarpophalangeal (MCP) joint hyperextension and resting interphalangeal (IP) joint



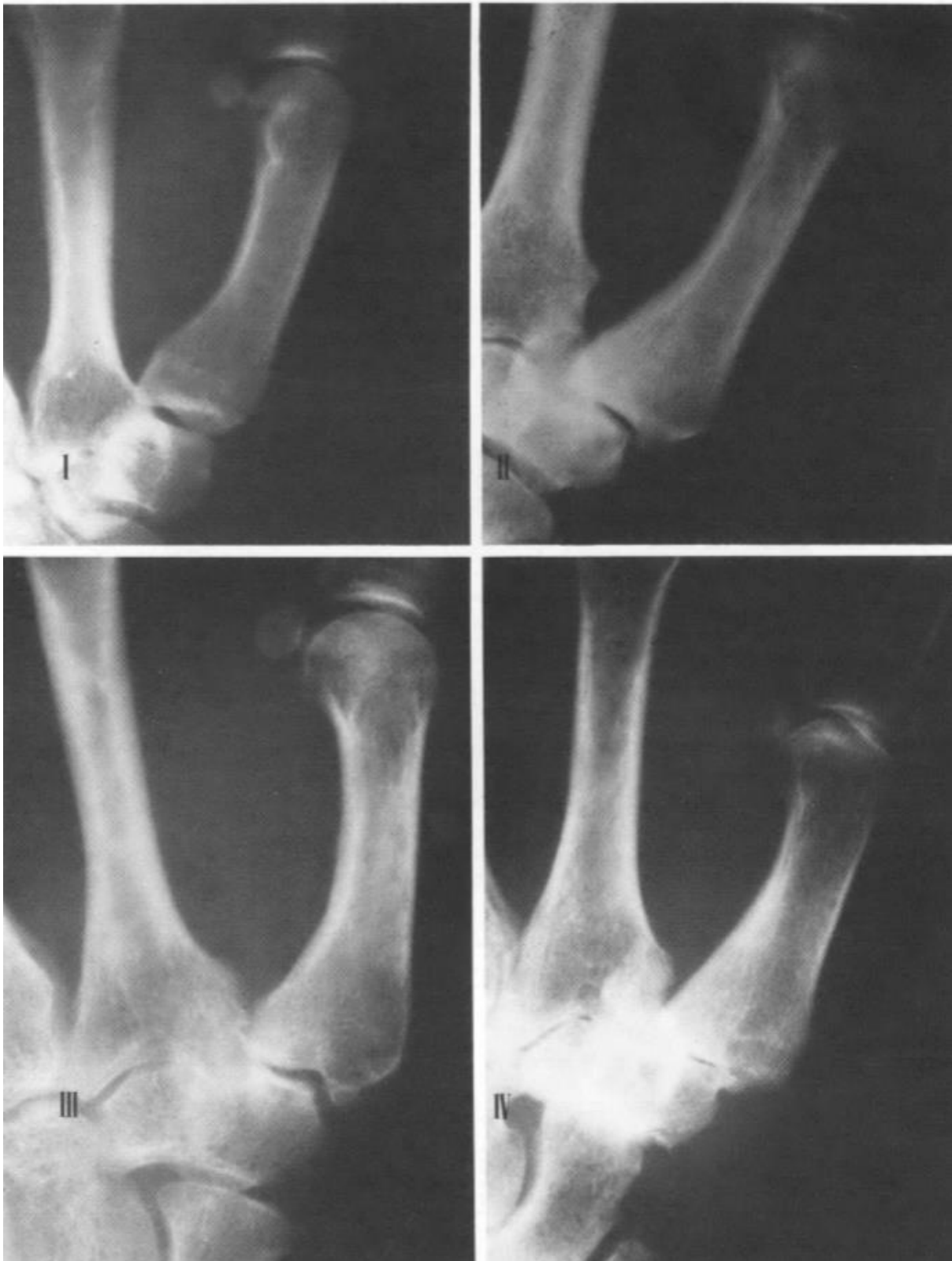flexion results in a 'zigzag' appearance to the thumb. Point tenderness may be elicited directly over the TM joint with a positive grind test (pain and joint crepitus on axial grinding of the joint). As a result of pain and narrowed hand width due to contracture, patients have weakened pinch and grip strength. Patients with base of thumb OA may also have concomitant carpal tunnel syndrome and de Quervain's tenosynovitis (15).

### Diagnosis and Staging

Accurate diagnosis and staging is important; it is a prerequisite for subsequent management, including patient selection and suitability for surgical management. Base of thumb OA can be diagnosed on history and examination alone. However, further investigation with plain radiographs will help to confirm diagnosis and stage the severity of disease.

The most widely used classification system for staging base of thumb OA was first proposed by Eaton and Littler in 1973. This was then later modified to include the presence of pan trapezial or scaphotrapezial (ST) arthritis (12, 16, 17). The Eaton Littler classification describes four stages of disease based on radiographic appearance on a true lateral x-ray with MCP sesamoid bones superimposed (12).

**Stage 1:** The radiographic appearances are normal or show slight widening of the joint space due to mild joint effusion or ligament laxity. **Stage 2:** The TM joint space is preserved but narrowed in comparison to normal or stage I disease. Minimal sclerosis of subchondral bone may be present. Osteophytes or loose bodies less than 2mm in diameter may occupy the joint space. **Stage 3:** The joint space is markedly narrowed or completely obliterated with significant subchondral sclerosis and cysts. Joint debris in the form of osteophytes or loose bodies are larger than 2mm in diameter. The arthritic changes are limited to the TM joint with preservation of ST joint. **Stage 4:** TM joint appearances are identical to stage three disease, with additional involvement of the ST joint showing subchondral sclerosis and cysts.



**Figure 2. Radiographs showing 4 stages of diseased based on the Eaton-Littler classification (Eaton, J Am Acad Orthop Surg, 2008)**

Although widely used and recognised, the limitations of the Eaton Litter system include only moderate inter-rater and intra-rater reliability (18). There may be also be underestimation of the

severity of disease when correlated with findings intra-operatively and radiographic staging is again not predictive of clinical symptoms (12, 16).

Other classification systems have been proposed by several authors. Badia et al proposed an arthroscopic classification system based on findings during arthroscopy. The system highlights the discrepancy between radiographic and arthroscopic findings. E.g. radiographic stage 1 disease may display focal loss of cartilage corresponding to an arthroscopic stage two disease. Staging can be done with greater accuracy under direct visualization with the added advantage of potential for treatment during the same procedure (19).

### Conservative management

Early stages of base of thumb OA is managed conservatively, and even in later stages of disease, a trial of conservative therapy is indicated. The aims of conservative therapies are to reduce pain, improve joint stability and restore function. Widely used conservative methods are hand-based splints, physiotherapy, non-steroidal anti-inflammatory (NSAIDS) and intra-articular corticosteroid and hyaluronate injections. (20).

Hand therapy techniques include passively mobilising the TM joint, neurodynamic manoeuvres to mobilise the superficial branch of the radial nerve and exercise protocols. These interventions have been shown to reduce pain in the short-term however did not show any benefit of increasing range of movement and grip or pinch strength (21-23).

Studies investigating the effect of splints have shown some benefits with regard to pain reduction in patients with base of thumb OA. Patients wearing a custom-made neoprene splint five times a week at night had improved pain and disability at 12 months follow up (24). Both prefabricated and custom-made splints have therapeutic effects to reduce pain. One study showed that although patients preferred a pre-fabricated splint, the custom-made splint provided greater reduction in pain (25, 26). Similarly, the use of short and long orthosis both provided pain relief, with patients preferring a short hand based-splint (27).

The use of intra articular steroid injection has been shown to reduce pain and inflammation caused by OA. The study by Bahadir et al showed patients with 1<sup>st</sup> carpometacarpal (CMC) OA undergoing steroid injection had pain reduction for up to 12 months (28). Similar results are reported with the use of hyaluronate (29).

The studies assessing effect of conservative therapy included symptomatic patients with various stages of OA. This supports the belief that a trial of conservative therapy is indicated and potentially beneficial regardless of the presenting stage of OA. Therefore, only patients with pain refractory to conservative treatment should be considered for surgical interventions.

## Surgical management

Patients with intolerable pain and functional impairments refractory to conservative treatment are candidates for surgical intervention (30). Main treatment aims are to alleviate pain and restore function of the thumb. Although many surgical techniques have been explored to meet these treatment aims, controversy still exist as to which procedure is superior. Currently in Australia and worldwide, the preferred surgical treatment firstly involves performing a total trapeziectomy (31).

Total trapeziectomy is an elective open procedure, which is usually performed under a general anaesthetic and involves piecemeal excision of the entire arthritic trapezium bone. Post trapeziectomy, a question then arises as to what is best done with the newly formed trapezial space. An unconventional 'L'appel du vide' or 'calling of the void'! The questions revolve around whether the space is best left alone, or if attempts should be made to preserve it either by suspension of the thumb or interposition of some material. If the latter options are pursued, further questions arise with regard to the best method and material used for interposition or thumb suspension. Many biological (cartilage, acellular dermis and tendon) and synthetic materials in the form of trapezial implants have

been trialled. The ensuing paragraphs explore the current literature surrounding the surgical management of base of thumb osteoarthritis.

### *Simple trapeziectomy*

Simple trapeziectomy for base of thumb OA was first described by Gervis et al at the British Orthopaedic association annual meeting in 1948, the case series was then later published in 1949 (32). Gervis suggested removal of the trapezium en bloc and zero post-operative immobilisation: "Active movements are started at once" (32). Since this description some alterations to technique and post-operative care have been incorporated, such as K-wire fixation to hold the joint distracted and prolonged 3-6-week immobilisation in plaster (33).

### *Advantages*

Simple trapeziectomy is well documented to provide excellent pain relief and preserve range of motion. The study by Gangopadhyay et al showed that 18 years post trapeziectomy good pain relief was achieved in patients. Mean pain levels improved from having pain at rest with severe restrictions to having no pain at all. Similar results were found by Salem et al comparing simple trapeziectomy and trapeziectomy+ LRTI. Both groups demonstrated improvement in pain compared to pre-operative pain levels. 80% of patients post trapeziectomy had no pain or only a mild ache. Furthermore, no significant differences in pain levels, functional outcome (measured by the DASH questionnaire), and pinch and key strength between the two groups were found. Another advantage of trapeziectomy is low complication rates (34). The literature therefore suggests that a simple trapeziectomy is capable of providing good pain relief and functional outcome with low complication rates in the majority of cases.

### *Disadvantages*

Shortening of the thumb, continued weakness in pinch and grip strength are the main disadvantages of simple trapeziectomy. In the series described by Gervis et al, all but two had satisfactory results, with good pain relief and range of movement restored. The main complaints of the patients were

continued weakness of the thumb (32). It has been shown however that the continued weakness is often subjective and that overall hand function is improved secondary to pain relief. Furthermore, shorting of the thumb was not correlated with increased weakness (35) although is important for cosmesis.

Another disadvantage concerning simple trapeziectomy is late onset failure due to subsidence of the first metacarpal and new arthritic changes in the scapho-metacarpal joint. The study by Salem et al investigated the trapezoidal space height and the development of OA after simple trapeziectomy. No significant difference was found in trapezoidal space height between the trapeziectomy and trapeziectomy LRTI group. The measured heights were 4.4mm vs 3.4mm respectively on stressed views. Although joint space did not significantly deteriorate over time in both groups, patients with simple trapeziectomy had greater degenerative changes on x-ray at 6 years. This was not however clinically significant and did not have an effect on functional outcome measured by the DASH score and pinch strength (36).

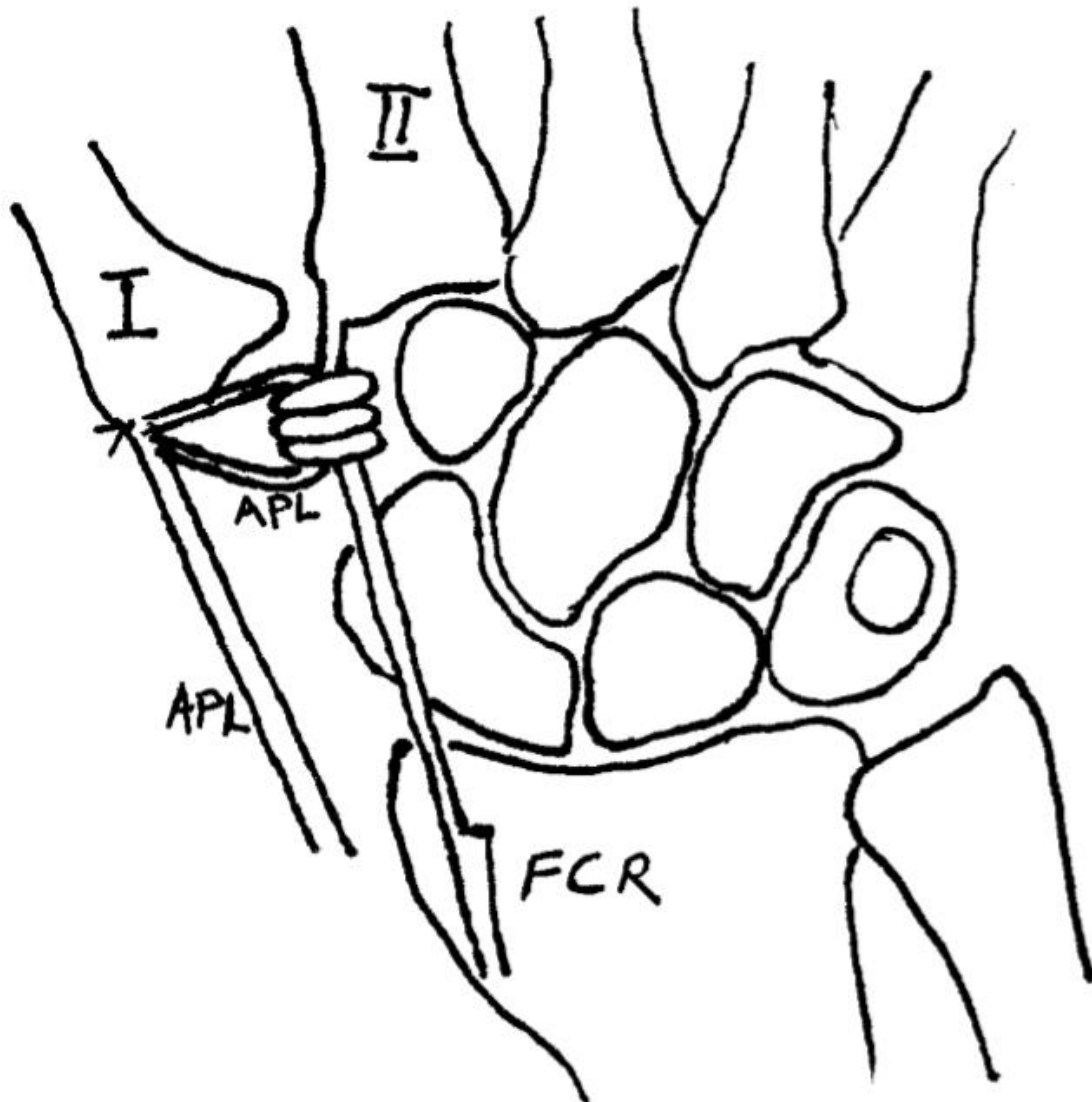
Other reported long-term complications include residual pain at the base of the thumb, sensory disturbance related to superficial branch of radial nerve, and flexor carpi radialis (FCR) rupture (37).

#### *Trapeziectomy with Ligament reconstruction +/- tendon interposition*

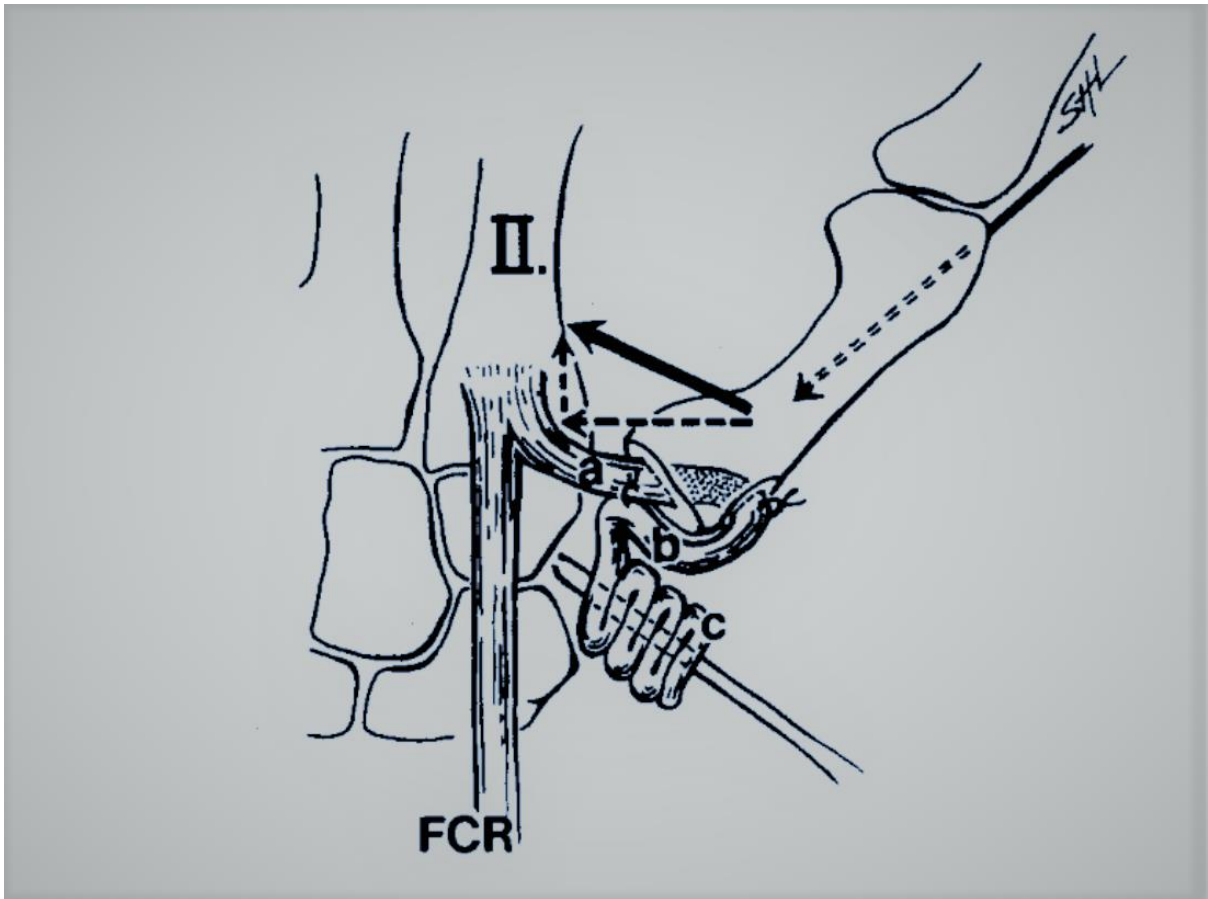
The terms ligament reconstruction and tendon interposition (LRTI) refer to a number of surgical techniques which use a tendon to suspend the thumb or interpose between the metacarpal and scaphoid to fill the trapezoidal space.

Ligament reconstruction techniques using the FCR tendon and abductor pollicis longus (APL) tendon have been described. The Weilby tendon interposition arthroplasty uses a partial distally based strip of FCR and a slip of APL tendon. The FCR tendon is wound around the remaining FCR portion and APL tendon to fill the trapezoidal space. A large slip of APL is doubled over and re-sutured to its origin to ensure good thumb abduction (38). The technique described by Burton and Pellegrini also uses

a portion of FCR. This technique places a tunnel which extends from the ulnar metacarpal base to the radial metacarpal cortex. The distally attached FCR tendon is passed through the metacarpal base and sutured to the periosteum in the radial cortex. An anchovy is conjured up from the remaining tendon by folding and suturing it on to itself. The tendon anchovy is placed in the trapezial space as an interposition spacer (39).



**Figure 3. Weilby interposition arthroplasty using partial FCR. The strip of FCR is wound around remaining portion and APL to fill the trapezial space (Nylen, J Hand Surg [Br], 1987)**



**Figure 4. Burton Pellegrini technique. A portion of FCR is passed through the metacarpal base, and a tendon anchovy produced from the remaining tendon to act as a spacer (Burton, J Hand Surg, 1986)**

Similar techniques using a slip of APL have been described by Siggfusen et al (40). A slip of APL is divided proximally and brought into the trapezial space. The tendon is then wound around FCR and the remaining APL in a figure eight. The remaining tendon is sutured on to itself and placed in the trapezial space as an anchovy (41).

Other soft tissue arthroplasty techniques include the use of Palmaris Longus (PL) tendon for interposition (42), and extensor carpi radialis longus (ECRL) tendon for ligament reconstruction (43).



### Advantages

Although many studies report similar outcomes between simple trapeziectomy and trapeziectomy with LRTI, the benefit of adding a soft tissue procedure may only be apparent with long term follow up. Currently in the trapeziectomy + LRTI literature, many of the studies have relatively short follow up (44, 45). The study by Bidwai et al showed good results were maintained in the medium to long term post trapeziectomy + LRTI using Weilby procedure. Patients had grip, key and pinch strength comparable to the non-operated side at 5 years post op. Pain was rated 1.7 using a visual analogue scale (VAS) out of 10, and the mean disability of shoulder, arm and hand (DASH) score was 25. These results correspond to low pain levels and good functional outcomes in the medium to long term.

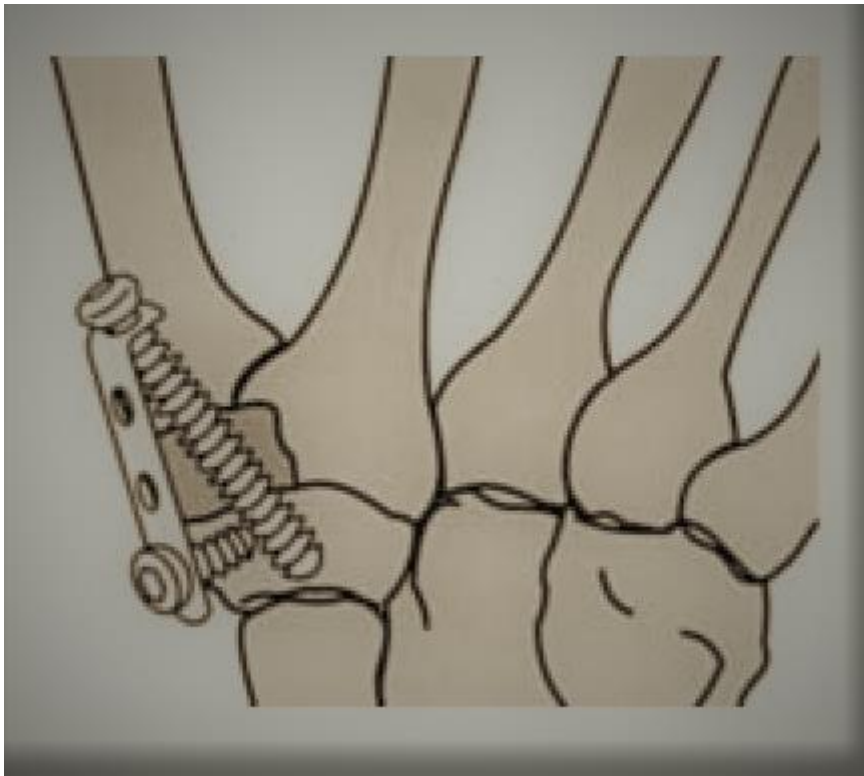
### Disadvantages

The main disadvantage which has been reported with the use of LRTI is a higher complication rate when compared to trapeziectomy alone (45). The systematic review by Wajon et al in 2009 initially concluded that the LRTI group had higher rates of scar tenderness, tendon adhesions or tendon rupture, sensory changes related to superficial radial nerve and development of complex regional pain syndrome. However, a further update of the systematic review in 2015 found that the difference in complication rates between the two groups were no longer statistically significant (46).

The addition of a soft tissue arthroplasty to trapeziectomy undoubtedly increases operation and tourniquet time. In some instances, it also produces additional scars (35).

### Arthrodesis

Arthrodesis of the trapeziometacarpal joint is another procedure at the disposal of the hand surgeon for treatment of base of thumb OA. Arthrodesis has been advocated to be used in younger patients with higher demand hands (47). Arthrodesis of the joint can be achieved by removing cartilage and sclerotic subchondral bone and interposing a cortico-cancellous bone graft harvested from the iliac crest. Stable fixation is achieved using a mini plate and cortical screws across the previous TM joint (48).



**Figure 5. Schematic of arthrodesis procedure showing bone graft, plate and screw fixation (Schroder, Arch Orthop Trauma Surg, 2002)**

#### Advantages

One of the reported advantages of arthrodesis is increased strength when compared to trapeziectomy +/- LRTI. The study by Hartigan et al found patients undergoing arthrodesis had significantly better lateral pinch ( $p < 0.001$ ) when compared to the trapeziectomy +/- LRTI group.

#### Disadvantages

The main disadvantage of arthrodesis is a high non-union rate and restriction in range of movement. The literature reports rates of non-union between 8% and 21% (45). It is important to note that patients with non-union can still have good pain relief and high satisfaction rates (49). Compared to trapeziectomy +/- LRTI, patients undergoing arthrodesis had less thumb opposition and ability to flatten their hand (49).

### *Comparison of surgical techniques*

Several studies have been performed to delineate which surgical procedure is superior in the treatment of base of thumb OA. The Cochrane systematic review, "Surgery for the thumb (trapeziometacarpal joint) osteoarthritis, first published by Wajon et al in 2005 and updated in 2009 and 2015, identified eleven RCTs and compared the outcomes of seven surgical procedures: Trapeziectomy, trapeziectomy with LRTI, trapeziectomy with LR, trapeziectomy with interposition arthroplasty, Artelon joint resurfacing, arthrodesis and Swanson joint replacement. The review was unable to demonstrate any benefit of one procedure over another with regards to pain and function, nor conclude if the different procedures produced equivalent outcomes. Furthermore, the trials included did not report on complication, revision and re-operation rates (46). Other comparative studies draw similar conclusions that minimal difference exists between procedures, however more complex procedures have greater complications (33, 45).

The systematic review by Li et al comparing simple trapeziectomy to trapeziectomy with LRTI found no statistically significant difference between the two techniques with regard to grip strength, pinch strength, DASH score, complication rates and pain measured by visual analogue scales (50).

A further systematic review comparing 8 different surgical techniques by Vermeulen et al also concluded no surgical procedure has proven superior however trapeziectomy with LRTI, and arthrodesis has higher complication rates (45).

The study by Gangopadhyay et al showed that 18 years post trapeziectomy good pain relief was achieved in 78% of patients undergoing Trapeziectomy, Trapeziectomy + LRTI and Trapeziectomy + TI. No significant differences were noted between the groups regards to pain relief, key and pinch strength and ability to perform activities such a writing, turning a key, and opening a jar (51). Similar results were found by Salem et al. No significant differences in pain levels, functional outcome (measured by the DASH questionnaire), and pinch and key strength were found between the trapeziectomy and trapeziectomy +LRTI groups (34).

# Systematic review: Failure rates of non-implant arthroplasty surgery for base of thumb arthritis

## Introduction

Surgical decision making regarding the best treatment option for base of thumb OA is a complex process. Many procedures are available (i.e trapeziectomy, trapeziectomy +/-LRTI and arthrodesis), and the literature remains largely inconclusive with regard to superiority of one technique over another. Superiority in terms of outcome measures such as pain relief, grip and pinch strength and functional outcome scores are similar. All techniques are capable of relieving pain and restoring function in a majority of patients. Some suggestion has been made that trapeziectomy +/- LRTI and joint fusion carry higher complication rates, however this again is not definitive. To base superiority of one technique over another on complication rates alone is ambiguous. Complications encompass a broad range of phenomena varying in severity and spanning over indeterminate amounts of time. Although complication grading systems have been created to categorise severity, their applicability in hand surgery for surgical decision making has minimal value due to the nature of the complications encountered. Procedure failure rates on the other hand are less ambiguous and serve as a more definitive comparator to judge one technique against another. A systematic review of the literature on failure rates of trapeziectomy, trapeziectomy +/- LRTI and arthrodesis was done to further delineate the superiority of one technique over another and aide surgical decision making.

## Methods

### **Search strategy**

A Medline search was carried out using the key word 'thumb' with limitations of 'review article' and '2007-2018' to identify systematic reviews reporting on surgical management of base of thumb arthritis in the past 10 years. The search results were screened by title to identify relevant systematic reviews. The articles included in the identified systematic reviews were then included for full-text review.

Inclusion criteria were: 1. Articles reporting on non-implant arthroplasty techniques for treatment of base of thumb osteoarthritis and 2. Articles which stated the number of arthroplasties and mean duration of follow up.

### **Data collection**

Data was collected using excel spreadsheet. Data points included: Level of evidence, sample size, mean age at surgery, mean follow up duration in months, procedure type, procedure complication, number with complication, salvage procedure and number with salvage procedure.

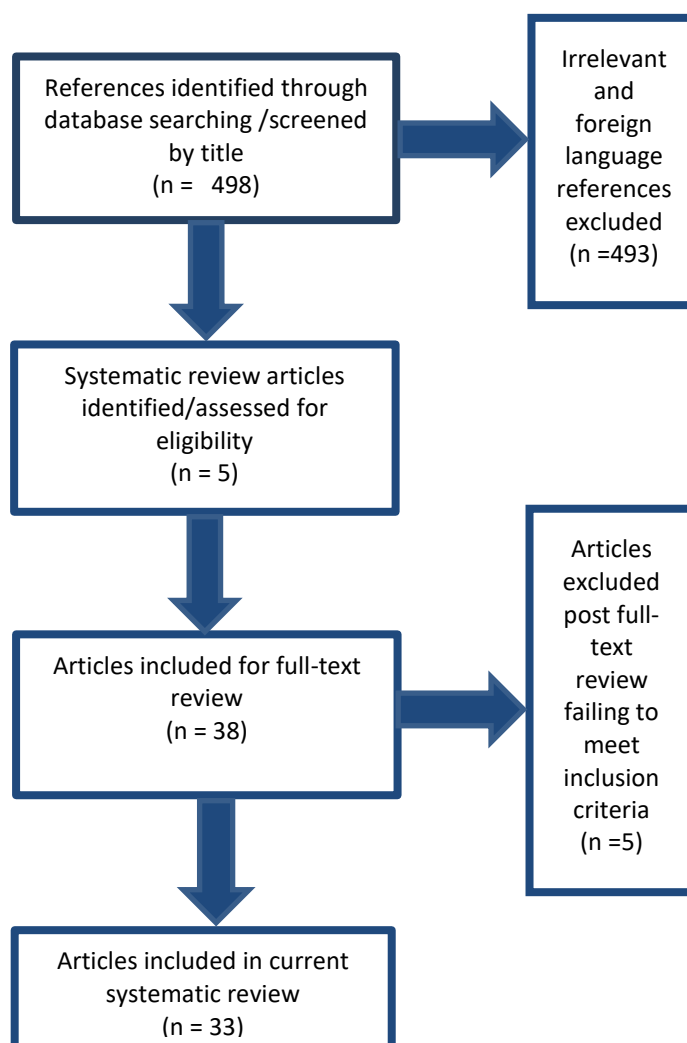
The identified surgical procedures were divided into three groups: 1. Trapeziectomy, 2. Trapeziectomy +/- LRTI and 3. joint fusion (arthrodesis). Data from techniques using FCR tendon, APL tendon, PL and ECRL tendon were pooled together to form the Trapeziectomy +/- LRTI group.

### **Data Synthesis**

Failure rates were calculated based on the method employed by the Australian Orthopaedic Association National Joint Replacement Registry (AOANJRR) to calculate failure rates of joint replacements. Firstly, procedure-years were derived by multiplying the number of study participants by the mean length of follow up of the study. A failure rate for each procedure was then calculated as the number revised per 10 procedure-years.

## Results

A total of 33 articles were included in the current review (Figure 6).



**Figure 6. Flowchart showing the selection of studies for the systematic review**

The level of evidence (according to the Oxford Centre for Evidence-Based Medicine [OCEBM]) of the included articles were high (level III or higher) as the systematic reviews which they originally belonged to had stringent inclusion criteria (Table 1). Full list of studies included and study characteristics are provided in appendix 1. The mean age of the patients included in the review was 58.8 years. A total of 1515 arthroplasties were performed in the articles included. The mean of the mean length of follow up of the studies was 32 months with a range of 6-69 months.

No. of articles	Level I 16	Level II 3	Level III 19	Level IV 0	Total 38
-----------------	---------------	---------------	-----------------	---------------	-------------

**Table 1: Evidence level frequency of included articles, defined by OCEBM, 2011.**

The 10-year failure rates for the surgical procedures trapeziectomy, trapeziectomy +/- LRTI and arthrodesis were 4.9%, 2.4% and 5.2% respectively. The overall failure rate of all non-implant arthroplasty was 3.4% in 10 years.

Non-Implant surgery	Procedure-years	Number failed	% Failure rate per 10 years
<b>Trapeziectomy</b>	1222	6	4.9
<b>Trapeziectomy +/- LRTI (APL, FCR, PL, ECRL)</b>	3747	9	2.4
<b>Arthrodesis</b>	1153	6	5.2
<b>Total</b>	6122	21	3.4

**Table 2. Non-implant arthroplasty 10-year failure rates.**

### Discussion

The systematic review was performed to compare failure rates of different surgical techniques used to treat base of thumb arthritis in order to guide surgical decision making as the current literature remains inconclusive with regard to superiority of one procedure over another. Considering the surgical procedures are reported to have similar outcomes with regard to pain relief, pinch and grip strength, DASH scores and complication rates, it then becomes plausible to base decisions on which procedure has the lowest failure rates. From the review it is apparent that the trapeziectomy +/- LRTI group has the lowest failure rates. The failure rates of simple trapeziectomy and arthrodesis

are more than double the failure rate of trapeziectomy +/- LRTI. Lower failure rates among this group suggests that the addition of an interposition material or suspension of the thumb is desirable for long term success.

The main reason for revision post simple trapeziectomy was persisting pain secondary to metacarpal subsidence, metacarpo-trapezoid and metacarpo-scaphoid abutment (35). The main reason for failure of joint fusion was persisting pain and non-union (52, 53). The main reason for revision in the trapeziectomy +/- LRTI group was again persisting pain (34, 35, 51).

The main limitation of the review was the search strategy. Potentially relevant level IV evidence articles could have been included as long as they were reporting on non-implant arthroplasty for base of thumb OA and stated the number of arthroplasties and duration of follow up. The method used to calculate failure rates is a linear model and does not give information with regard to early vs late failure for example.

## Conclusion

The current review favours the use of trapeziectomy together with a soft-tissue arthroplasty technique for treatment of base of thumb OA based on low failure rates compared to simple trapeziectomy and joint fusion.

## Trapezoidal Implants

The literature so far suggests that simple trapeziectomy +/- LRTI and joint fusion are successful at treating pain and improving function in a majority of patients. However, each of the techniques discussed carry disadvantages. To address these disadvantages trapezoidal implants have been trialled with varying degrees of success and popularity. The actual and theoretical advantages of using an implant to treat base of thumb OA include immediate thumb stability, restoring or enhancing joint biomechanics to provide a strong grip and pinch, to preserve thumb length by preventing



metacarpal subsidence, deliver greater patient satisfaction and a faster road to recovery (54). These factors are secondary to provision of excellent pain relief. Implants of different designs composed of different material are currently available. The following paragraphs aim to provide an overview of the currently available implants. Due to the numerous different types of implants available subheadings have been created based on the classification system of trapezial implants proposed by Vitale et al (54). The implants are classified by basic design concept and not the material it is composed of. The three basic designs are 1. Interposition, 2. Total Joint replacement and 3. Hemiarthroplasty.

## Interposition

Many types of trapezial implants are used for interposition similar to that of tendon interposition. It is based on the concept of placing some material between the metacarpal and the trapezium (post partial trapezial resection or no trapezial resection) or scaphoid (post total trapeziectomy) to resurface the joint and preserve joint space.


The class of implants used for interposition can be further divided by the degree of trapezial resection done prior to interposition. Interposition of an implant can be done without any trapezial resection, post partial trapezial resection and post a total trapeziectomy.

## Implants post total trapeziectomy

### *Swanson trapezial implant*

The first trapezial implant to become available for use was the Swanson trapezial implant in 1965. Swanson drew from his experience of creating other implants for replacement of small joints in the hand to develop a silicone implant to be used as a spacer post total trapeziectomy. The implant is stabilised by a metacarpal stem, which is inserted intramedullary within the shaft of the metacarpal. The metacarpal stem maintains the correct alignment between implant and metacarpal. The original design contained a convex base, but was later changed to a concave base for better articulation with the convexity of the scaphoid (55). Since its initial implementation concerns over the use of the

Swanson trapezium has been expressed due to a high prevalence of silicone synovitis. The prevalence of silicone synovitis with the use of trapezium implants is reportedly higher than for other small joints in the hand (56) and failure rates of up to 25% have been reported with Swanson implants secondary to synovitis (57). The implants however are capable of providing good pain relief, restoring range of motion and preserving thumb length in a majority of patients. The study by Lehmann et al found equal outcomes in pain relief, range of movement, pinch and grip strength when compared to trapeziectomy (56). 16-year long-term follow up of patients with silicone arthroplasty showed that only 84% (52 out of 62 patients) had satisfactory outcomes in terms of good to excellent pain relief, and improved key, pinch and grip strength (58). High complication rates related to silicone synovitis, implant fracture and dislocation are repeatedly encountered (59). The Dow Corning silastic trapezium implant appears to be identical to the Swanson design (60).

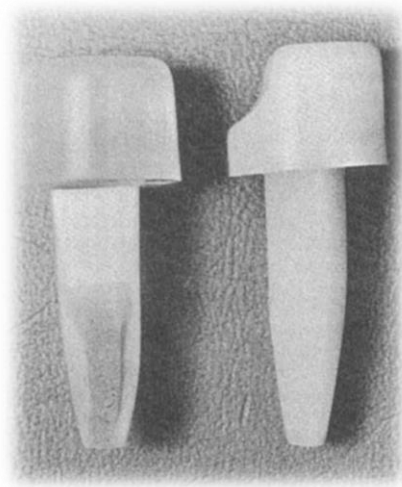


**Figure 7. Swanson Trapezium (left) (Swanson, JBJS Am, 1972), Dow Corning Silastic Trapezium (Right) (Hook, J Hand Surg Br, 1986)**

### *Tecoflex Os Trapezium*

Tecoflex is a polyether elastomer (polyurethane) and has similar tensile properties to silicone (61). Similar in design to the Swanson trapezium, the Tecoflex implant too contains a metacarpal stem and base for complete trapezium replacement. In addition, an ulnar notch in the base is an added design feature to improve articulation with the trapezoid for increased stability. Unlike the silicone

Swanson trapezium, the Tecoflex Os implants were biocompatible but painful dislocations were still encountered (61)



**Figure 8. The Tecoflex os trapezium (right) and Swanson trapezium (left) (Sollerman, Scand J Plast Reconstr Hand Surg, 1993)**

*Eaton trapezium implant, Niebauer implant and Tie-in implants*

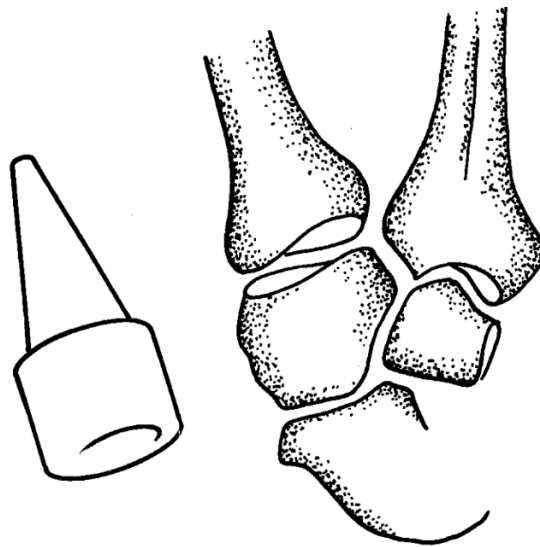
Similar in shape and design to the Swanson trapezium are the Eaton trapezium, Niebauer and Tie-in implants. The implants are again stabilised by a metacarpal shaft, but also contain an additional anchor mechanism to provide further stability.

The Eaton trapezium contains a tunnel at the base of the implant for passage of a slip of APL through the tunnel and into the adjacent trapezoid. Additional stability is assumed by the implant incorporated ligament reconstruction, however the case series reported a dislocation and subluxation rate of 10%. Pain free movement was achieved in all patients, and a pinch strength of 6kg and 8kg for women and men respectively (62).

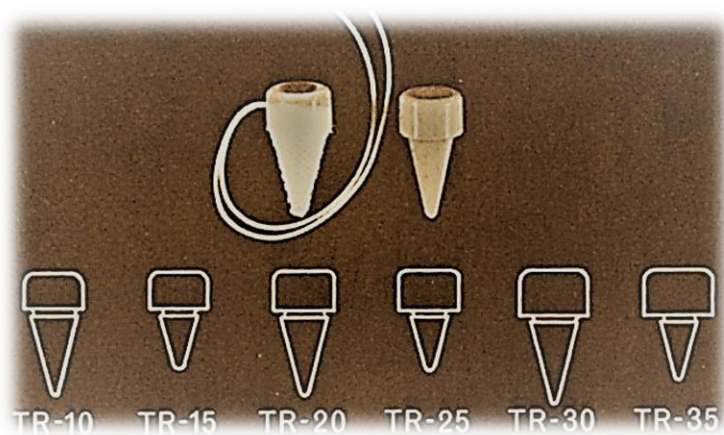
Results of the Niebauer implant was presented by Ferlic et al in 1977 and Poppen et al in 1978. Poppen et al called it instead the 'Tie-in' implant leading to some confusion, however it is apparent

the implant discussed in both case series is fact the same (63, 64). This implant contains two heavy Dacron ties to anchor the prosthesis into surrounding tendons. Ferlic et al in their case series of 11 patients describe range of motion and stability as "Satisfactory, but far from normal". No implant dislocations were encountered. However, dislocation and instability of the implant was encountered in other published case series (65). Post-operatively pain was completely resolved or only slight in 75% of patients. 25% still had moderate pain (66).

(a)



(b)



**Figure 9. Niebauer Implant. Schematic demonstrating the prosthesis morphology and alignment in relation to normal anatomy (a) (Rajan, Hand, 1982). Implant containing heavy Dacron ties to anchor the implant to surrounding tendon (b) (Poppen, J Hand Surg Am, 1978)**

The implant used by Avisar et al, was again confusingly referred to as “Tie-in” implant. However, this implant is of a different design and contains a groove which allows for an FCR tendon sling to be wrapped around the implant head to increase stability. Mean pain levels measured by visual analogue scale (VAS) improved from 7.4 pre-operatively to 1.2 post operatively. Good range of movement was achieved with 85° of thumb abduction. Patients had a post-operative DASH score of 25 correlating to good functional outcome (67).




**Figure 10. Tie-in trapezial Implant containing a rim for FCR tendon sling to be wrapped around (Avisar, J Hand Surg Am)**

### *Helal prosthesis*

The Helal prosthesis was first described in 1983 by its’ designer. It consists of a central silicone elastomer ball used as a trapezial spacer and, not one, but two stems for stability. One for the metacarpal and another for the scaphoid respectively. The implant is symmetrical and was designed with the view to be used in other small joint replacements in the hand (68). The stems are reinforced with polyester fibre mesh. Although the double and reinforced stems appear to be measures taken to improve stability and prevent implant fracture, in the case series presented by Helal et al reports two implant subluxation and two implant fractures. Majority of patients though attained good pain relief and retained 80% of the strength in the contra-lateral hand (69). The series of 23 patients presented by O’Leary et al, showed patients had 37° of thumb extension and 40° of abduction at 59-

month post op. Grip and pinch strength was approximately 20% less than for age matched individuals (70)



**Figure 11. The Helal prosthesis. This prosthesis contains two metacarpal stems for increased stability (O’Leary, J Hand Surg Br, 2002)**

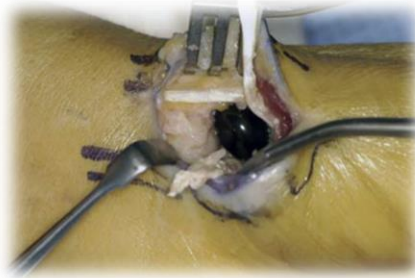### *Pi<sup>2</sup> Trapezial Implant*

Trapezial implants composed of the relatively new material Pyrocarbon, have been developed to address the concerns with silicone synovitis affecting many of the silicone trapezial implants. Pyrocarbon has a reputation of having perfect biocompatibility and an elastic modulus similar to cortical bone. It contains a core of graphite with a fine outer layer of pure carbon. The pure carbon outer layer is created from carbon gas at extremely high temperatures ranging from 1200-1500<sup>o</sup> (71).

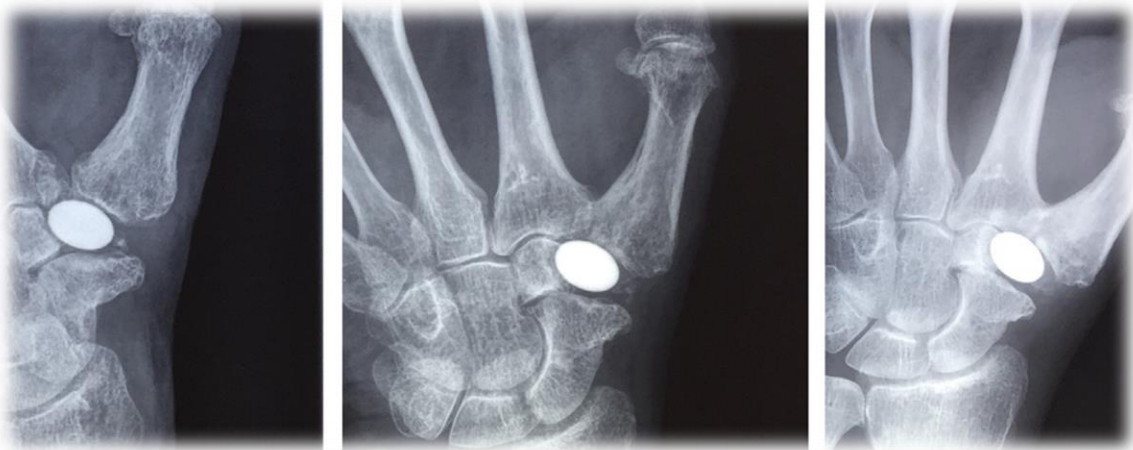The Pyrocarbon interposition implant, or more affectionately known as the Pi<sup>2</sup> implant, is an oval shaped pyrocarbon spacer inserted freely into the trapezial space. This implant contains no stabilising features and relies on capsular and ligament support for stability (72). A case series of 43 patients with a 5 year follow up period showed two dislocations, the same series at 10 year follow up did not show any further dislocations (72). The study showed that 97% of the patients were satisfied and showed comparable range of movement (ROM) and strength to the non-operated hand (71). A prospective cohort study comparing the Pi<sup>2</sup> implant to simple trapeziectomy showed no statistically significant difference in pain VAS, DASH scores and strength measurements between the two groups at six and 12 months follow up. Seven of the 24 implants in this series required revision due to dislocation (73). Similarly high complications of dislocation were encountered in the

series by Maru et al without any objective or subjective benefit when compared to simple trapeziectomy (74). The series of 63 patients by Szalay et al showed 83.2% of patients had very good or good outcome based on Buck-Gramcho scale. However, dislocations and revisions were again encountered in this series and the case series by van Aaken et al (75, 76).

(a)



(b)



**Figure 12. The Pi<sup>2</sup> implant in situ intra operatively (a). X-rays of the same patient with Pi<sup>2</sup> implant at 10 years, 5 years and immediately post op (b) (Agout, Hand Surg Rehabil, 2016)**

#### *Amorphous interposition materials*

A range of synthetic materials have been trialled for basic interposition post total trapeziectomy. These materials are in generic forms such as sheets, rolls, gels or strips and lack any specific implant morphology. The rationale for such spacers is to avoid the increased complications reported with autologous tendon spacers (77). Such implants act solely as space fillers to preserve joint space



and resurface the joint. They would otherwise confer no increased stability to the joint, at least in theory.

### Polyethylene Mesh

Spaans et al report on the outcomes of a polyethylene terephthalate mesh spacer. The implant is non-resorbable and aims to reduce metacarpal subsidence. The spacer is meant to be encapsulated by fibrous tissue within three weeks and remain innate. The results however, reported by Spaans et al show that the material is capable of producing foreign body reactions requiring explantation of the mesh (77). No evidence is available regarding positive outcome measures such as pain relief, strength and functional outcomes with the polythene mesh.



**Figure 13. Polyethylene mesh spacer (Spaans, J Hand Surg Am, 2014)**

### Gelfoam spacer

Gelfoam has been used in surgery since at least the 1940's. It is a haemostatic agent applied to bleeding surfaces. It is an absorbable material composed of porcine skin and gelatine granules. Its haemostatic action is more physical as opposed to altering clotting pathways. It has been used as a trapezial spacer alone and in conjunction with a tendon spacer (78, 79). The case series presented by Nusem et al used Gelfoam as a spacer to prevent metacarpal subsidence. All patients in this series were satisfied with the operation and had good ROM at 5 year follow up. Strength was reduced, in key pinch, tip pinch and grip to 71%, 74% and 85% respectively compared to the



contralateral thumb (79). The trapezial space was maintained showing only minor (7%) shortening. No complications or revisions were encountered in this series.



**Figure 14. Gelfoam sponge (birthmarks.us, 14<sup>th</sup> Jan 2019)**

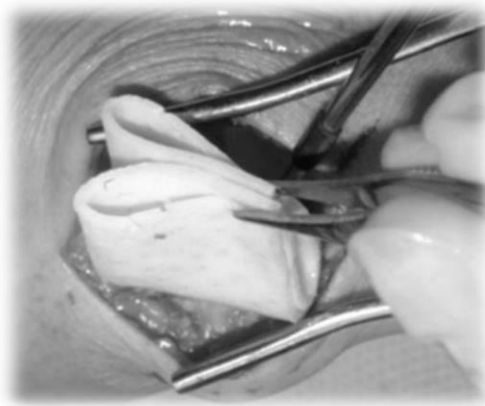### Permacol

Permacol is porcine acellular dermal matrix. Cells, DNA, RNA and other cellular material are removed to retain the 3D collagen matrix. Permacol has a wide range of applications in surgery from hernia repair as a biological mesh (80) , to breast reconstruction post mastectomy for implant coverage (81) and uncommonly as a trapezial spacer. Belcher et al randomised 26 hands with base of thumb OA to undergo simple trapeziectomy or trapeziectomy with Permacol. The study was prematurely terminated as 6 of the 13-thumbs with Permacol developed foreign body reactions. Furthermore, the control group was observed to have better grip, while the Permacol group reported more pain and less satisfaction with the surgery (82).

(a)



(b)



**Figure 15. (a) Permacol implant (fanavari.com, 14<sup>th</sup> Jan 2019), (b) Permacol implantation (Belcher, J Hand Surg Br, 2001)**

### Gore-Tex

Gore-Tex, also known as expanded polytetrafluoroethylene (e-PTFE) has a multitude of uses in a range of industries including textiles and medicine. Gore-Tex implants have a long and well documented history of use in many aspects of surgery, particularly vascular surgery. The use of Gore-Tex in hand surgery as a trapezial spacer has shown less favourable outcomes. Both series presented by Muermans et al and Greenberg et al reported a high incidence of synovitis and secondary osteolysis and recommend abandoning the use of Gore-Tex implant for this purpose (43, 83).

### Other materials

Other implanted spacers include Marlex, and Graftjacket Maxstrip. Marlex is another hydrocarbon polymer (polypropylene) and has several surgical uses. Its use has also been associated with inflammatory reactions (84, 85), however no synovitis was seen in the case series presented by Muermans et al (43). Graft-jacket is human cadaveric acellular dermal matrix. It is most widely used in orthopaedic surgery (86). Good outcomes were reported by Kokkalis et al in a series of 100 thumbs treated with trapeziectomy and Graftjacket spacer at minimum one year follow up. Pain levels measured by VAS reduced from 6.2 preoperatively to 0.7 post operatively. Compared to pre-operative levels, a 16% increase in pinch strength and 19% increase in grip strength were measured post operatively. However, a 31% loss of trapezoidal space height was noted. No cases of synovitis or revision were encountered (87).

### Implants post partial trapezoidal resection

Numerous implants are designed for interposition post partial resection of the trapezium. Many are composed of pyrocarbon (Pyrocardan implant, Pyro Disk, and PyroSphere) or silicone (Silicone Ball, Kessler Implant, Ashworth Implant). Other materials include ceramic (Orthosphere) and polyurethane urea (Artelon spacer).

### *Pyrocardan implant*

The Pyrocardan implant is a rectangular shaped implant with two “orthogonal tubular concavities” opposed to one another. It has a central thickness of approximately 1mm. Lauwers et al reported the outcomes of 28 patients after a mean follow up time of 25 months treated with Pyrocardan. Only 19 patients reported improvements in ADLs, were satisfied with the operation and would undergo the operation once more if required. 5 implants required revision secondary to dislocation, persisting pain and grinding related to the implant (88). The series presented by Odella et al showed patients treated with Pyrocardan had a 20% reduction in strength compared to the contralateral side. Post-operative pain recorded by VAS was 4 and DASH score was 22.4. 3 out of 25 patients did not have a satisfactory outcome and required revision due to worse pain than pre-operatively (89).



**Figure 16. The Pyrocardan implant with a bi-orthogonal design (Lauwers, Hand Surg Rehabil, 2016)**

### *PyroDisk*

The PyroDisk is a bi-concave disk with a central hole. It somewhat resembles a liquorice lifesaver. The convex surface is designed to increase congruity as partial resection of the trapezium leaves a concave surface. The central hole allows passage of a tendon graft for stability and proper alignment of the implant. Barrera-Ochoa et al reported 5-year outcomes on patients treated with the PyroDisk. Good range of movement was achieved, and pain rated on VAS reduced 7.9 pre-operatively to 1.7 post operatively, post-operative DASH score was 20.2. 8 out of 19 patients had developed subluxation or dislocation of the implant, with two requiring revision (90) . Similar results were reported by Odella et al; post-operative DASH score of 19.2 and pain levels on VAS of 3.3. 20% reduction in strength was present compared to the contralateral hand. One implant required revision due to pain. Dislocation again was encountered.



**Figure 17. PyroDisk implant (integralife.eu, 16<sup>th</sup> January 2019)**


### *PyroSphere*

The PyroSphere has an uncanny resemblance to a classic Tahitian pearl, and rather alarmingly, was proposed as an ideal trapezoidal implant design.

“The pyrocarbon spherical implant does satisfy the criteria as an ideal implant for arthroplasty of the first CMC”.

~Omar Bengezi (91)

The sphere sits cradled by the concavities of the trapezium and metacarpal base providing coverage of two thirds of the implant to confer stability. The case series of 24 patients reported by Bengezi had good outcomes at a mean follow up of 18.5 months (range 4.3-38.9). The mean post-operative DASH score was 11.7. Pain levels on VAS was 1.13 post-operative. No dislocations or revisions were encountered! (91)



**Figure 18. PyroSphere implant (Bengezi, Plast Surg Oakv, 2014) and perfect Tahitian pearls (right) (premiumpearl.com, 16<sup>th</sup> January 2019)**

### *Silicone Ball*


Identical in design to the above implant is a silicone spherical implant. The silicone balls range in diameter from 8mm to 12mm. A case series of seven patients treated with the silicon ball implant showed complete pain relief, increased grip and strength from pre-operative levels and good ROM. 1 dislocation required a revision procedure (92).

### *Orthosphere*

On keeping with a theme of spherical implants is the Orthosphere. Unlike its pyrocarbon and silicone cousins, the Orthosphere carries a denser disposition and is composed of yttrium-stabilised zirconia (a ceramic). The results of the Orthosphere presented by Adams et al were less than encouraging although patients were reportedly satisfied with the operation. Subsidence of the implant and trapezial fracture were frequently encountered. Pinch strength was measured to be 91% of the contralateral hand and pain levels were reported as “less than before surgery” or “much less than before surgery” in 83% of the patients (93). Further discouraging outcomes were reported by Athwal et al. 5 of 7 patients in the series underwent revision at a mean follow up of 33 months (94).

### *Proplast stabilised stemless trapezium implant*

The above-named implant is composed of a high-performance silicone elastomer. The cylindrical design is stabilised by a coating of 1 mm thickness of Teflon fluorocarbon polymer and aluminium oxide known as Proplast. This substance is porous and encourages tissue ingrowth to improve stability. The results of the implant reported in 88 patients at a mean two years follow up showed 65% of patients were symptom free, and had improved strength and good ROM. Four Implants were revised due to dislocations and persisting pain (95).



**Figure 19. Proplast stabilised trapezium implants in different sizes (Kessler, J Hand Surg Am, 1984)**

### *Cartiva Implant*

The Cartiva implant is a hydrogel containing 40% polyvinyl alcohol (PVA) and 60% saline. It has an appearance not unlike a lemonade wine gum. The compressive modulus and coefficient of friction


of the implant is similar to cartilage. The implant is impacted into the joint space to resurface the base of the 1<sup>st</sup> metacarpal. Good outcomes with the use of the implant were reported by Taleb et al in a series of seven patients. Pain score on VAS and DASH score were improved post operatively from 8/10 to 2/10 for pain and 93 to 40 for DASH respectively. A lower DASH represents greater function. Grip strength was markedly improved at the last follow up from 11kg to 20kg. No inflammatory reactions or revisions were noted (96).



**Figure 20. The Cartiva implants in difference sizes (left) (Taleb, Chir Main, 2014). An assortment of wine gums Arrows point to lemonade flavoured ones (right) (ebay.com.au, 16<sup>th</sup> January 2019)**

#### *Ashworth and Kessler Implants*

Other implants which have performed poorly and since been abandoned include the Ashworth implant. This is a modified neurosurgical burr hole cover used for interposition post partial resection of the trapezium and metacarpal base. The case series using this implant encountered several implant fractures (97). The Kessler implant used in the case series presented by Engel et al, 19 out of 25 patients encountered subluxation within the two year follow up period (98).

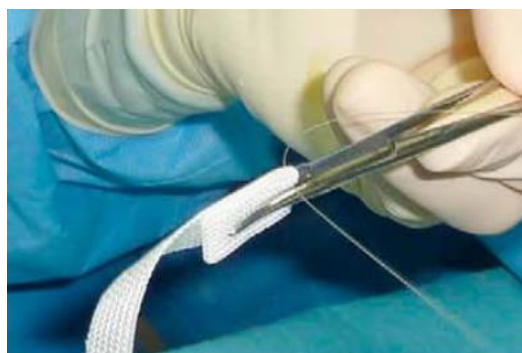

**Figure 21. Kessler implants in three different sizes (Kessler, JBJS Br, 1973)**

### *AREX implant*

Similar to the implants used for interposition post total trapeziectomy, some implants for interposition post partial trapeziectomy are in generic forms without any defined implant design.

The AREX L-polylactic acid implant (PLLA) is an absorbable implant and has been used for interposition with discouraging results. The implant was interposed arthroscopically in 25 patients. The pre-operative and post-operative scores for pain measured on VAS and function measured by DASH score were not significantly different; 6.61 and 6.03 for pain and 56.36 and 53.65 for DASH score respectively. Grip strength was reduced post-operatively from 15.34kg to 12.8kg. 11 patients had a poor outcome requiring revision to trapeziectomy (99). Semere et al also report on the AREX implant, 9 out of 68 patients encountered foreign body reaction requiring revision prior to 3 years follow-up (100). The series presented by Diaconu et al suggest good outcomes post PLLA implant for early stage of OA. In the series of 25 patients with a mean follow up of 18.5 months; post-operatively pain improved from 3.5 to 0.68, grip improved from 16.64kg to 24.76kg, lateral pinch from 3.64 to 6.44kg. Inflammatory foreign body reactions were again noted in 9 patients which resolved by three weeks (101).



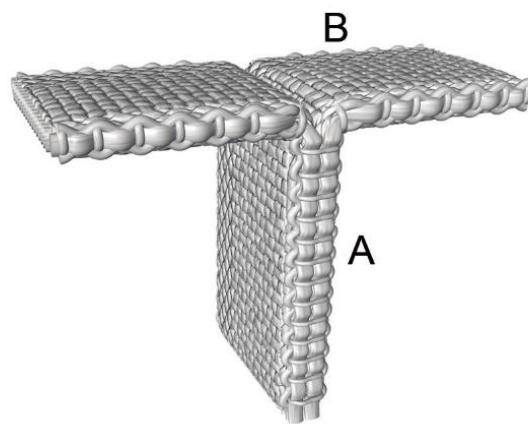
**Figure 22. The AREX L-polylactic acid implant (Diaconu, Chir Main, 2011)**

### *Artelon spacer*

The Artelon spacer was introduced as an alternative surgical option for base of thumb OA. The spacer is a T-shaped design to be used as an interposition material post partial resection of the



trapezium. It is composed of biocompatible polyurethaneurea and degrades over time (102). A pilot study published by Nilsson et al found equal pain relief in the Artelon and trapeziectomy group. In addition, the Artelon group demonstrated greater pinch strengths (103). A larger randomised control trial (RCT) was done following the pilot study which showed that pain relief was in fact better achieved in the simple trapeziectomy group. Furthermore, several authors have reported foreign body giant cell reactions to the spacer material, wound breakdown and implant extrusion (41, 104)



**Figure 23. The Artelon CMC spacer. Vertical spacer (A) is interposed between the trapezium and metacarpal. The implant is stabilised by anchoring horizontal wings (B) to cancellous bone on each side of the joint (researchgate.net, 16<sup>th</sup> January 2019)**

#### *Implants without any trapezium resection*

Two implants have been designed for interposition without requirement for trapezium resection; the Articulinx intercarpometacarpal (ICMC) cushion (105) and the Silicone rubber sponge (106). The Articulinx ICMC cushion is 'C' shaped and has a modified central area designed for weight bearing surface. The ring structure is composed of nickel titanium alloy and contains an outer covering of polycarbonate urethane. The spacer is implanted through a 1cm arthrotomy. It is delivered under fluoroscopic guidance attached to a tapered needle and secured with primary and auxiliary suture tethers. The case series by van der Veen et al reports on the outcomes of eight patients with the Articulinx cushion at 24 months follow up. VAS pain scores decreased from 6.3 pre-operatively to 2.2 post-operatively, quickDASH score improved from 47 to 31, and pinch and grip strength improved compared to baseline. Two out of the eight implants were removed at six and nine months

respectively due to displacement (105). Dickson et al described the outcomes of 12 patients (4 bilateral cases) treated with the silicone sponge with a 1 to 3.2 year follow up. Although no objective measures are reported the authors state complete pain relief and good range of movement in 15 of the 16 patients. One patient required removal of the implant at six weeks due to persistent crepitus and pain.



**Figure 24. The Articulinx ICMC cushion (van der Veen, J Wrist Surg, 2013)**

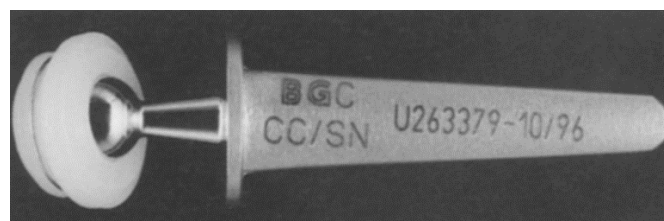### Total joint replacements

Many types of total joint replacements have been created, it is the most diverse group of trapezial implants. Key elements which define a total joint replacement are separate trapezial and metacarpal components. These components are either cemented or have a press-fit fixation with inbuilt features for stabilisation.

### *De la Caffiniere prosthesis*

The first total joint replacement to become available was the De la Caffiniere Aucouturier implant. This was a ball and socket type design similar to a total hip arthroplasty (107). The implant was a metal on polyethylene total joint replacement which contained separate trapezial and metacarpal components. The polyethylene trapezial cup articulates with a cobalt-chromium metacarpal stem

(54) . The De la Caffiniere prosthesis is the most widely reported trapezial total joint arthroplasty in the literature. A large series by Van Cappelle et al showed a 72% prosthesis survival at 16 years post op. The main complication leading to failure was a loosening rate of 44%. Loosening was more common in younger patients with higher demand hands (108). Similarly, high loosening rates were reported in the case series by De Smet et al. Furthermore, no increase in key and pinch strength was measured in patients with the de la Caffiniere prosthesis compared to patients with trapeziectomy +/- LRTI (109). Another long-term follow-up study by Johnston et al showed good implant survival rate of 73.9% at a mean of 19 years. On 100-point VAS mean pain, stability and satisfaction were rated at 27,75 and 89 respectively. Mean DASH score was 33. Grip and pinch strength was less compared to the non-operated hand: 15.7kg vs 17.8kg and 3.0 vs 4.3kg respectively. Good mobility was reported on Kapandji score 8.1 vs 8.4 on the operated and non-operated hand respectively. Nicholas et al followed the outcomes of 20 patients treated with the de la Caffiniere prosthesis after 10 years and found satisfactory outcomes. 16 of the patients were pain free and had good ROM: mean abduction, flexion and extension were 39, 8.25 and 31 degrees respectively, however two patients required revision due to dislocation (110). Sondergaard et al report similar long-term outcomes (111). Albertoni et al reported on 15 cases with seven years follow up. Complete pain relief was achieved in 86% of the patients. Mean key pinch strength was 5.3kg compared to 5.2kg in the contra-lateral thumb and 5.9kg in a control group (112). Other authors reporting on the De la Caffiniere prosthesis (113, 114) report satisfactory pain relief and functional outcome but draws attention to high rates of loosening and revision associated with the prosthesis.



**Figure 25. The De la Caffiniere prosthesis (Chakrabarti, J Hand Surg Eur, 1997)**

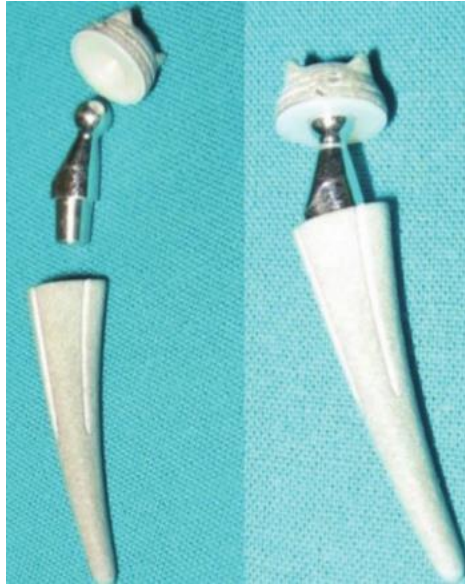
### *Ivory prosthesis*

The Ivory prosthesis is a ball-and-socket design. It is a non-constrained prosthesis which relies on proper alignment of the prosthesis for joint stability. It contains an ultra-high-molecular weight polyethylene lined trapezoidal cup and hydroxyapatite-covered metacarpal stem. The trapezoidal cup too is covered by hydroxyapatite on the outer surface. It is a total joint replacement often used in Europe (115). The 20 patient case series reported on the Ivory prosthesis by Spans et al conclude good results can be achieved by using this prosthesis. Follow up at 37 months showed pain measured on 10-point VAS score of 1.9. The Michigan hand questionnaire showed only mild to moderate impairment. Although three patients required revision due to loosening, all patients rated the outcome as good or excellent (115). Goubau et al report the outcomes of the Ivory prosthesis in 22 patients after five years. Patients rated satisfaction as high, and key and grip strength improved by 13% and 31% respectively. Prosthesis survival was 95% and the authors conclude the Ivory prosthesis has reliable medium-term results (116).

### *ARPE prosthesis*

The ARPE prosthesis too is a modular ball and socket design with separate metacarpal and trapezoidal components covered in hydroxyapatite. 65 patients were followed for a mean of 56 months. 34 patients were treated with trapeziectomy + LRTI and 31 patients with the ARPE prosthesis. No statistical difference was found between the groups with pain rated on VAS, an improvement of 7.81 was observed in the LRTI group versus 7.97 in the ARPE group. Range of motion and mean Kapandji score were greater in the ARPE group. Post operatively the ARPE group had significantly greater pinch strength, 11.8kg compared to 8.39kg in the LRTI group. However, the ARPE group also carried a higher complication rate, the re-operation rate for the ARPE group was 9.67% compared to 5.88% in the LRTI group (117). The case series reported by Martin-Ferrero followed 69 patients with ARPE prosthesis with 10-year outcome data. 10-year implant survival based on Kaplan-Meier estimates was 93.9% (118). Aparid et al report on 35 patients with the prosthesis. At a minimum five year follow up the mean DASH score was 27 and 16% of prosthesis required revision (119). Comparatively better results are reported in the series by Eecken et al. The five-year outcomes of this study show a mean DASH score of eight, mean pain score on VAS of one and a 97% prosthesis survival (120).

Longer term follow-up of the prosthesis was reported by Goddard et al. At a mean follow up of 7.8 years 93% of a total of 227 prosthesis was intact and functioning well. The authors conclude that total joint replacement is a preferable alternative treatment in a cohort of patient with 1<sup>st</sup> CMC OA (121).

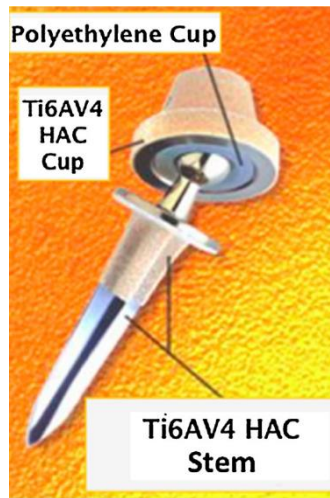

**Figure 26. The ARPE prosthesis has a modular design. Parts disassembled (left) and assembled (Robles-Molina, Orthopaedics, 2017)**

#### *The Roseland prosthesis*

The Roseland prosthesis too is a ball and socket design with a coating of hydroxy-apatite in the proximal third of the metacarpal stem. It is not a modular design, as the head, neck and shaft are fixed; a “monoblock design”. The metacarpal stem viewed end on is T-shaped to prevent rotation and reduce implant bulk within the metacarpal shaft. The trapezoidal cup is a “truncated cone” and contains a polyethylene cup and outer coating of hydroxyapatite for press-fit fixation. Semere et al report on the 10-year outcomes of the prosthesis. Complete pain relief or only occasional pain was seen in 91% of the patients and a quickDASH score of 27.6. A high complication rate of 25% was encountered (122). Zollinger et al found in a case series of 27 patients mean pain score on VAS


reduced to 1.2 post operatively. Satisfaction rated on VAS improved from 2.2 to 8.8 postoperatively. A complication rate of 15% was encountered (123).



**Figure 27. The Roseland prosthesis containing a T-shaped metacarpal stem and truncated conical trapezoidal cup (Semere, Chir Main, 2015)**

#### *The MOJE prosthesis*

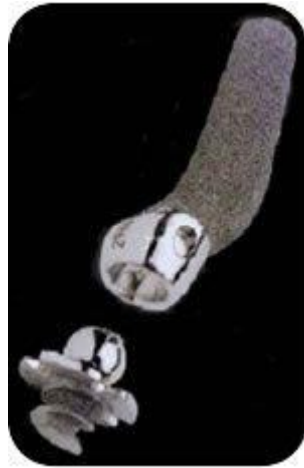The MOJE prosthesis is a ceramic reverse ball and socket design. The 'cup' component is therefore present at the base of the metacarpal. It is an uncemented prosthesis covered in the substance bioverit to improve osseointegration. Short-medium term outcomes have been reported unfavourably by Kollig et al. In the case series 15 of the 29 implants were removed due to loosening. The patients with the implant in situ had low pain scores (1.9) on VAS and DASH scores (23). Kaszap et al too caution the use of MOJE implant due to high failure rates. 9 of the 12 implants in the series required revision due to loosening (124).



**Figure 28. The Moje Acamo ceramic prosthesis. It contains a reverse ball and socket design (Hansen, J Hand Surg Eur, 2008)**

### *The Rubis II prosthesis*

The Rubis II prosthesis too is a reverse ball and socket design. It is a metal-on-metal prosthesis composed of chromium-cobalt-molybdenum alloy containing an outer coating of “pure microporous titanium by plasma torch”. The metacarpal stem is unique in design. It contains a triangular cross-section to resist rotational forces and a neck which is off-set from the stem to mimic the normal metacarpal off-set from the trapezium. The trapezium component contains a screw at the base designed to sink into the trapezium. Dehl et al report on the outcome of 115 cases treated with the Rubis II prosthesis. At 10 years post-operative implant survival was 89%. Patients had 92% and 98% of grip and key pinch strength respectively of the contralateral side. 70% of patients were pain free, and the mean VAS score at rest was 1 and with activity was 5. 99% of patients were satisfied or very satisfied. Mean quickDASH score was 30. (125)

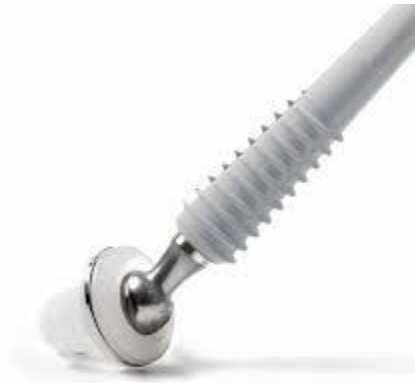

**Figure 29. The Rubis II prosthesis. It contains a reverse ball and socket design. (medicalexpocom, 16<sup>th</sup> January 2016)**

#### *The Motec prosthesis*

The Motec prosthesis is a metal-on-metal (MoM), titanium ball and socket prosthesis. It is a cementless prosthesis coated in calcium phosphate (BONIT) for osteointegration. The indications for use by Thilleman et al were Eaton stage I and II disease. At a mean of just over two years post op 40% of the implants were revised. Of the patients with the implant in situ, the DASH score was 28.4, and the median pain rating was one on a numeric rating scale. Similarly, high revision rates (30%) of the Motec MoM prosthesis were reported by Hansen et al (126). The remaining prosthesis had good functional outcomes with DASH score of nine at 29 months follow up (127).





**Figure 30. The MOTEC prosthesis. BONIT coated with metacarpal and trapezial treads to increase osteointegration and decrease loosening (download.swemac.com, 18<sup>th</sup> January 2019)**

#### *The MAIA prosthesis*

The MAIA prosthesis is a modular cement-less hydroxyapatite covered, ball and socket design implant. The neck is composed of high-nitrogen-content steel and the stem and cup are titanium alloy. The modular design contains a metacarpal stem, neck and trapezial cup. The neck has two possibilities; medium angled or high angled neck. Its centre of rotation is located on the trapezial component. The series by Bricout et al report an implant survival rate of 90.8% at 62 months follow up. Functional outcome was otherwise good, with a mean quickDash score of 14.3. 73.6% of patients were pain free and 23% had occasional pain with heavy use of the hand (128). The series by Toffoli et al also report on the outcome of 116 MAIA prosthesis. QuickDASH score improved from 61.3 to 17.5. Pre-operative pinch and grip strength were 4.3kg and 13.3kg which improved to 5.8kg and 23.4kg respectively post operatively. Furthermore, patients had good range of movement post-op. The overall revision rate was 8.3% at 6 years post op.

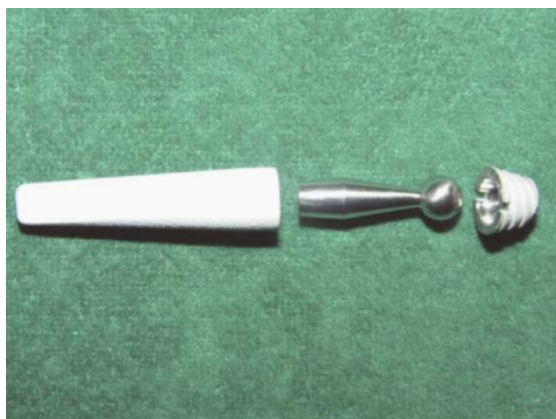


**Figure 31. The MAIA modular design prosthesis (medicalexpocom, 18<sup>th</sup> January 2019)**

### *The Elektra prosthesis*

The Elektra prosthesis is widely reported in the literature. It is a cement-less metal-on-metal prosthesis with a titanium metacarpal stem and cobalt-chromium trapezoidal cup. The trapezoidal cup has the morphology of a truncated cone containing threads which screw into the trapezium. It is hydroxyapatite coated for osseointegration. Chug et al report on the outcome of 16 Elektra prosthesis at a mean 26 months follow up. Pain scores improved significantly post op. Pinch and grip strength were not significantly different from the non-operated side. The Kapandji score was eight or greater in all thumbs. A failure rate of 6.25% (1 prosthesis) was observed (129). In contrast Klan et al report a higher revision rate of 24% at an average 36 months, increasing to 72% at 72 months. A significantly greater grip strength was observed at 2 years post op compared to pre-operative strength. However, post-operative pinch strength was not significantly different from pre-op levels. Pain measured on VAS score was significantly reduced from six week follow up. Further reductions in pain VAS score was observed at 12 weeks, one year and two years follow up (130). High rates of revision were again noted in the series by Hernandez-cortes et al, as four out of 19 patients required revision. Although QuickDASH scores were improved post operatively from 69 to 38, nine out of the 19 patients had on going pain at the TM joint (131). Ulrich-Vinther et al conducted

a comparative study of patients with base of thumb OA treated with the Elektra prosthesis and trapeziectomy+/- LRTI. The one-year outcomes show that the Elektra prosthesis group had significantly better resting pain scores measured on VAS than the tendon arthroplasty groups. Pain with activity and with ADLs were also better in the Elektra group. The prosthesis group had significantly greater key pinch, tip-pinch and grip strength than the tendon arthroplasty group. Furthermore, the post-operative rehabilitation and time to return to work was shorter for the total joint prosthesis group and there was no significant difference in rates of complications. The results of the study were short term; 1-year post-operative (132). Discouraging results on the Elektra prosthesis were published by Hansen et al. Six out of 11 patients required revision at 35 months post-op. The remaining 11 patients had a mean DASH score of 38 and grip strength which was 111% of the contra-lateral side (133). Finally, Renard et al report on the first 100 cases of base of thumb OA treated by the Elektra prosthesis at a mean follow up of 54 months. The authors report good results in terms of pain, range of movement and strength (pinch and grip) in 83 of the cases. The remaining patients encountered failures and complications (134).



**Figure 32. The Elektra hydroxyapatite covered prosthesis (Regnard, J Hand Surg Eur, 2006)**

#### *The GUEPAR prosthesis*

The GUEPAR prosthesis contains first- and second-generation designs. Both are cemented prosthesis with a ball-and-socket design. The main feature of the second-generation prosthesis is

an anatomically shaped metacarpal stem (135). Both 1<sup>st</sup> and 2<sup>nd</sup> generations have metal ball on a polyethylene cup articulation. Alnot et al report on the outcomes of the first-generation prosthesis. 90 cases were treated with the prosthesis whilst 25 cases with simple trapeziectomy. 79 of these cases were reviewed at a mean 5.25 years. Good results were reported in 92% of the patients. However, failures due to cup and stem loosening was encountered (136). Results of the 2<sup>nd</sup> generation prosthesis were reported by Lemoine et al and showed improved outcomes and rates of failure. Of the 84-prosthesis assessed post a mean of 50 months, none were revised. 80% of patients remained pain free and strength measurements were comparable to the contralateral hand (137).

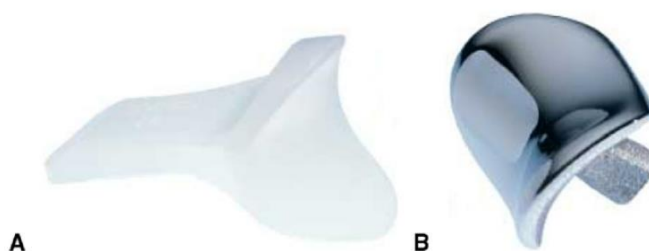


**Figure 33. The GUEPAR second generation prosthesis. It is available in 4 sizes of metacarpal stem and two neck lengths and a single sized polyethylene trapezoidal cup (Lemoine, Orthop Traumatol Surg Res, 2009)**

#### *The AVANTA prosthesis*

The AVANTA surface replacement prosthesis is of a different design to a traditional ball and socket total joint replacement. The surfaces are instead saddle shaped to mimic the native


trapeziometacarpal joint. It is a cemented prosthesis containing an ultra-high molecular weight polyethylene metacarpal component and a cobalt chromium trapezium component. The curvatures of the implant surface are more congruous than a native joint to improve stability. Initial results using the prosthesis were reported by Perez-Ubeda et al. 19 patients (1 bilateral case) were assessed at an average of 33 months. During this period 20% of implants required revision. Patients with a good outcome had significant improvements in thumb abduction and Kapandji scores. Tip and key pinch were also significantly improved respectively from 3.49kg and 3.75kg pre-operatively to 4.2kg and 4.38kg post-operatively. Grip strength too improved but failed to reach statistical significance, from 13.8kg to 16.25kg. The authors found younger patients had poorer outcomes with the prosthesis and encountered more prosthetic loosening and revisions (138). Van Rijn et al also reported on the prosthesis as it was felt in their experience better outcomes were observed than the series presented by the former authors. 15 arthroplasties in 13 patients were followed up at an average of 36 months. ROM measured by the Kapandji score, grip and pinch strength were comparable to pre-operative values but not statistically improved at follow up. Pain during activities significantly decreased from pre-operative values. One prosthetic failure occurred during the follow up period (139).



**Figure 34. The AVANTA surface replacement prosthesis. It contains saddle-like surfaces to mimic the native TM joint to improve stability and encourage similar ranges of movements to a native joint (van Rinj, J Hand Surg Am, 1982)**

### *The Braun-Cutter prosthesis*

The Braun-Cutter prosthesis is a ball and socket design first implemented in the early 1980's. It is a cemented implant containing a conical shaped titanium metacarpal stem. To prevent rotation the sides are slightly concave. Subsidence of the implant is prevented by non-polished surfaces and transverse troughs. Initial results of the prosthesis were reported by the designer, Braun et al. The series included OA patients as well as rheumatoid patients with basal thumb arthritis. Range of motion was improved post operatively in abduction and "palmar elevation". The authors also note correction of adduction deformities with the use of total joint replacement; the metacarpal and trapezium are brought back into proper alignment (140). More than 20 years since the initial report, Badia et al report the outcomes of 25 patients at an average of 59 months. 24 of the patients were completely pain free and 1 patient had minimal on-going pain. Pinch strength was measured to be 85% of the contra-lateral hand and thumb abduction was 60 degrees post-operatively. All patients had ROM to enable thumb opposition to the base of the little finger corresponding to 9/10 in the Kapandji scoring system. One case required revision (141).




**Figure 35. The Braun-Cutter prosthesis (Braun, J Hand Surg Am, 1982)**

### *The cementless trapeziometacarpal prosthesis*

The cementless prosthesis is a ball and socket design made with high fatigue resistant titanium alloy. It contains a cobalt-chrome neck and ball which articulates with a polyethylene socket. The proximal end of the trapezium cup and distal end of the metacarpal stem is covered in a -layer woven titanium mesh to encourage bony in growth. Hanunula et al report on their experience with the prosthesis in

36 patients (42 joints). During the follow up period of 34 months five implants required revision in four patients. 79% of patients had good or excellent pain relief and functional improvement. Difficulty with activities of daily living (ADL) measured on a 5-point scale showed significant improvements post-operatively in ADLs such as 'open car door, shuffle cards, remove a jar lid and turn a key' to name a few. Significant increase in key pinch strength was seen post-operatively and 85% of patients reported they would undergo the same operation again (142).



**Figure 36. The cementless trapeziometacarpal prosthesis. The trapezoidal cup and metacarpal stem is covered in a titanium mesh to promote bony ingrowth for osteointegration (Hannula, J Hand Surg Am, 1999)**

#### *The Ledoux prosthesis*

The Ledoux prosthesis is another ball and socket cementless design. The trapezoidal component is a cylindrical ring shape composed of titanium with a polyethylene cup insert. The outer surface of the trapezoidal component contains longitudinally arranged wings which expand as the polyethylene cup is inserted which anchors the trapezoidal component to the trapezium. The metacarpal stem too is titanium and contains an anatomical shape to fit into the metacarpal medulla. In the series presented by Wachtel et al a 38% revision rate was seen in the first 12 months which increased to 41% by 16 months. 75% of the surviving prosthesis assessed at an average of 25.3 months had on going pain with loading of the joint, movement or at rest. Due to the high failure rate the authors do not recommend the implant (143).

### *The Mayo, Steffee and Bichat prosthesis*

The Mayo, Steffee and Bichat prosthesis are all cemented ball and socket designs containing a metal (titanium or cobalt-chromium) metacarpal stem and polyethylene trapezoidal cup. An asymmetrical trapezoidal cup is a key difference in the Mayo implant (107). Amadio et al reported on 10 cases treated with the Mayo implant. Post-operative pinch strength was comparable to pre-operative levels, 5.5kg vs 5.6kg respectively. Grip strength was reduced post-operatively from 40kg to 28kg. The authors however make note that pre-operative grip strength was inaccurately recorded. One failure occurred in the series (53). Alnot et al reported on the Bichat prosthesis in 15 patients (17 arthroplasties) at a mean three years follow up. Good mobility and strength were achieved in 13 cases. Three implant failures occurred during the follow up period (144). Ferrari et al reported the outcomes of the first 45 cases treated using the Steffee prosthesis. 33 patients had complete pain relief, seven patients had occasional pain relief "once or twice a month" and two patients had pain with prolonged use of the hand. Three implant failures were reported. Majority of patients >70% had strength and dexterity to carry out ADLs with ease (145).

### *Hemiarthroplasty*

An implant grouped under Hemiarthroplasty design replaces only the metacarpal surface of the joint. Similar to the total joint replacement prosthesis, hemiarthroplasty implants may also be cemented or have press-fit fixation. The implants in this category are also diverse in design and the materials used.

### *Pyrohemisphere, NuGrip and Saddle PyroCarbon Implants*

The Pyrohemisphere, NuGrip and Saddle PyroCarbon implants are all composed of pyrocarbon. As previously discussed, the material has excellent biocompatibility and an elastic modulus similar to cortical bone (146). The implants are from the same manufacturer however have different design features. As the name suggests, the Pyrohemisphere has a head which terminates in a hemisphere. The NuGrip implant contains a collar between the metacarpal stem and the spherical head of the



implant. The Saddle implant is concave, like a metacarpal base to improve congruity with the trapezium (147). Martinez de Aragon report of the outcomes of 49 patients treated with the Pyrohemisphere implant at an average of 22 months follow up. A high failure rate of 20% was encountered. 35 patients with in situ implants had complete pain relief, and a further six patients reported mild or occasional pain. 81% of patients were satisfied with the operation. Grip, key pinch and tip pinch compared to the contralateral hand was 86%, 92% and 95% respectively (148). Stillwater et al also reported on the radiographic outcomes of the Pyrohemisphere implant at an average 13 months follow op. Radiographic loosening was seen in 31 x-rays however only 11 of the x-rays were associated with adverse outcomes. The authors emphasise the discrepancy between radiographic changes and clinical outcomes (146). The outcomes of 45 patients (53 joints) treated with the NuGrip implant was reported by Aita et al at a mean follow up of 42 months. Pain measured on VAS score was 1.37, thumb range of movement increased to 95% of the contralateral side and DASH score was 9.98. No implant failures occurred however five patients underwent re-operation due to dislocation requiring stabilisation with capsuloplasty. A good clinical outcome was achieved subsequently in the patients with dislocation (149). No case series or higher-level evidence has been published assessing the outcomes of the Saddle PyroCarbon implant to our knowledge.



a)



b)



c)

**Figure 37. The pyrocarbon hemiarthroplasty implants. From left to right is Pyrohemisphere (a), NuGrip (b) and Saddle PyroCarbon Implant (c) (handconsultant.com, integralife.com, 16<sup>th</sup> January 2016)**

#### *BioPro Modular Thumb*

The stem of the BioPro implant is coated with porous titanium to allow bony ingrowth and cementless fixation. In contrast to many other implants which have an alignment which is perpendicular to the joint surface, the BioPro contains a varus angulation which is designed to permit anatomical alignment of the metacarpal on the trapezium. The outcomes of 159 arthroplasties in 138 patients at an average follow up of 72.1 months were published by Pritchett et al. Majority of arthroplasties (135 thumbs) resulted in pain relief, and tip pinch strength improved from 4.9kg pre-operatively to 6.44kg post operatively. The implant had a 94% survival rate at 72.1 months (150).



**Figure 38. The BioPro Modular Thumb. The metacarpal stem has a varus arrangement in relation to articular head of the implant for an anatomical alignment (150)**

#### *Swanson titanium prosthesis*

The above implant was created in an effort to address the silicone synovitis encountered with the Swansons silicone implant. The implant contains a rectangular stem in cross-section and a hemispherical head (151). The results of 105 arthroplasties (95 patients) were reported by Swanson et al at an average five years follow up. All, except three patients were extremely satisfied with the outcomes of pain relief, range of motion and strength. Tip pinch was improved from 2.3kg to 4.1kg, key pinch from 4.1kg to 5.4 and grip strength from 18.1kg to 23.6kg. Phaltanker et al also report on

their experience with the implant in 18 patients (19 arthroplasties). The outcomes of the arthroplasty hand were compared to the contralateral hand at 34 months post-op. The mean grip, tip pinch and key pinch were 23kg, 4.8kg and 3.6kg respectively, compared to the contralateral hand values of 22kg, 5kg and 4kg. The mean VAS score for pain was three out of 10. Thumb abduction was significantly improved compared to the contralateral thumb (152). Naidu et al report the outcomes of the titanium arthroplasty less favourably. 50 arthroplasties were assessed at two years post-operative. A 20% failure rate (10 implants) was encountered. The remaining patients showed significant improvements in the DASH scores and the hand questionnaire assessing functional outcome. However, continued weakness remained compared to the contralateral thumb (153).



**Figure 39. The Swanson titanium prosthesis (medicalexpo.com, 16<sup>th</sup> January 2016)**

Isolated cases of base of thumb hemiarthroplasty performed using metatarso-phalangeal implant and MOJE implants are reported by Conolly et al (52) and Malhotra et al (154). Although good outcomes were reported, these are creative uses of the implants designed to be used differently.

## Rationale for Research

Implant based modalities of treatment have been designed to address the disadvantages of non-implant techniques and the review of the literature suggests that implant arthroplasty has the potential to deliver improved outcomes. However, the main concern with the currently available implants are high complication and failure rates. In the patients which implant arthroplasty is successful patients do benefit from increased thumb stability, preservation of thumb length and grip strength, overall greater patient satisfaction and a faster road to recovery. Therefore, the advantages to be gained by using an implant are well worth pursuing if implant related complications can be addressed through the development of an ideal implant. Prior to fruition of such an implant it is necessary to define, with as much accuracy, the morphological requirements of the implant, as morphology is critical to function. The current thesis aims to investigate and define the morphology of an ideal trapezial implant for base of thumb OA.

## Aims and Research Hypothesis

The hypotheses of the research project are that the morphology or shape of the implant is crucial to its function.

An implant with an ideal morphology aims to:

- alleviate the pain associated with base of thumb OA,
- Restore thumb pinch and grip strength and
- Provide stability to the thumb during pinch and power grip
- Correct adduction deformity
- Have acceptable complication and failure rates
- Be technically feasible

An implant which meets these requirements would therefore possess an ideal morphology.

# **CHAPTER 2**

## **Complications of trapeziometacarpal implants: A systematic review**

## CHAPTER 2: Complications of trapeziometacarpal implants: A systematic review

### Chapter 2 research outputs:

#### Published:

- Ganhewa AD, Wu R, Chae MP, Miller G, Tobin V, Rozen WM, Hunter-Smith DJ. The Complications of Trapeziometacarpal Implants for Base of Thumb Arthritis. ANZ J. Surg. 2018; 88(S1) 71-79
- Hunter-Smith DJ, Ganhewa AD, Wu R, Chae MP, Tobin V and Rozen WM. Mechanisms of failure in base of thumb implant arthroplasty: A systematic review. Journal of Hand Surgery (European Volume) 2018, Vol. 43(Supplement 2) SS107

#### Accepted:

- Ganhewa AD, Wu R, Chae MP, Miller G, Tobin V, Smith JA, Rozen WM, Hunter-Smith DJ. Failure rates of base of thumb arthritis surgery: A Systematic Review. J Hand Surg Am.

#### Presented:

- Ganhewa AD, Wu R, Chae MP, Miller G, Tobin V Hunter-Smith DJ, Rozen WM. The complications of trapeziometacarpal prosthesis for base of thumb arthritis: Systematic Review. Oral presentation, Celebrating research Peninsula Health 2017, Frankston Hospital.
- Ganhewa AD, Wu R, Chae MP, Miller G, Tobin V Hunter-Smith DJ, Rozen WM. Complications of Implant Arthroplasty for Basal Thumb Arthritis: A systematic review. Oral presentation, Surgical symposium Peninsula health 2017, Frankston Hospital.
- Hunter-Smith DJ, Ganhewa AD, Wu R, Chae MP, Tobin V, Rozen WM. Mechanisms of failure in base of thumb implant arthroplasty: A Systematic Review. FESSH Congress. Copenhagen, Denmark 13-16 June 2018
- Ganhewa AD, Wu R, Chae MP, Miller G, Tobin V Hunter-Smith DJ, Rozen WM. The complications of trapeziometacarpal implants for base of thumb arthritis: A systematic review. RACS ACS, Sydney 7-11<sup>th</sup> May 2018
- Ganhewa AD, Wu R, Chae MP, Miller G, Tobin V, Smith JA, Rozen WM, Hunter-Smith DJ.. Mechanisms of failure in base of thumb implant arthroplasty: A Systematic Review. ASSH Annual meeting. Boston, USA 13-15<sup>th</sup> September 2018

## Introduction

Progression of design and technology is a seamless process, each advance built upon an almost identical version of its predecessor. American novelist Mark Twain stated that;

“There is no such thing as a new idea. It is impossible. We simply take a lot of old ideas and put them into a sort of mental kaleidoscope. We give them a turn and they make new and curious combinations indefinitely; but they are the same old pieces of coloured glass that have been in use through all the ages. “

~Mark Twain

The pursuit of an ideal trapezoidal implant is not a new quest. This much is evident from the review of the trapezoidal implant arthroplasty literature. As discussed in the previous chapter, the history of implants extends beyond 50 years. Thus, at least 50 years of experience and wisdom exists in the design and manufacture of trapezoidal implants. To draw from this wealth of experience and learn from the complications which has afflicted the current and older designs helps to avoid the same pitfalls. Therefore, systematically reviewing the complications and mechanisms of failure in existing implants is an important and critical step in the design of a new implant with an ideal morphology. This systematic review aims to identify implants used for basal thumb arthritis discussed in the English literature, group them by design concept and assess the complications leading to implant failure in each design group. Implant design features which lead to low or high complication and failure rates can then be identified as favourable or needing to avoid.

## Methods:

### Inclusion Criteria

A systematic review of the literature was performed according to the Preferred Reporting Items for Systematic reviews and Meta-Analyses (PRISMA) guidelines (155). The inclusion criteria comprised articles: 1. reporting on treatment of base of thumb OA using any form of implant arthroplasty; 2. limited to English language; 3. of all levels of evidence, from level I, randomised control trials to level IV, case series, according to the 2011 Oxford Centre for Evidence-Based Medicine (OCEBM) definitions; 4. Stated the type of implant used, the number of arthroplasties performed and the mean length of follow up.

### Exclusion Criteria

The exclusion criteria were: 1. review articles; 2. biomechanical and experimental studies; 3. cadaver and animal studies; 4. non-implant arthroplasty e.g. trapeziectomy and tendon interposition arthroplasty.

### Information source and Search strategy

Medical databases PubMed, Medline, Embase and the Cochrane database of systematic reviews were searched on 27<sup>th</sup> May 2017 using the following search strategy: A Boolean combination of key word and Mesh terms were used to search the concepts of: Thumb, trapeziometacarpal (TM) joint, trapezium, first carpometacarpal joint, osteoarthritis, implant, prosthesis, arthroplasty, hemiarthroplasty and joint replacement. A bibliographic hand search was done for all articles included for full text review and all relevant review articles in the past 10 years.

### Study selection

All search results from data bases were screened by title and abstract for relevance. If relevant, the article was placed for full text review. Articles were included post full text review according to the



inclusion and exclusion criteria. Two studies by Wachtl et al (143, 156) and 2 studies by De Smet et al (157, 158) contained data from the same population, therefore the 1996 Wachtl et al and 2004 De Smet et al studies were excluded from the review.

### Data Items

The complete list of data items sought is as follows: Sample size (implants and patients), gender of patients, mean age, stage of OA, implant in dominant hand, mean follow up, implant name, design, fixation, length of post-operative splinting, complication, number with complication, number revised, timing of complication, author comment on cause of failure, salvage procedure, number with salvage procedure, author advice on future use of implant.

### Data collection process

The outcome measures of this review included any reported complication, revision and failure of the implant. All data collected by reviewer, DG, using excel spreadsheet and a data dictionary. The collection process was confirmed by a second reviewer RW.

### Synthesis of results

The identified implants were divided into five different classes, as described in the previous chapter, based on the classification system of trapezial implants described by Vitale et al (54). The classification system groups the implants by basic design concept. The five main designs of trapezial implants were:

1. Total joint replacement: Implants containing separate trapezial and metacarpal components were classed as total joint replacements.
2. Hemiarthroplasty: Implants containing a sole metacarpal component which replaces only the metacarpal surface.

3. Interposition with partial trapezial resection: Implants which are interposed between the metacarpal and partially excised trapezium.
4. Interposition with total trapezial resection: Implants which are interposed between the metacarpal and scaphoid post total trapeziectomy
5. Interposition with no trapezial resection: Implants which are interposed between the metacarpal and trapezium without any surgical resection on the trapezium.

The data was combined for each implant design group and also an overall total for all implants. Failure and complication rates were calculated based on the method employed by the Australian Orthopaedic Association National Joint Replacement Registry (AOANJRR) to calculate failure rates of joint replacements. Similar to the non-implant arthroplasty review, implant-years were firstly derived by multiplying the number of arthroplasties by the mean length of follow up of the study. A failure and complication rate for each implant and group of implants was then calculated for the number of complications or revisions per 10 implant-years.

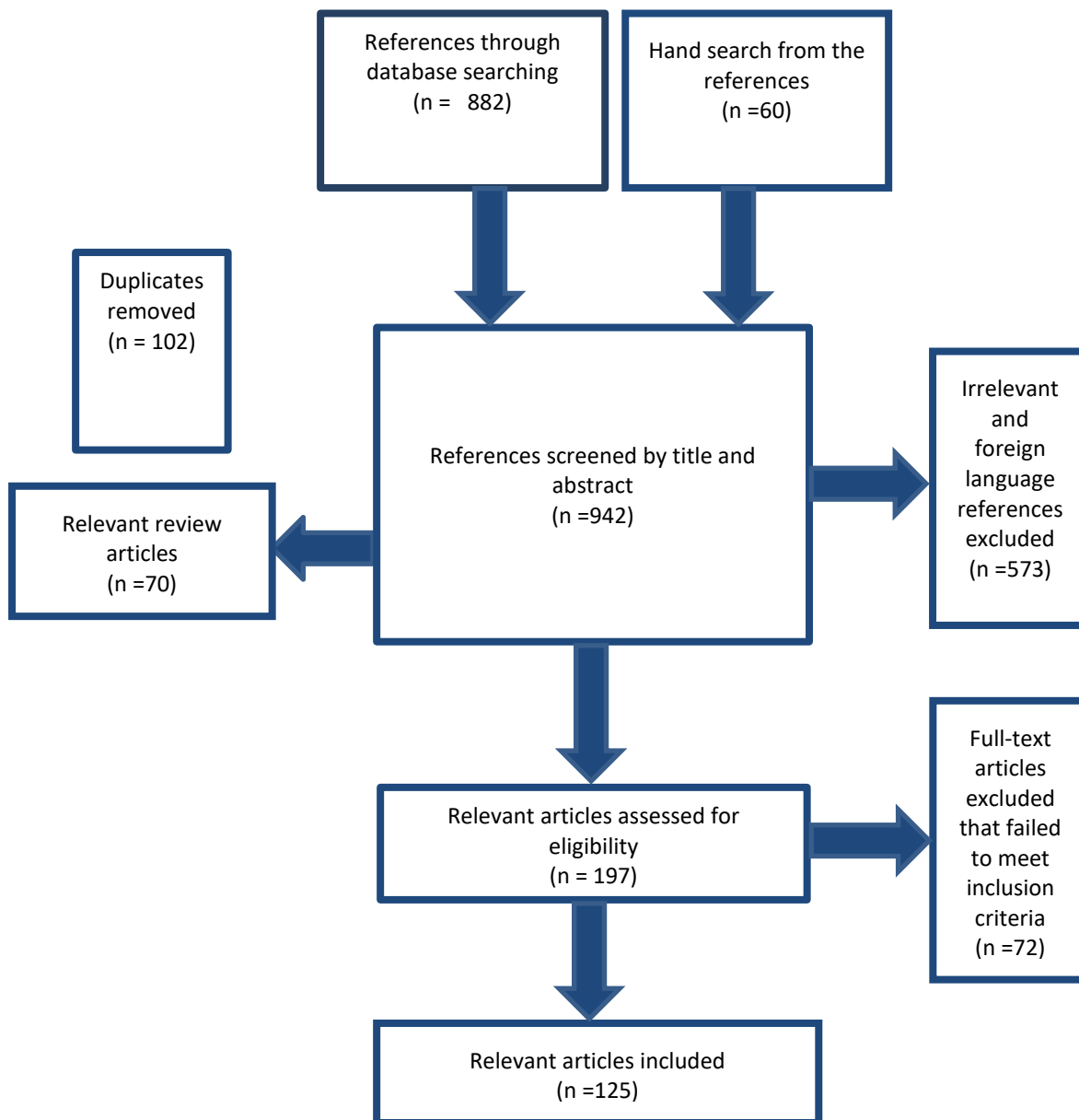
#### Identification of implants with high failure rates and unfavourable morphology

Currently guidelines or implant registries are not implemented to detect TM implants with high failure rates. In contrast, the final chapter of the AOANJRR annual report is dedicated to identifying orthopaedic prosthesis (e.g. Hip and knee) with higher than anticipated rates of revision. The annual report states, "The first stage is a screening test to identify prostheses that differ significantly from the combined revisions per 100 observed component-years of all other prostheses in the same class". The first criteria in the screening stage is "the revision rate (per 100 component-years) exceeds twice that for the group".

Therefore, we have used this screening criteria as a surrogate to identify TM implants which have a high rate of failure and unfavourable design morphology. As previously introduced the five classes or groups of trapezial implants are total joint replacement, hemiarthroplasty and interposition. The interposition class is further divided depending on the degree of trapezial resection; partial resection, total resection or no resection. The overall failure rate for each class of implants was derived using the method described above. This rate was then doubled to provide an acceptable or anticipated rate of failure for each class of trapezial implants. Implants with a failure rate exceeding the anticipated rate for each class was then identified.

## Results

### Study selection



**Figure 40. PRISMA flow chart**

### Study Characteristics



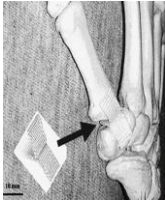

The level of evidence of the studies included in the implant arthroplasty literature was not high; Only five of the studies were prospective (RCT or prospective cohort) (table 3). Majority of the included

studies were retrospective, case series. Appendix 2 shows a full list of studies included and study characteristics.

	Level I	Level II	Level III	Level IV	Total
No. Of Articles	4	2	21	98	125

**Table 3. Level of evidence of articles included according OCEBM, 2011**

From the 125 articles included, 51 types of implant arthroplasty were identified. A total number of 5,416 implant arthroplasties were done in 5313 patients owing to numerous bilateral cases. 83% of the population were female, and the implant was placed in the dominant hand 57% of the time. Mean age of patients at the time of operation ranged from 51-71 years old. Mean length of follow-up of the studies was 6-228 months.

	<i>Total Joint Replacement</i>	<i>Hemiarthroplasty</i>	<i>Interposition: Partial trapezial resection</i>	<i>Interposition: Total Trapezial replacement</i>	<i>Interposition: No trapezial resection</i>	<i>Total</i>
<i>Number of articles</i>	46	11	25	46	2	130
<i>number. of different Implants</i>	18	6	12	13	2	51
<i>Total number of Arthroplasties</i>	2352	604	669	1,767	24	5,416
<i>Total number of implant-years</i>	13456	1875	1,834	7,908	67	25140
<i>An example</i>					NA	

**Table 4: Number of articles, different implant types, number of arthroplasties and an example from each implant design group**

Identified implants:

Below is a list of implants included in the review. It is comprehensive, however is non-exhaustive, and does not include all trapezial implants in existence. The implants discussed in articles meeting the inclusion criteria were included.

1. *Total Joint replacement*: Separate trapezial and metacarpal components, often but not limited to a ball and socket design:

- a. De la Caffiniere prosthesis
- b. Ivory TMC prosthesis
- c. ARPE TM prosthesis
- d. Roseland prosthesis
- e. Moje Acamo CMC1 prosthesis
- f. Rubis II prosthesis
- g. Motec Metal on Metal (MoM) CMC prosthesis
- h. Motec Polyethylene (PE) cemented prosthesis
- i. MAIA prosthesis
- j. Elektra MoM prosthesis
- k. Elektra PE cemented prosthesis
- l. GUEPAR prosthesis (1st generation)
- m. GUEPAR prosthesis (2nd generation)
- n. Avanta SRTM Trapeziometacarpal (TMC) prosthesis
- o. Braun-Cutter TM joint prosthesis
- p. The cementless trapeziometacarpal prosthesis
- q. Ledoux Prosthesis
- r. Cemented metal and plastic Implant (Mayo designed)
- s. Steffee Prosthesis
- t. Bichat Total Arthroplasty

2. *Hemiarthroplasty*: Replacement of the metacarpal joint surface with or without partial trapezial resection:

- a. Pyrohemisphere TM prosthesis
- b. NuGrip
- c. BioPro Modular thumb prosthesis
- d. Swanson titanium convex condylar prosthesis
- e. Silicone Metatarso-phalangeal implant
- f. Convex condylar silicone implant

3. *Interposition with partial trapezial resection*: Implant material interposed between the trapezial and metacarpal joint surface post partial resection of the trapezium:

- a. Pyrocardan implant
- b. AREX Polylactic acid (PLLA) implant
- c. Cartiva Polyvinyl acid (PVA) implant
- d. Artelon spacer
- e. PyroDisk
- f. Pyrocarbon Spherical implant
- g. Orthrosphere
- h. Interposition (Button) Silicone-Rubber
- i. Ashworth Implant
- j. Silicone Ball
- k. Kessler Implant
- l. Proplast stabilised trapezial implant

4. *Interposition with total trapezial replacement*: Implant material is interposed between metacarpal and scaphoid post total trapeziectomy.

- a. Pi2 Implant
- b. Tie-in Trapezial Implant
- c. Polyethylene-mesh Implant



- d. Swanson Trapezial Implant
  - e. Gelfoam Spacer
  - f. Helal Prosthesis
  - g. Gore-Tex
  - h. Niebauer Implant
  - i. Tecoflex Polyurethane Implant
  - j. Eaton Trapezial Implant
  - k. GraftJacket Max strip
5. *Interposition with no trapezial resection*: Implant material interposed between trapezium and metacarpal without any resection of the trapezium:
- a. Articulinx Intermetacarpal cushion
  - b. Silicone rubber sponge interposition arthroplasty

Complications:

Thirteen common implant related complications and a further few rare complications were identified.

The common complications were:

1. Dislocation
2. Aseptic loosening
3. Subluxation
4. Radiological loosening with periprosthetic lucency
5. Implant subsidence
6. Implant fracture
7. Peri-prosthetic fracture
8. Implant resorption or wear
9. Osteolysis

10. Periprosthetic ossification
11. Foreign body reaction
12. Infection
13. Persisting pain.

Rarer complications included:

1. Cement extrusion into the palm with encapsulation of the neurovascular bundles.
2. Osteonecrosis of the trapezium
3. Tendon rupture (i.e. FCR, EPL and EPB)
4. Tendonitis (i.e. De Quervain's, FCR and APL)

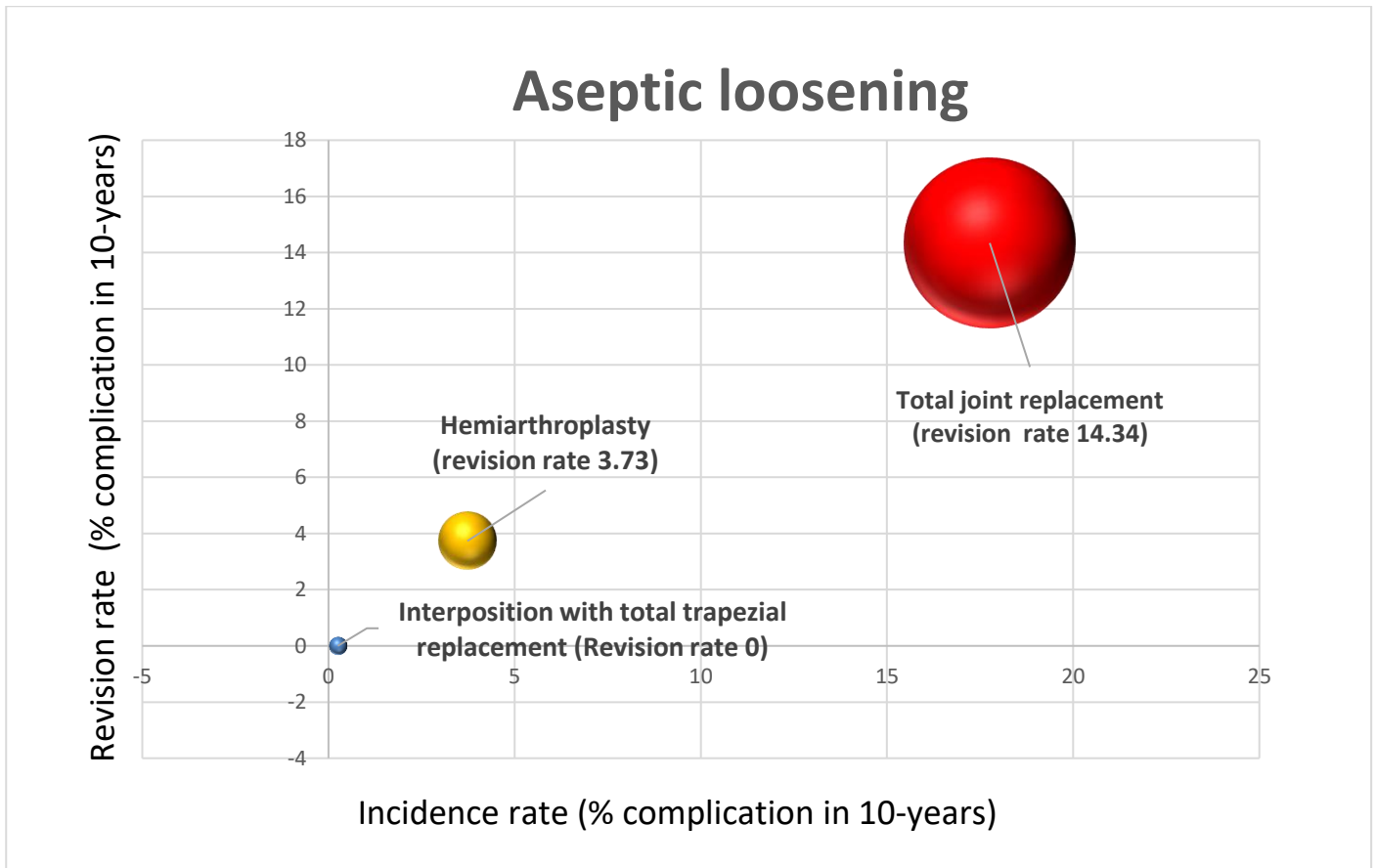
All listed complications except radiological loosening and implant wear contributed towards a revision procedure of at least one implant. The most common reasons for implant revision differed among the different design groups. The most pertinent results of each complication is discussed below. Each complication is accompanied by a bubble graph which compares the incidence and revision rates of each complication among the groups of implants.

### *Aseptic loosening*

Aseptic loosening was the most common complication leading to implant revision overall and in the total joint replacement (TJR) group. All cases of revision secondary to aseptic loosening were from the TJR and hemiarthroplasty groups. However, revision due to aseptic loosening was over three times as high in the TJR group (10-year rate 14.34%) than the hemiarthroplasty group (10-year rate 3.73%). It was not only a common complication, but also a severe one too. If encountered it carried a high risk of implant revision, 81% of all cases encountering aseptic loosening were revised in the TJR and 100% in the hemiarthroplasty groups.

<b>Aseptic loosening</b>	<i>Total Joint Replacement</i>	<i>Hemiarthroplasty</i>	<i>Interposition: Partial trapezial resection</i>	<i>Interposition: Total Trapezial replacement</i>	<i>Interposition: No trapezial resection</i>	<i>Total</i>
<i>Number</i>	239	7	0	2	0	248
<i>encountering complication</i>						
<i>Total number of Arthroplasties</i>	2352	604	669	1,767	24	5,416
<i>Percentage (%) proportion with complication</i>	10.16	1.16	0.00	0.11	0.00	7.96

**Table 5: Proportion of patients in each group with aseptic loosening.**



**Figure 41: The bubble graph represents the rates of aseptic loosening in the implant groups. The x-axis details how commonly the complication was encountered. The y-axis details how commonly the complication resulted in an implant revision. The size of the spheres relates to the proportion of patients in each group encountering the complication.**

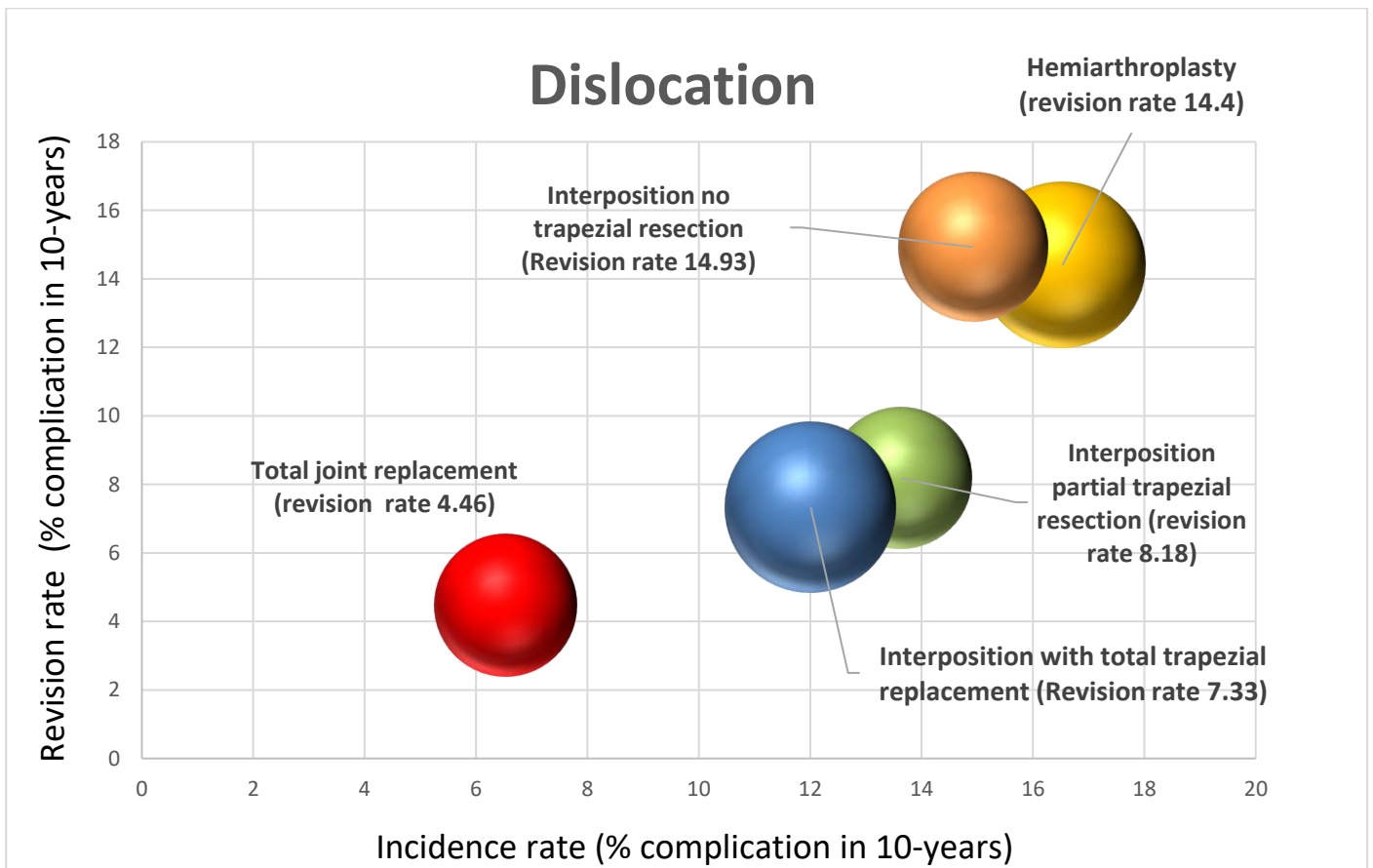
### *Dislocation*

Dislocation was overall the second most common complication leading to implant failure. It was a complication encountered across all design groups, and highest in the interposition with no trapezial resection group. Dislocation was the most common cause of revision in the hemiarthroplasty (10-year rate of 14.4%) and interposition with total trapezial resection (10-year rate 7.33%) groups. It was the second most common cause of revision in the TJR (10-year rate 4.46%), interposition with partial (10-year rate 8.18%) and no (10-year rate 14.93%) trapezial resection groups. The reported directions of dislocation were: volar (19 cases), radial (18 cases), dorsal (17 cases), dorso-radial (8 cases) and ulnar (2 cases). Although dislocation was seen across all groups, the proportion of dislocations which proceeded to implant revision differed among the different groups. Interposition

with partial and total trapezial resection groups had lower proportions of implants which were revised than did the total joint replacement and hemiarthroplasty groups if a dislocation was encountered. 60% and 61% in the interposition with partial and total trapezial resection groups respectively versus 85% and 68% in the hemiarthroplasty and TJR groups respectively.

<b>Dislocation</b>	<i>Total Joint Replacement</i>	<i>Hemiarthroplasty</i>	<i>Interposition: Partial trapezial resection</i>	<i>Interposition: Total Trapezial replacement</i>	<i>Interposition: No trapezial resection</i>	<i>Total</i>
<i>Number</i>	88	31	25	95	1	240
<i>encountering complication</i>						
<i>Total number of Arthroplasties</i>	2352	604	669	1,767	24	5,416
<i>Percentage (%) proportion with complication</i>	3.74	5.13	3.74	5.38	4.17	4.43

**Table 6: Proportion of patients in each group with dislocation.**



**Figure 42: The bubble graph represents the rates of dislocation in the implant groups. The x-axis details how commonly the complication was encountered. The y-axis details how commonly the complication resulted in an implant revision. The size of the spheres relates to the proportion of patients in each group encountering the complication.**

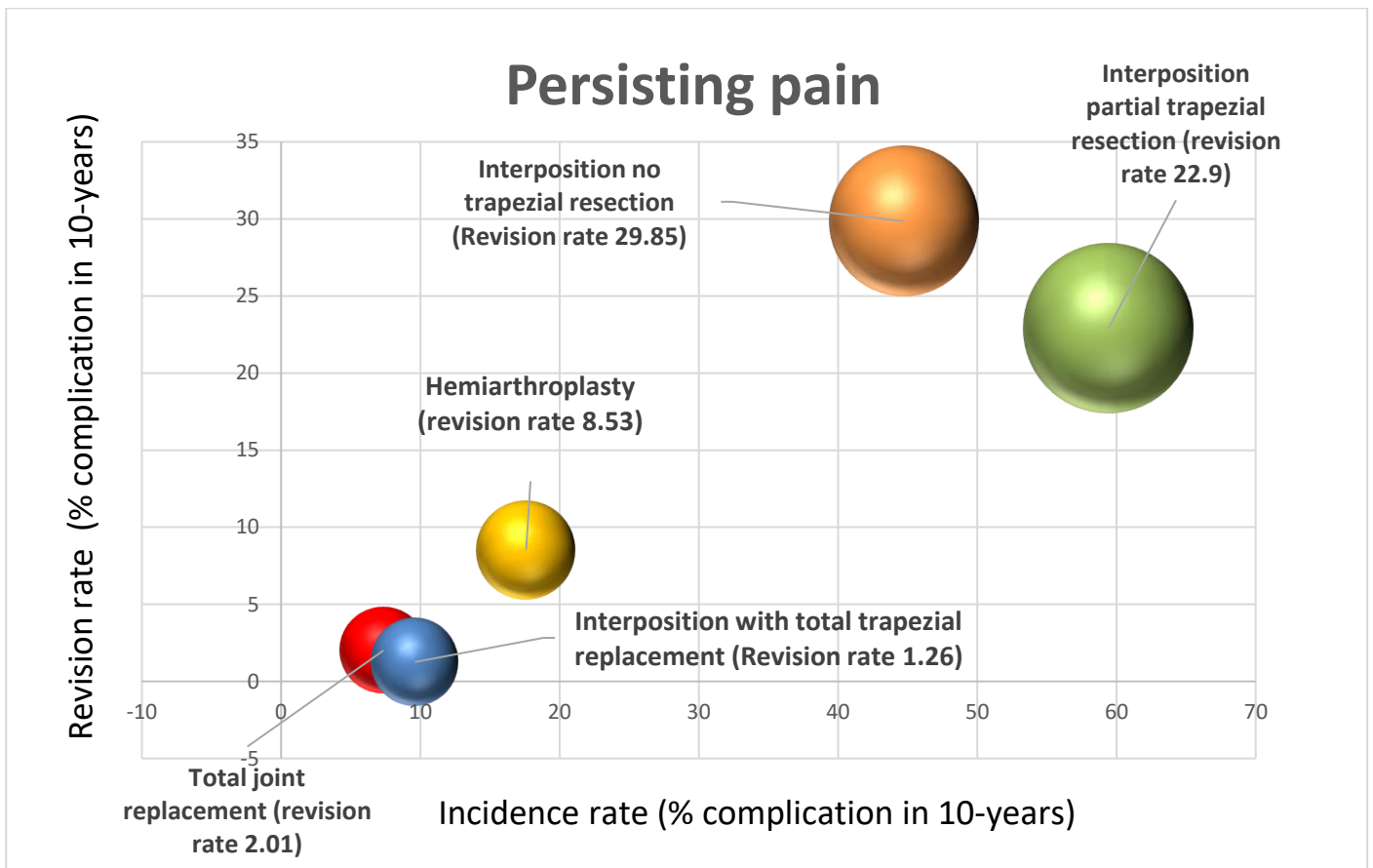
### *Persistent pain*

Persistent pain was overall the most common complication encountered, and the third most common to cause implant failure. Only 30% of cases were revised if persisting pain was encountered leading to an overall 10-year revision rate of 3.86%. Revision rates due to persisting pain were higher in the hemiarthroplasty, interposition with partial and no trapezium resection groups (8.53%, 23% and 30% respectively) groups, when compared to the interposition with total trapezium resection and TJR groups (2.01% and 1.26% respectively). Revision if persisting pain was encountered was lowest in the interposition with total trapezium resection group (13% or 10/76 cases) compared to the other groups: 27%(29 out of 99 cases), 48%(16 out of 33 cases), 38%(42 out of 109 cases) and 66% (2

out of 3 cases) for TJR, hemiarthroplasty, interposition with partial and no trapezial resection respectively.

<b>Persisting pain</b>	<i>Total Joint Replacement</i>	<i>Hemiarthroplasty</i>	<i>Interposition: Partial trapezial resection</i>	<i>Interposition: Total Trapezial replacement</i>	<i>Interposition: No trapezial resection</i>	<i>Total</i>
<i>Number</i>	99	33	109	76	3	320
<i>encountering complication</i>						
<i>Total number of Arthroplasties</i>	2352	604	669	1,767	24	5,416
<i>Percentage (%) proportion with complication</i>	4.21	5.46	16.29	4.3	12.5	5.91

**Table 7: Proportion of patients in each group with persisting pain.**



**Figure 43: The bubble graph represents the rates of persisting pain in the implant groups. The x-axis details how commonly the complication was encountered. The y-axis details how commonly the complication resulted in an implant revision. The size of the spheres relates to the proportion of patients in each group encountering the complication.**

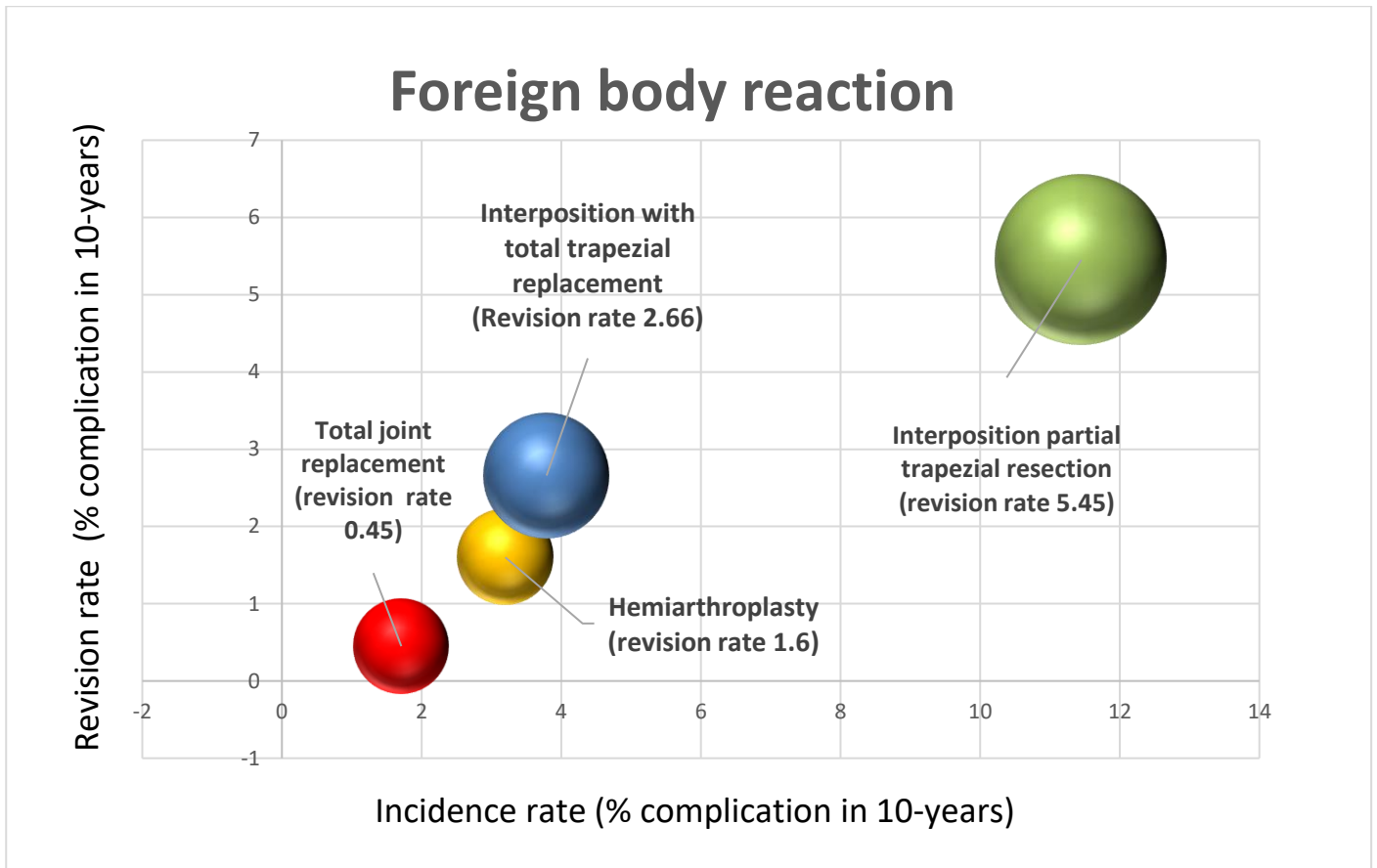
#### *Foreign body reaction*

Foreign body reaction was overall the fourth most common reason contributing to implant revision. It is a complication that was most commonly seen in the interposition with partial and total trapezial resection groups (10-year revision rates of 5.45% and 2.66% respectively). If encountered it carried a high rate of revision in all groups: 70% (21 out of 30 cases) and 48% (10 out of 21 cases) for interposition with total and partial trapezial resection groups respectively and 50% and 26% for hemiarthroplasty and TJR groups respectively.



<b>Foreign body reaction</b>	<i>Total Joint Replacement</i>	<i>Hemiarthroplasty</i>	<i>Interposition: Partial trapezial resection</i>	<i>Interposition: Total Trapezial replacement</i>	<i>Interposition: No trapezial resection</i>	<i>Total</i>
<i>Number</i>	23	6	21	30	0	80
<i>encountering complication</i>						
<i>Total number of Arthroplasties</i>	2352	604	669	1,767	24	5,416
<i>Percentage (%) proportion with complication</i>	0.98	0.99	3.14	1.70	0.00	1.48

**Table 8: Proportion of patients in each group with foreign body reaction.**



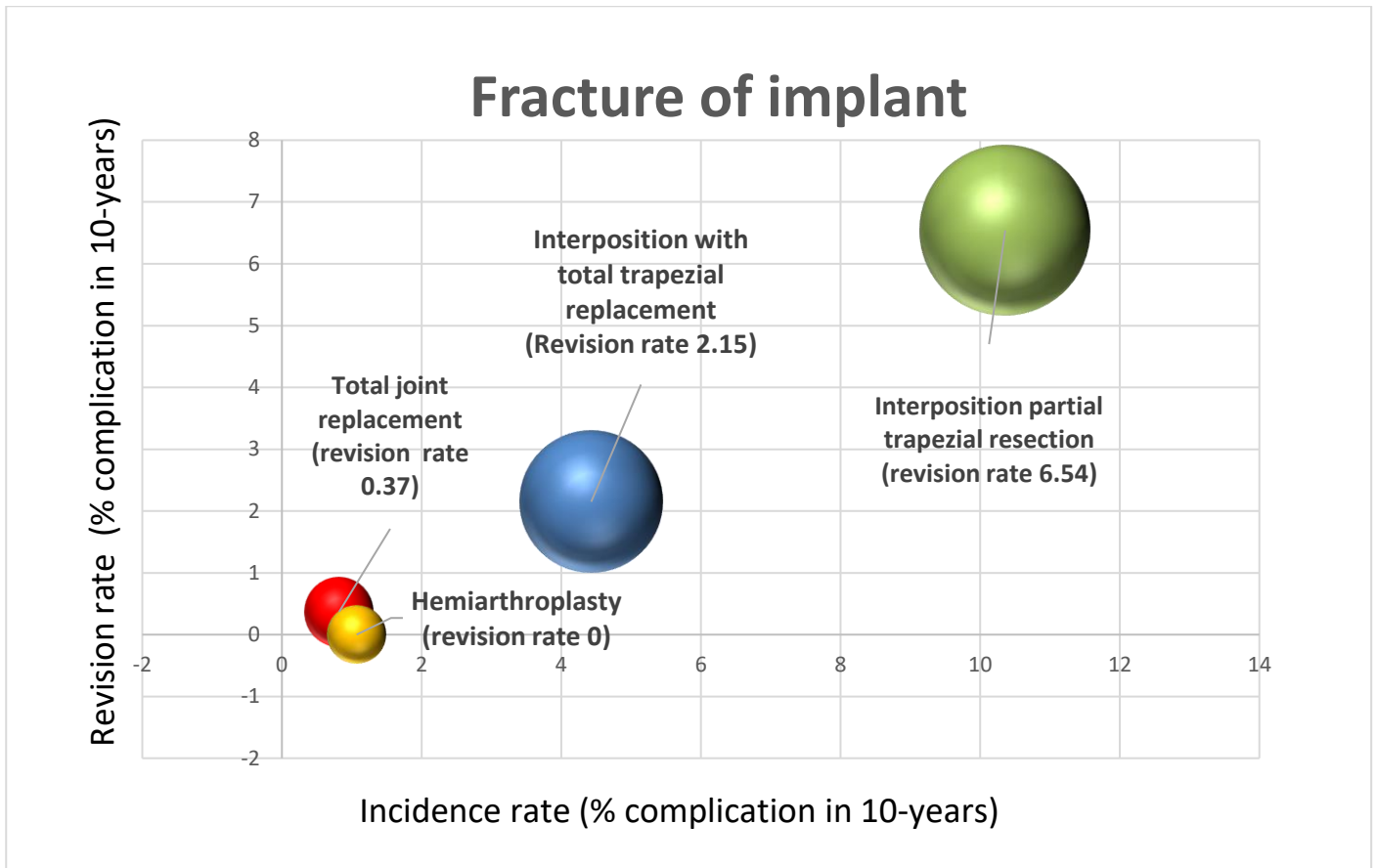
**Figure 44:** The bubble graph represents the rates of foreign body reaction in the implant groups. The x-axis details how commonly the complication was encountered. The y-axis details how commonly the complication resulted in an implant revision. The size of the spheres relates to the proportion of patients in each group encountering the complication.

*Fracture of implant:*

Fracture of implant occurred across all design groups. The highest revision rates due to implant fracture were the interposition with partial resection (10-year revision rate of 6.54%) and total trapezial replacement (10-year rate of 4.43%) groups. If encountered it led to implant revision in 51% of all cases.

<b>Fracture of implant</b>	<i>Total Joint Replacement</i>	<i>Hemiarthroplasty</i>	<i>Interposition: Partial trapezial resection</i>	<i>Interposition: Total Trapezial replacement</i>	<i>Interposition: No trapezial resection</i>	<i>Total</i>
<i>Number</i>	11	2	19	35	0	67
<i>encountering complication</i>						
<i>Total number of Arthroplasties</i>	2352	604	669	1,767	24	5,416
<i>Percentage (%) proportion with complication</i>	0.47	0.33	2.84	1.98	0.00	1.24

**Table 9: Proportion of patients in each group with fracture of implant.**



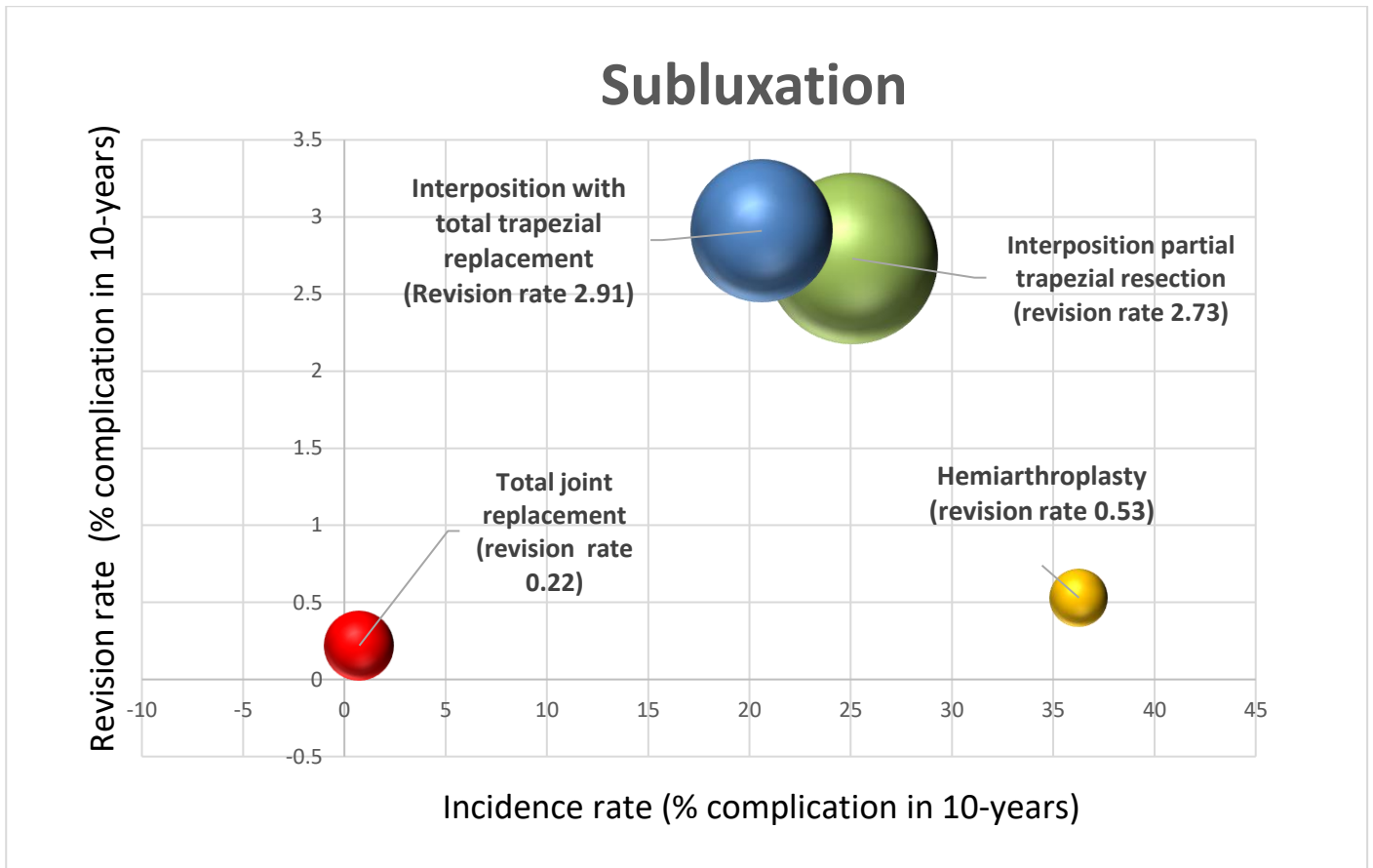
**Figure 45: The bubble graph represents the rates of implant fracture in the implant groups. The x-axis details how commonly the complication was encountered. The y-axis details how commonly the complication resulted in an implant revision. The size of the spheres relates to the proportion of patients in each group encountering the complication.**

#### *Subluxation*

Subluxation was most commonly encountered in the hemiarthroplasty group, however the groups with highest rates of revision due to subluxation were interposition with partial and total trapezial resection (10-year rates of 2.73% and 2.91% respectively) as a greater proportion of patients proceeded to implant revision (11% and 14% respectively) in these groups compared to the hemiarthroplasty group (1.47%). Although less commonly encountered, it was a more severe complication in the TJR group, as 30% of patients with subluxation proceeded to revision.

<b>Subluxation</b>	<i>Total Joint Replacement</i>	<i>Hemiarthroplasty</i>	<i>Interposition: Partial trapezial resection</i>	<i>Interposition: Total Trapezial replacement</i>	<i>Interposition: No trapezial resection</i>	<i>Total</i>
<i>Number</i>	10	68	46	163	0	287
<i>encountering complication</i>						
<i>Total number of Arthroplasties</i>	2352	604	669	1,767	24	5,416
<i>Percentage (%) proportion with complication</i>	0.43	11.26	6.88	9.22	0.00	5.30

**Table 10: Proportion of patients in each group with subluxation.**



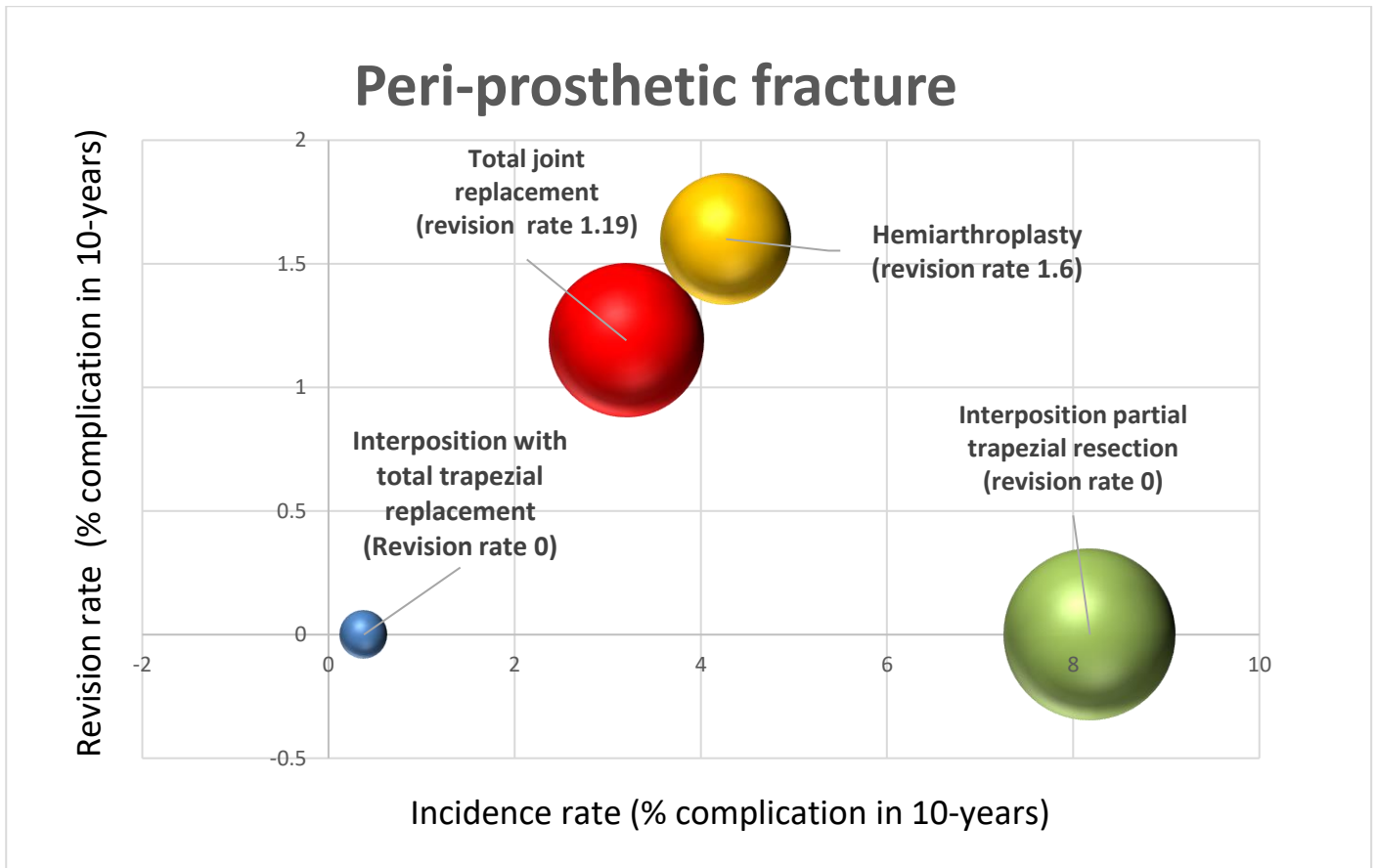
**Figure 46:** The bubble graph represents the rates of subluxation in the implant groups. The x-axis details how commonly the complication was encountered. The y-axis details how commonly the complication resulted in an implant revision. The size of the spheres relates to the proportion of patients in each group encountering the complication.

### *Periprosthetic fracture*

Peri-prosthetic fractures occurred most frequently in the interposition with partial trapezial resection group however none of the cases proceeded to a revision procedure. 37% and 29% of cases with periprosthetic fracture proceeded to revision in the TJR and hemiarthroplasty groups respectively.

<b>Peri-prosthetic fracture</b>	<i>Total Joint Replacement</i>	<i>Hemiarthroplasty</i>	<i>Interposition: Partial trapezial resection</i>	<i>Interposition: Total Trapezial replacement</i>	<i>Interposition: No trapezial resection</i>	<i>Total</i>
<i>Number</i>	43	8	15	3	0	69
<i>encountering complication</i>						
<i>Total number of Arthroplasties</i>	2352	604	669	1,767	24	5,416
<i>Percentage (%) proportion with complication</i>	1.83	1.32	2.24	0.17	0.00	1.27

**Table 11: Proportion of patients in each group with peri-prosthetic fracture.**



**Figure 47:** The bubble graph represents the rates of peri-prosthetic fracture in the implant groups. The x-axis details how commonly the complication was encountered. The y-axis details how commonly the complication resulted in an implant revision. The size of the spheres relates to the proportion of patients in each group encountering the complication.

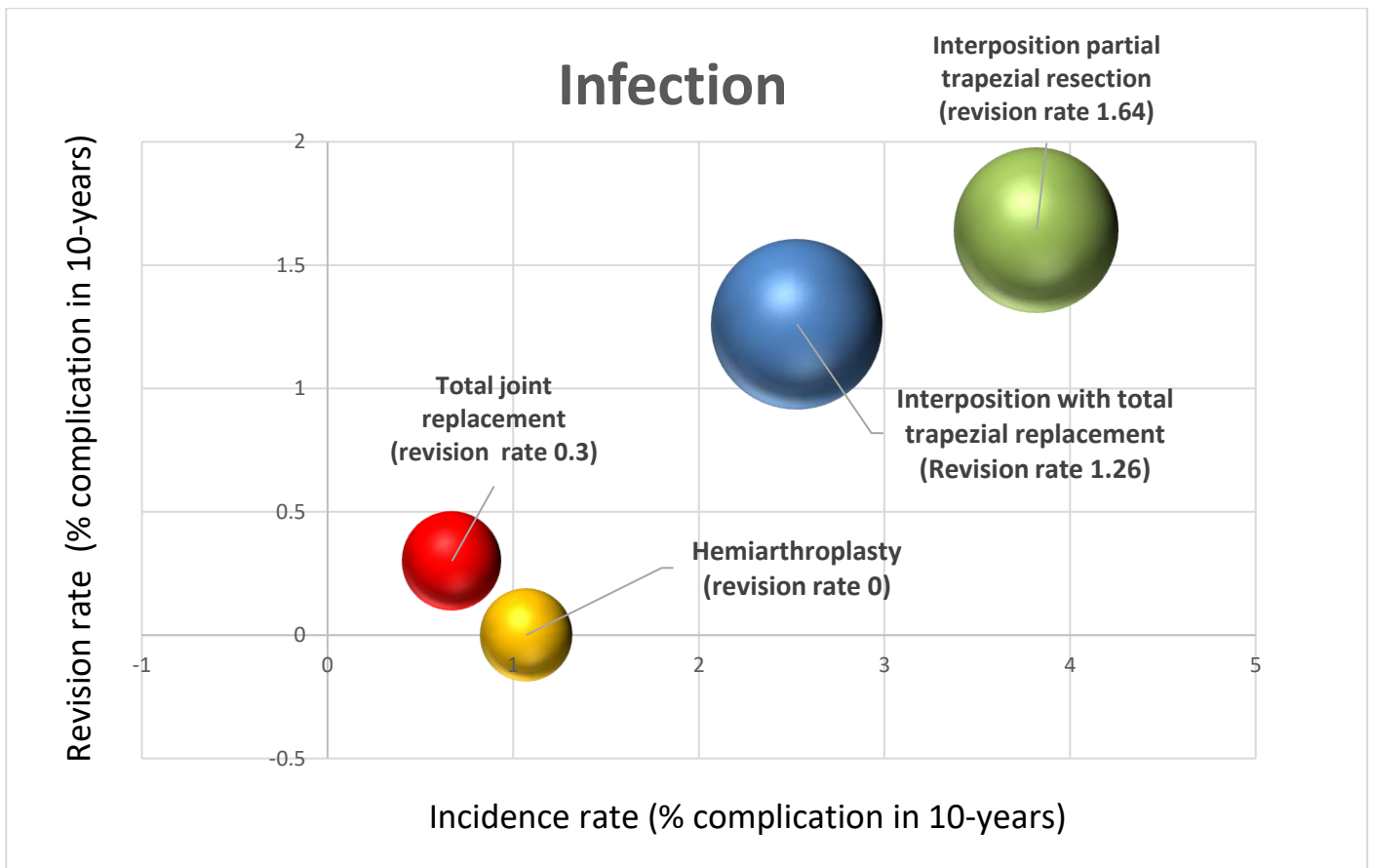
### *Infection*

Overall, the rate of revision due to an infection was low, 0.69% in 10-years. When encountered, it was a severe complication, as 45% (17 out of 38 cases) of implants required a revision if an infection was implicated.



<b>Infection</b>	<i>Total Joint Replacement</i>	<i>Hemiarthroplasty</i>	<i>Interposition: Partial trapezial resection</i>	<i>Interposition: Total Trapezial replacement</i>	<i>Interposition: No trapezial resection</i>	<i>Total</i>
<i>Number</i>	9	2	7	20	0	38
<i>encountering complication</i>						
<i>Total number of Arthroplasties</i>	2352	604	669	1,767	24	5,416
<i>Percentage (%) proportion with complication</i>	0.38	0.33	1.05	1.13	0.00	0.70

**Table 12: Proportion of patients in each group with infection.**



**Figure 48:** The bubble graph represents the rates of infection in the implant groups. The x-axis details how commonly the complication was encountered. The y-axis details how commonly the complication resulted in an implant revision. The size of the spheres relates to the proportion of patients in each group encountering the complication.

*Osteolysis, implant subsidence, peri-prosthetic ossification, radiological loosening, and implant resorption/wear*

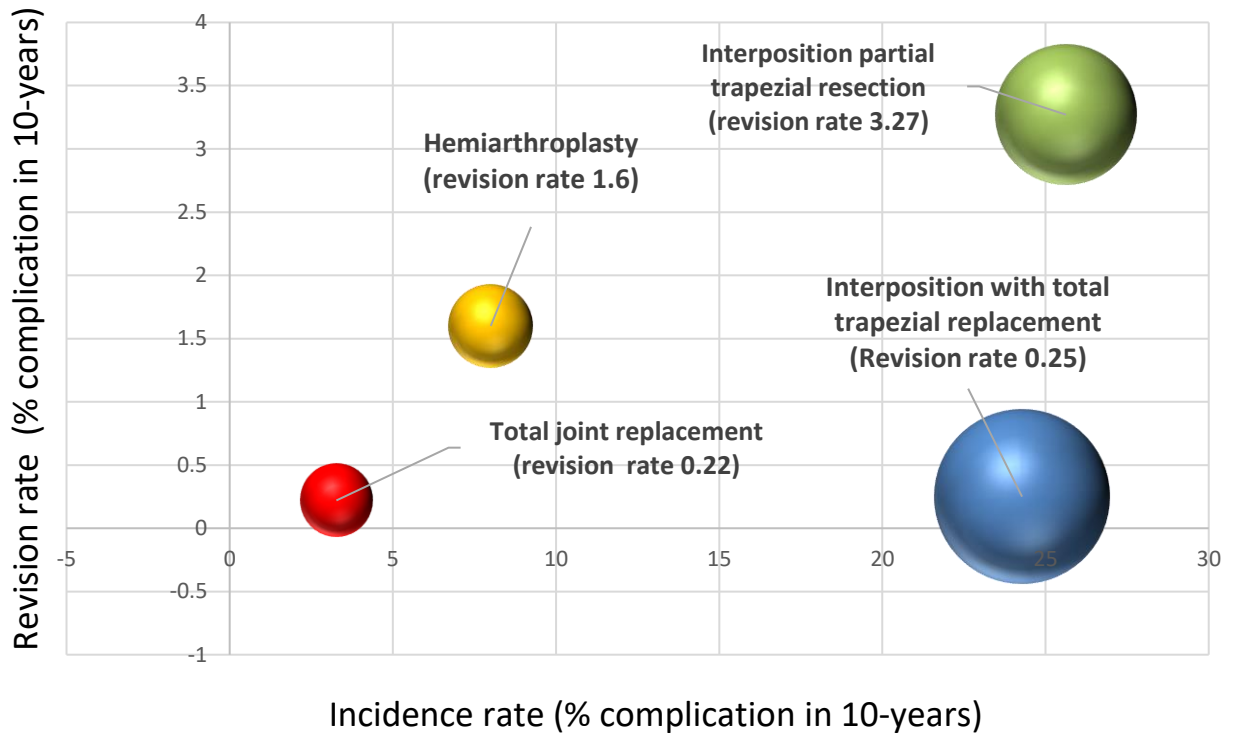
The complications of radiological loosening, implant resorption and wear, periprosthetic ossification, osteolysis and implant subsidence all share the commonality of being largely radiological findings which does not or only rarely leads to implant revision. Osteolysis was largely encountered in the interposition with total (192 cases) and partial (47 cases) trapezium resection groups. 14 cases of the reported 298 cases (4.7%) proceeded to revision. Implant subsidence was most commonly encountered in the interposition with partial trapezium resection group. 11 cases of the reported 142 cases (7.75%) proceeded to revision. Peri-prosthetic ossification was a complication exclusive to

total joint replacements, 92 cases were encountered of which 2 were revised. Radiological loosening was a common finding in TJR, hemiarthroplasty and interposition with total trapezium replacement groups. None of the encountered 305 cases were revised due to the presence of periprosthetic lucency. Implant resorption and wear was a rarely encountered complication in the TJR, hemiarthroplasty and interposition with total trapezium replacement groups, none of the reported 40 cases were revised due to this complication.

<b>Osteolysis</b>	<i>Total Joint Replacement</i>	<i>Hemiarthroplasty</i>	<i>Interposition: Partial trapezium resection</i>	<i>Interposition: Total Trapezium replacement</i>	<i>Interposition: No trapezium resection</i>	<i>Total</i>
<i>Number encountering complication</i>	44	15	47	192	0	298
<i>Total number of Arthroplasties</i>	2352	604	669	1,767	24	5,416
<i>Percentage (%) proportion with complication</i>	1.87	2.48	7.03	10.87	0.00	5.5

**Table 13: Proportion of patients in each group with osteolysis.**

# Osteolysis

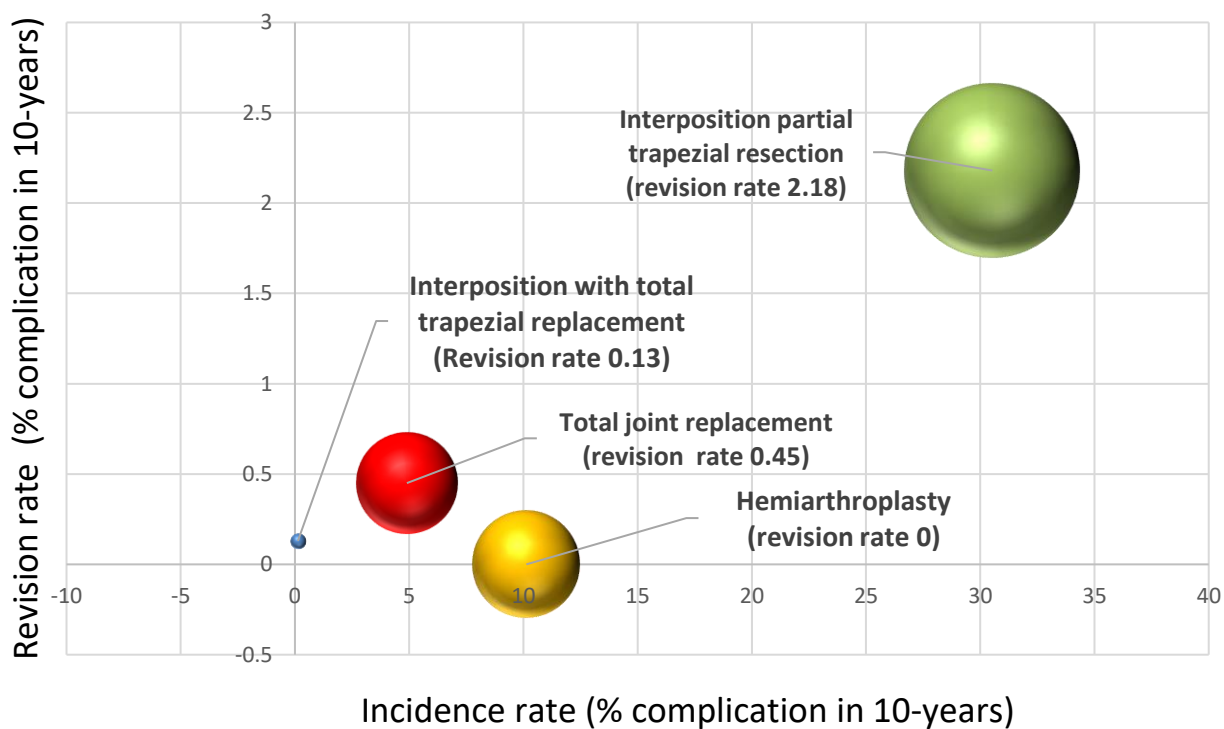


**Figure 49:** The bubble graph represents the rates of osteolysis in the implant groups. The x-axis details how commonly the complication was encountered. The y-axis details how commonly the complication resulted in an implant revision. The size of the spheres relates to the proportion of patients in each group encountering the complication.

<b>Implant subsidence</b>	<i>Total Joint Replacement</i>	<i>Hemiarthroplasty</i>	<i>Interposition: Partial trapezial resection</i>	<i>Interposition: Total Trapezial replacement</i>	<i>Interposition: No trapezial resection</i>	<i>Total</i>
<i>Number</i>	66	19	56	1	0	142
<i>encountering complication</i>						
<i>Total number of Arthroplasties</i>	2352	604	669	1,767	24	5,416
<i>Percentage (%) proportion with complication</i>	2.81	3.15	8.37	0.06	0.00	2.62

**Table 14: Proportion of patients in each group with implant subsidence**

## Implant subsidence

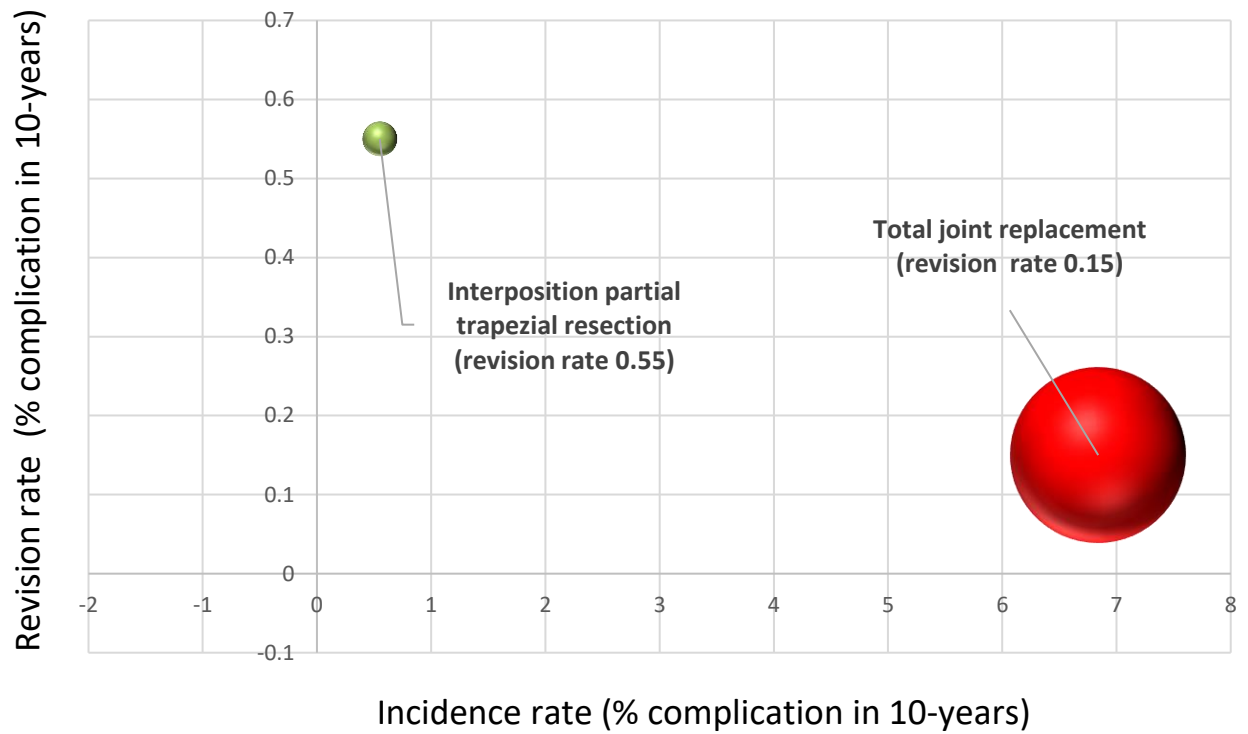


**Figure 50:** The bubble graph represents the rates of implant subsidence in the implant groups. The x-axis details how commonly the complication was encountered. The y-axis details how commonly the complication resulted in an implant revision. The size of the spheres relates to the proportion of patients in each group encountering the complication.

<b>Peri-prosthetic ossification</b>	<i>Total Joint Replacement</i>	<i>Hemiarthroplasty</i>	<i>Interposition: Partial trapezial resection</i>	<i>Interposition: Total Trapezial replacement</i>	<i>Interposition: No trapezial resection</i>	<i>Total</i>
<i>Number</i>	92	0	1	0	0	93
<i>encountering complication</i>						
<i>Total number of Arthroplasties</i>	2352	604	669	1,767	24	5,416
<i>Percentage (%) proportion with complication</i>	3.91	0.00	0.15	0.00	0.00	1.72

**Table 15: Proportion of patients in each group with implant peri-prosthetic ossification**

## Peri-prosthetic ossification

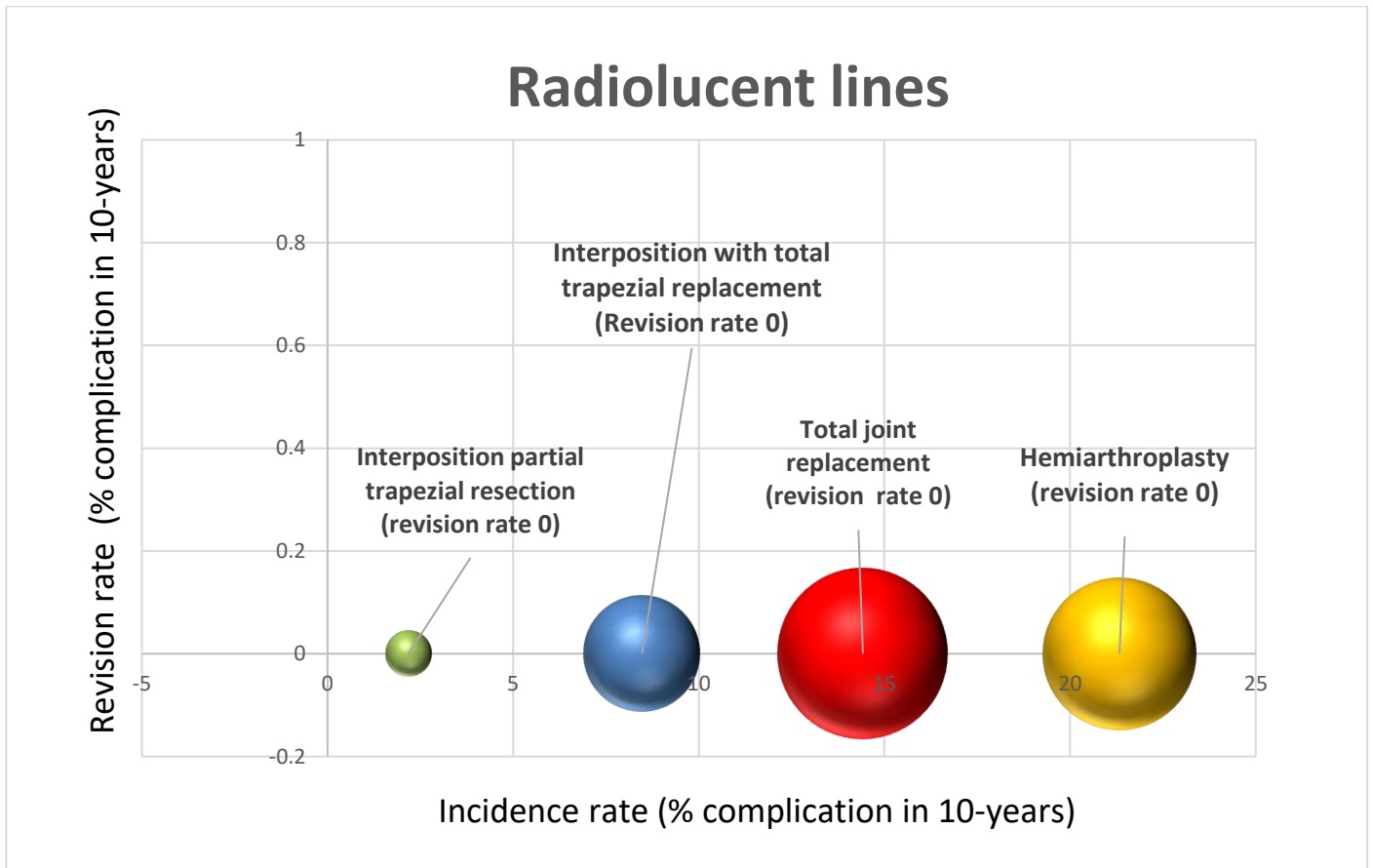


**Figure 51:** The bubble graph represents the rates of periprosthetic ossification in the implant groups. The x-axis details how commonly the complication was encountered. The y-axis details how commonly the complication resulted in an implant revision. The size of the spheres relates to the proportion of patients in each group encountering the complication.



<b>Radiolucent lines</b>	<i>Total Joint Replacement</i>	<i>Hemiarthroplasty</i>	<i>Interposition: Partial trapezial resection</i>	<i>Interposition: Total Trapezial replacement</i>	<i>Interposition: No trapezial resection</i>	<i>Total</i>
<i>Number</i>	194	40	4	67	0	305
<i>encountering complication</i>						
<i>Total number of Arthroplasties</i>	2352	604	669	1,767	24	5,416
<i>Percentage (%) proportion with complication</i>	8.25	6.62	0.60	3.79	0.00	5.63

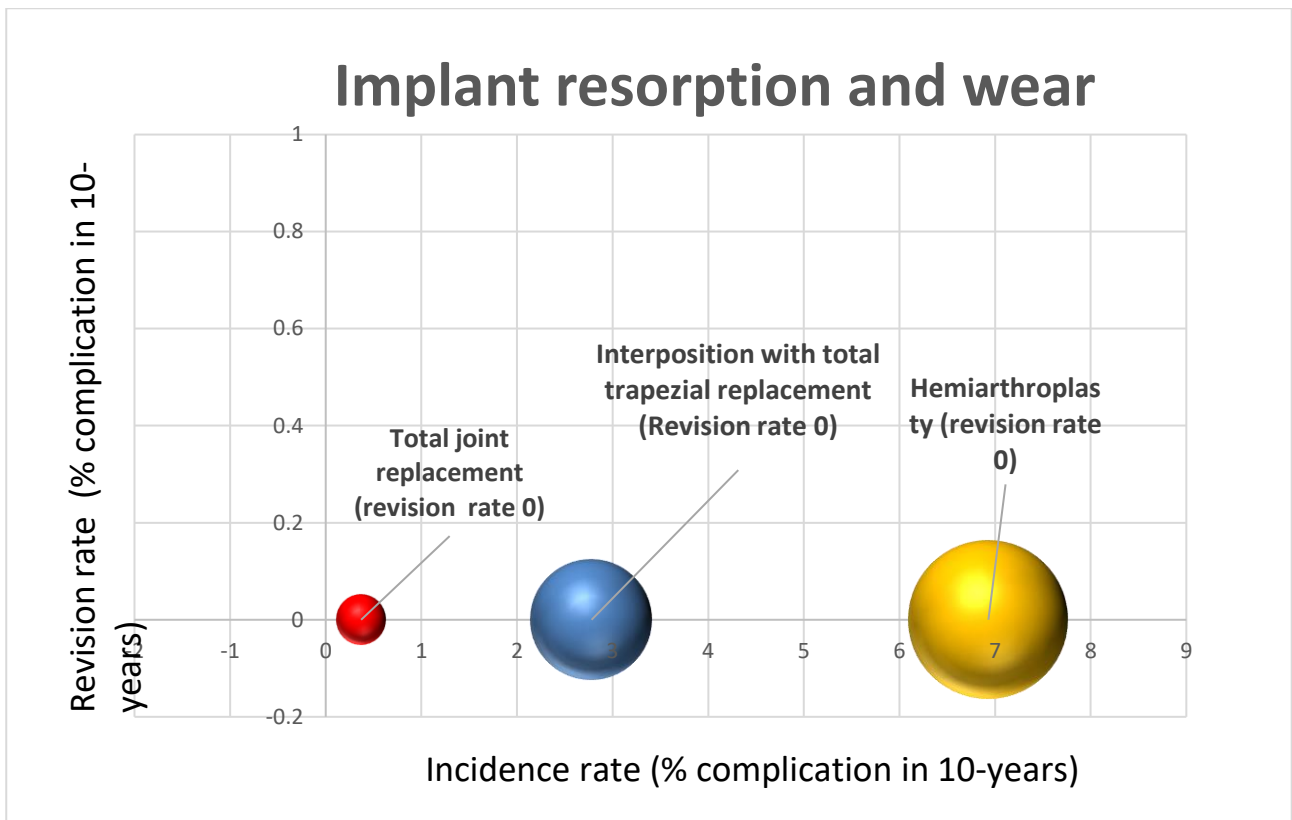
**Table 16: Proportion of patients in each group with radiolucent lines**



**Figure 52: The bubble graph represents the rates of radiolucent lines in the implant groups. The x-axis details how commonly the complication was encountered. The y-axis details how commonly the complication resulted in an implant revision. The size of the spheres relates to the proportion of patients in each group encountering the complication.**

<b>Implant resorption and wear</b>	<i>Total Joint Replacement</i>	<i>Hemiarthroplasty</i>	<i>Interposition: Partial trapezial resection</i>	<i>Interposition: Total Trapezial replacement</i>	<i>Interposition: No trapezial resection</i>	<i>Total</i>
<i>Number</i>	5	13	0	22	0	40
<i>encountering complication</i>						
<i>Total number of Arthroplasties</i>	2352	604	669	1,767	24	5,416
<i>Percentage (%) proportion with complication</i>	0.21	2.15	0.00	1.25	0.00	0.74

**Table 17: Proportion of patients in each group with implant resorption and wear**



**Figure 53:** The bubble graph represents the rates of implant resorption and wear in the implant groups. The x-axis details how commonly the complication was encountered. The y-axis details how commonly the complication resulted in an implant revision. The size of the spheres relates to the proportion of patients in each group encountering the complication.

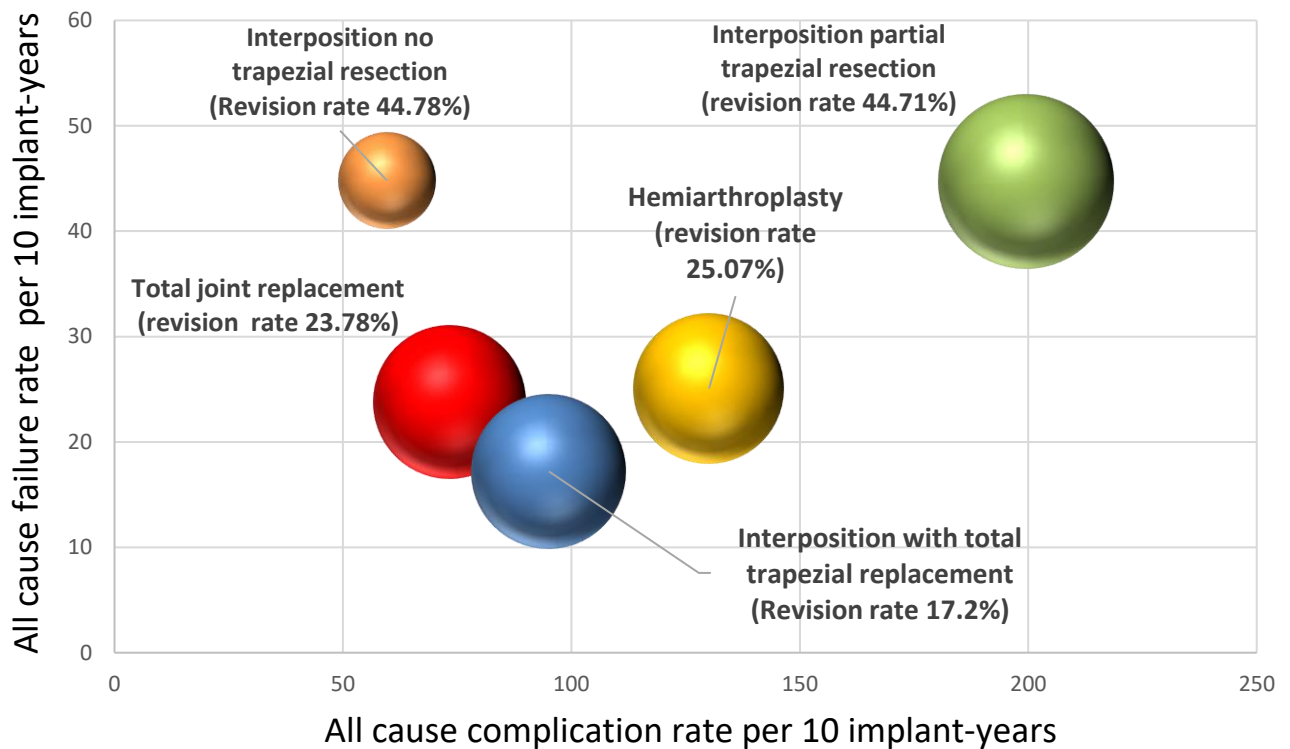
*All cause implant complication and failure rates*

The group of implants with the lowest overall rate of failure was the interposition with total trapezial replacement group, at 17 % per 10 implant years. The interposition with partial trapezial resection and interposition with no trapezial resection groups had the highest rates of failure at 45% per 10 implant years. The total joint replacement and hemiarthroplasty groups had similar rates of failure, at 24% and 25% per 10 Implant-years respectively

<b>All cause complications</b>	<i>Total Joint Replacement</i>	<i>Hemiarthroplasty</i>	<i>Interposition: Partial trapezial resection</i>	<i>Interposition: Total Trapezial replacement</i>	<i>Interposition: No trapezial resection</i>	<i>Total</i>
<i>Number</i>	987	244	366	752	4	2353
<i>encountering a complication</i>						
<i>Total number of Arthroplasties</i>	2352	604	669	1,767	24	5,416
<i>Percentage (%) proportion with complications</i>	41.96	40.40	54.71	42.56	16.67	43.45

**Table 18: Proportion of patients in each group with all cause complications**

## All cause complication and failure rates

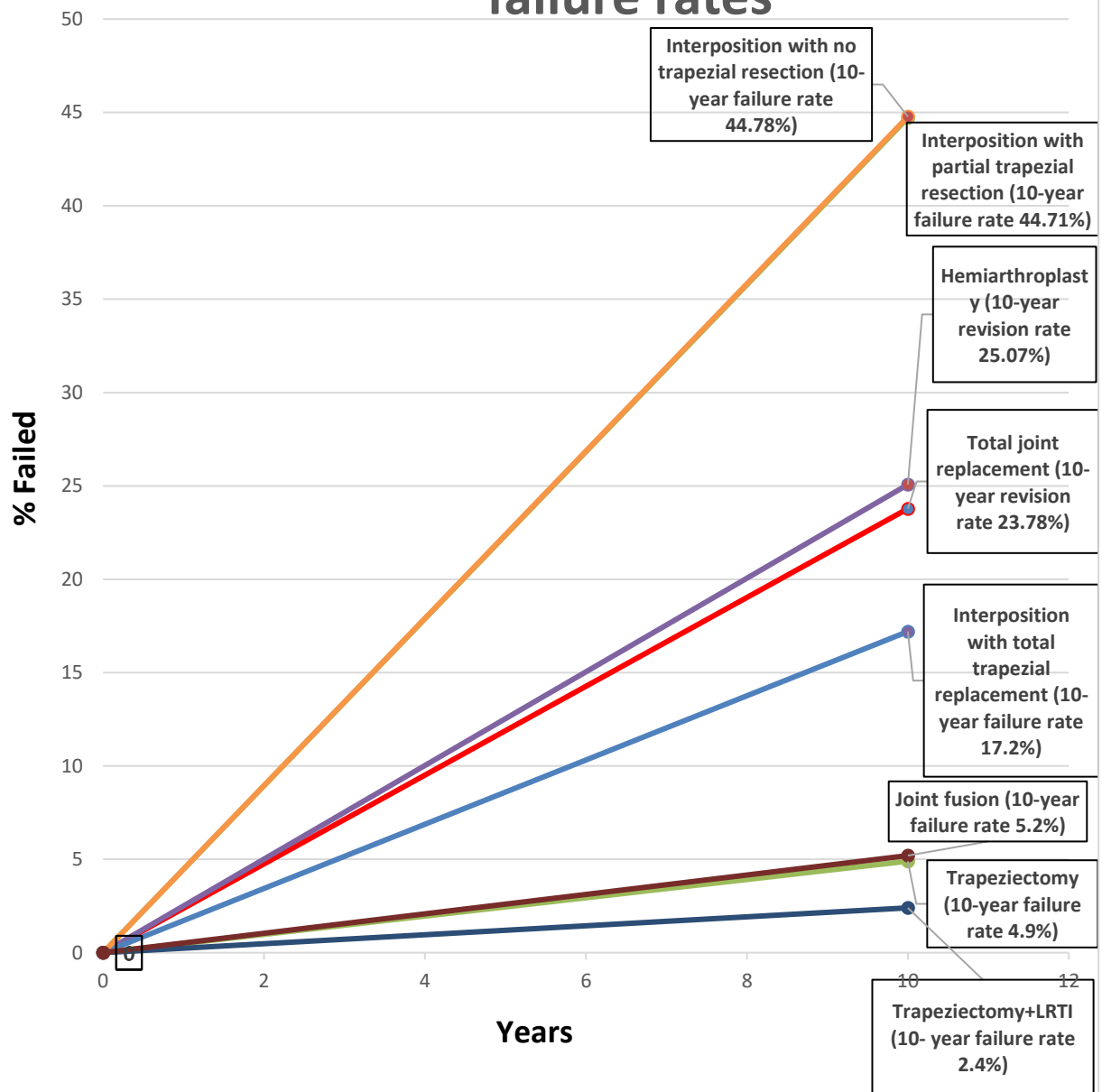


**Figure 54:** The bubble graph represents the rates of all cause implant failure in the implant groups. The x-axis details how commonly a complication was likely to be encountered. The hemiarthroplasty group and interposition with partial trapezial resection group have all cause complications >100% at 10 years. This result can be interpreted as 100% of implants will encounter a complication before 10 years. The y-axis details all cause failure in 10 years. The size of the spheres relates to the proportion of patients in each group encountering a complication.

### *Comparing failure rates of implant and non-implant arthroplasty*

The rates of failure of non-implant arthroplasty was compared to the implant arthroplasty groups. All non-implant arthroplasty groups (Trapeziectomy, trapeziectomy with ligament reconstruction +/- tendon interposition and joint fusion) all had overall lower rates of failure than the implant groups.

## Implant vs Non-implant arthroplasty failure rates

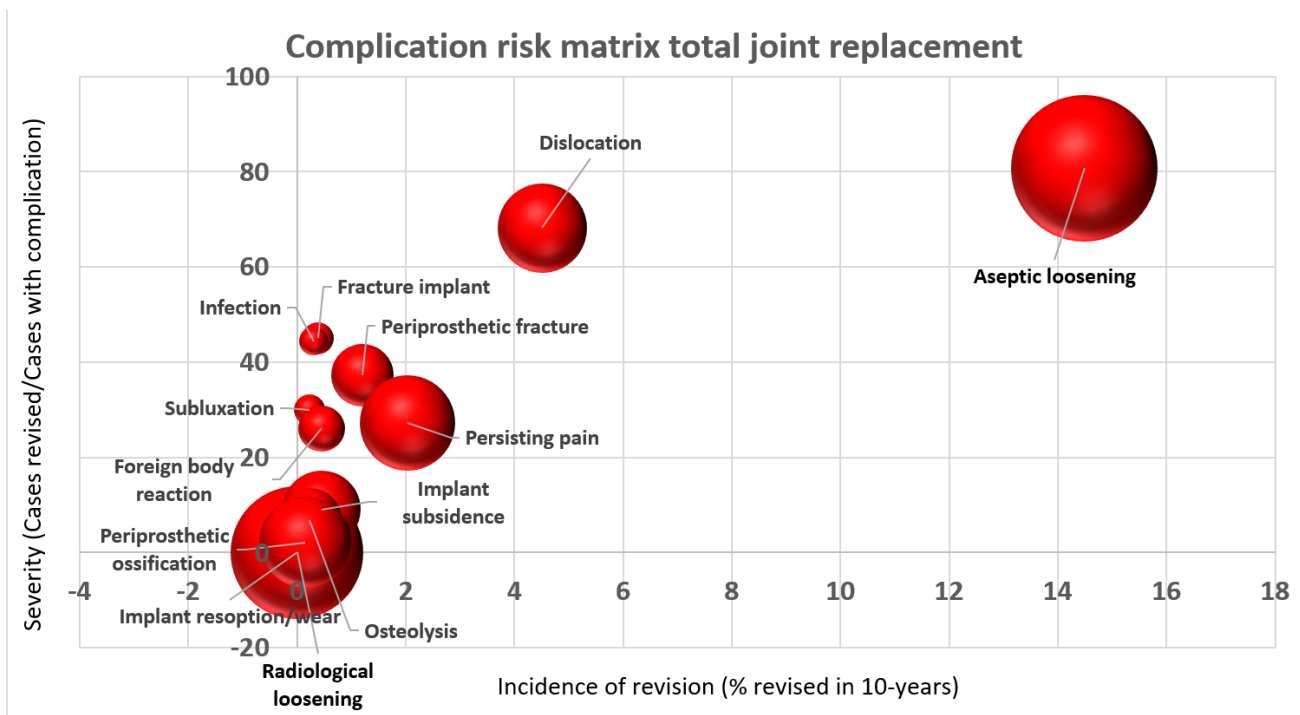


**Figure 55:** The line graph represents rates of failure in the implant and non-implant arthroplasty groups. All non-implant arthroplasty groups carried lower failure rates than the implant arthroplasty groups

### Complication risk matrixes by design group

The bubble graphs below present the same data as above, re-organised by implant design group. Data presented as a risk matrix allows clear visualisation of the complications which each design group is particularly susceptible to (Figures 56-60).

**Figures 56-60.** The bubble graph shows the complication matrix for each class of implants. The x-axis represents the 10-year revision rate of each complication. The Y-axis relates to the % of cases which progressed to implant revision if the complication was encountered. The size of the spheres represents the proportion of patients encountering each complication. i.e. the larger the sphere the more common it was.



**Figure 56.**



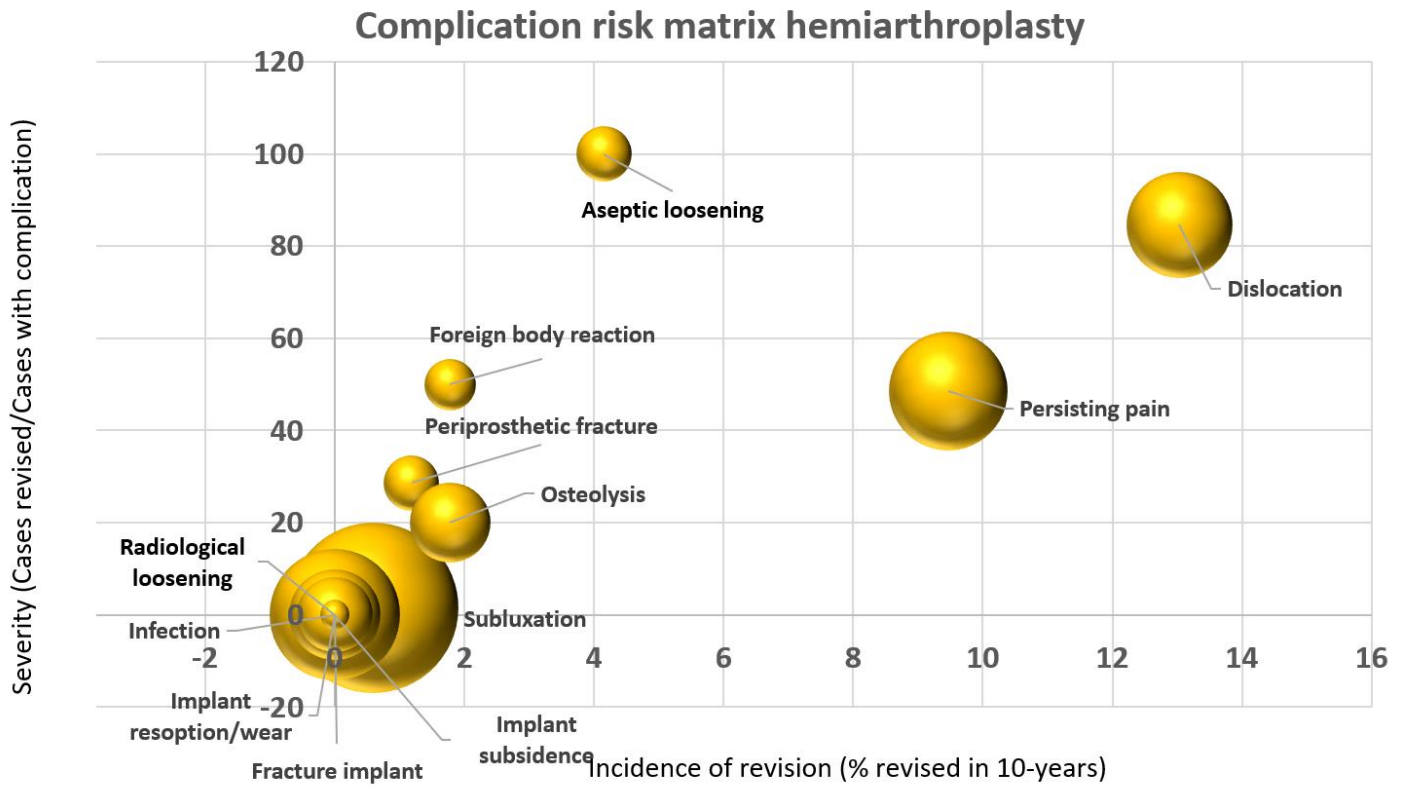


Figure 57.

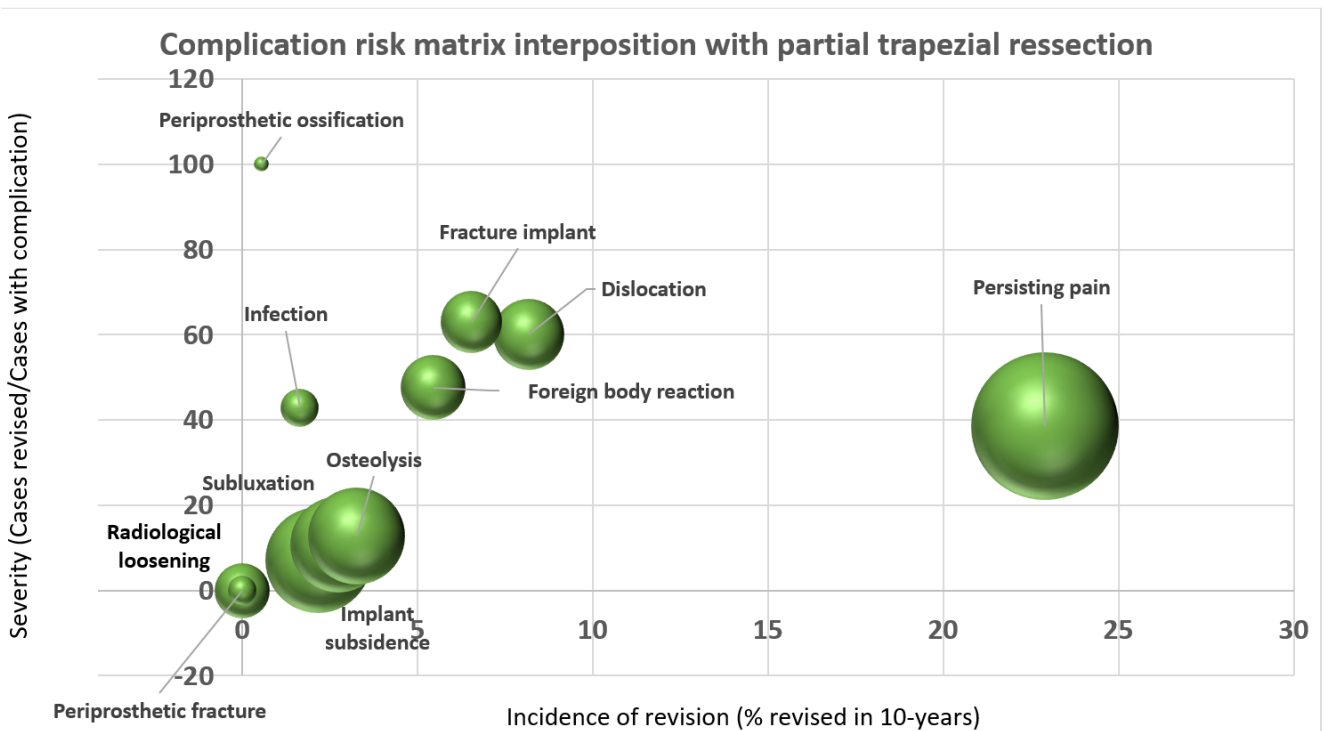


Figure 58.

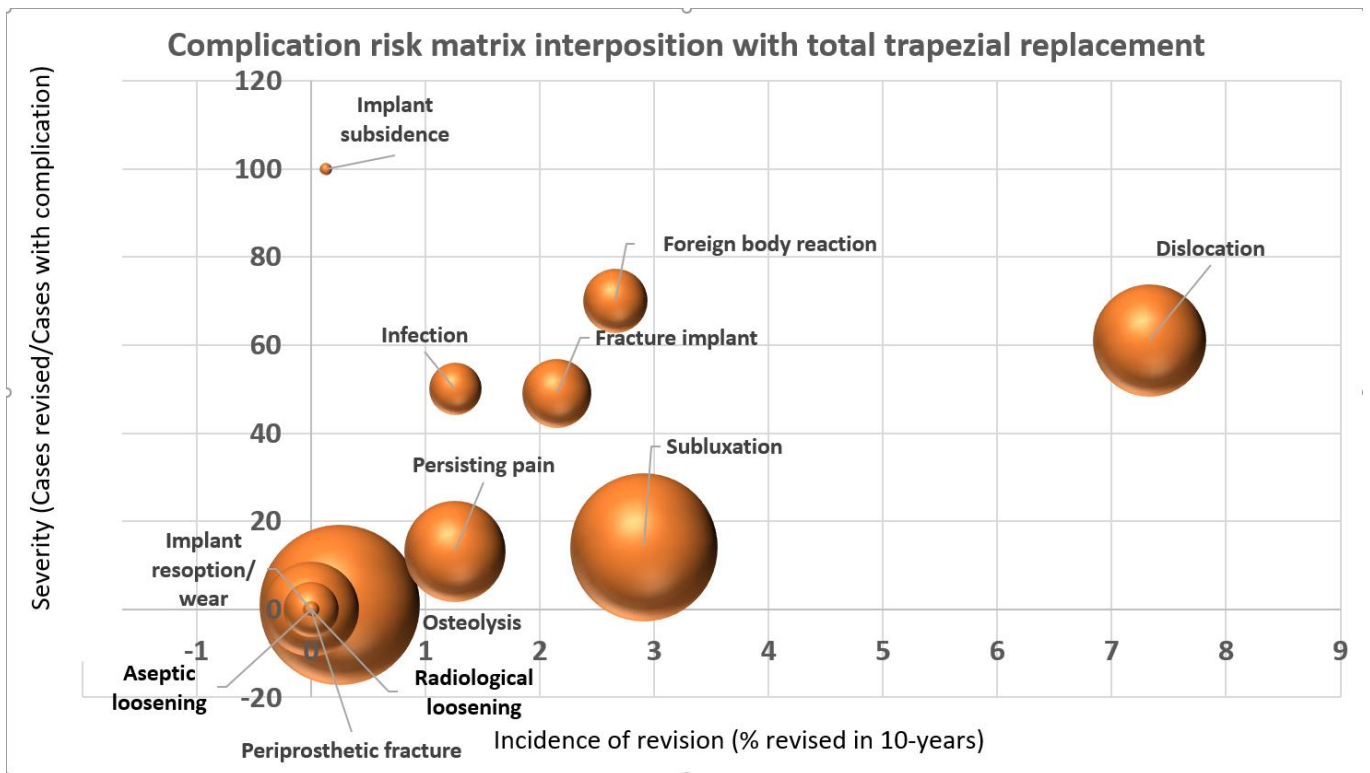


Figure 59.

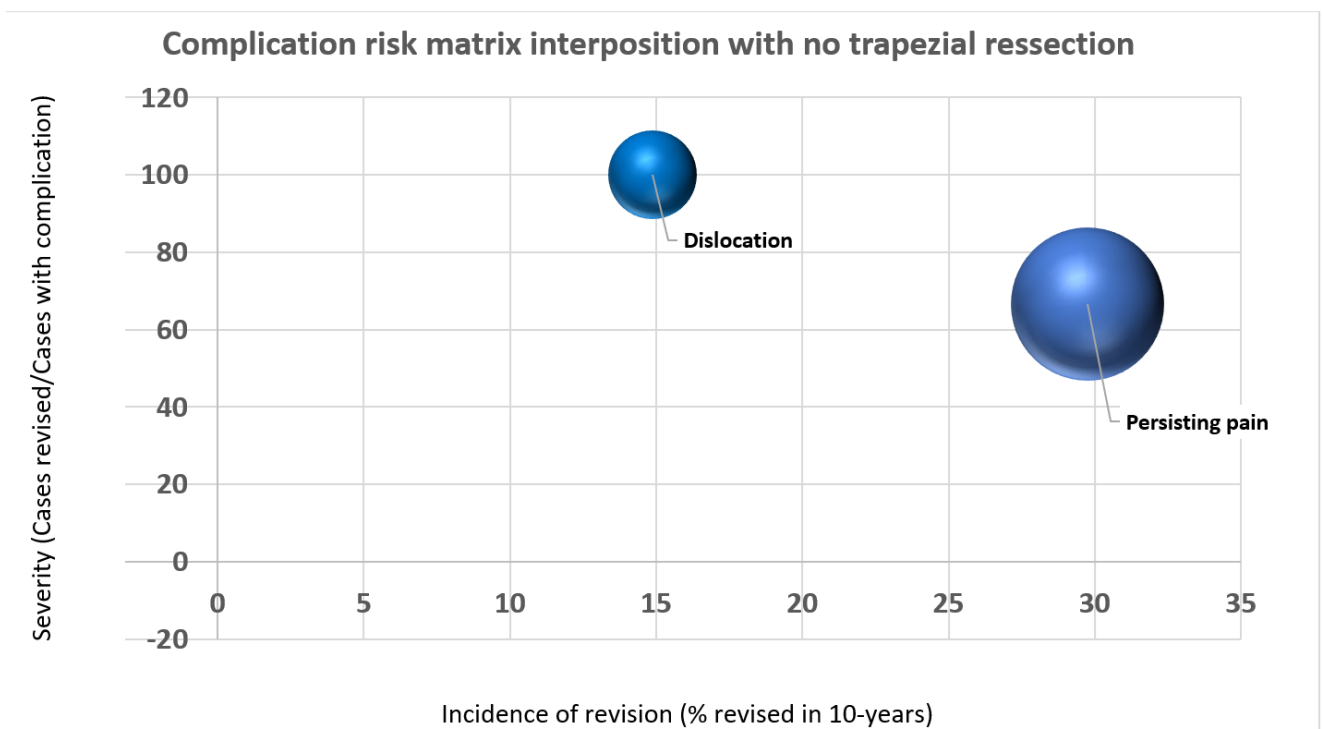


Figure 60.

Identification of implants with higher than expected failure rates and unfavourable morphology

Total joint replacement

The total joint replacement group had a combined failure rate of 2.4 per 100-implant years. Five total joint replacement implants had a failure rate greater than twice that of the group (> 4.8 per 100 implant years). These implants (Ledoux, Motec, Moje Acamo, Bichat, Elektra) were identified as having a higher than expected rate of failure which differed from other types of total joint replacements. (Figure 55).

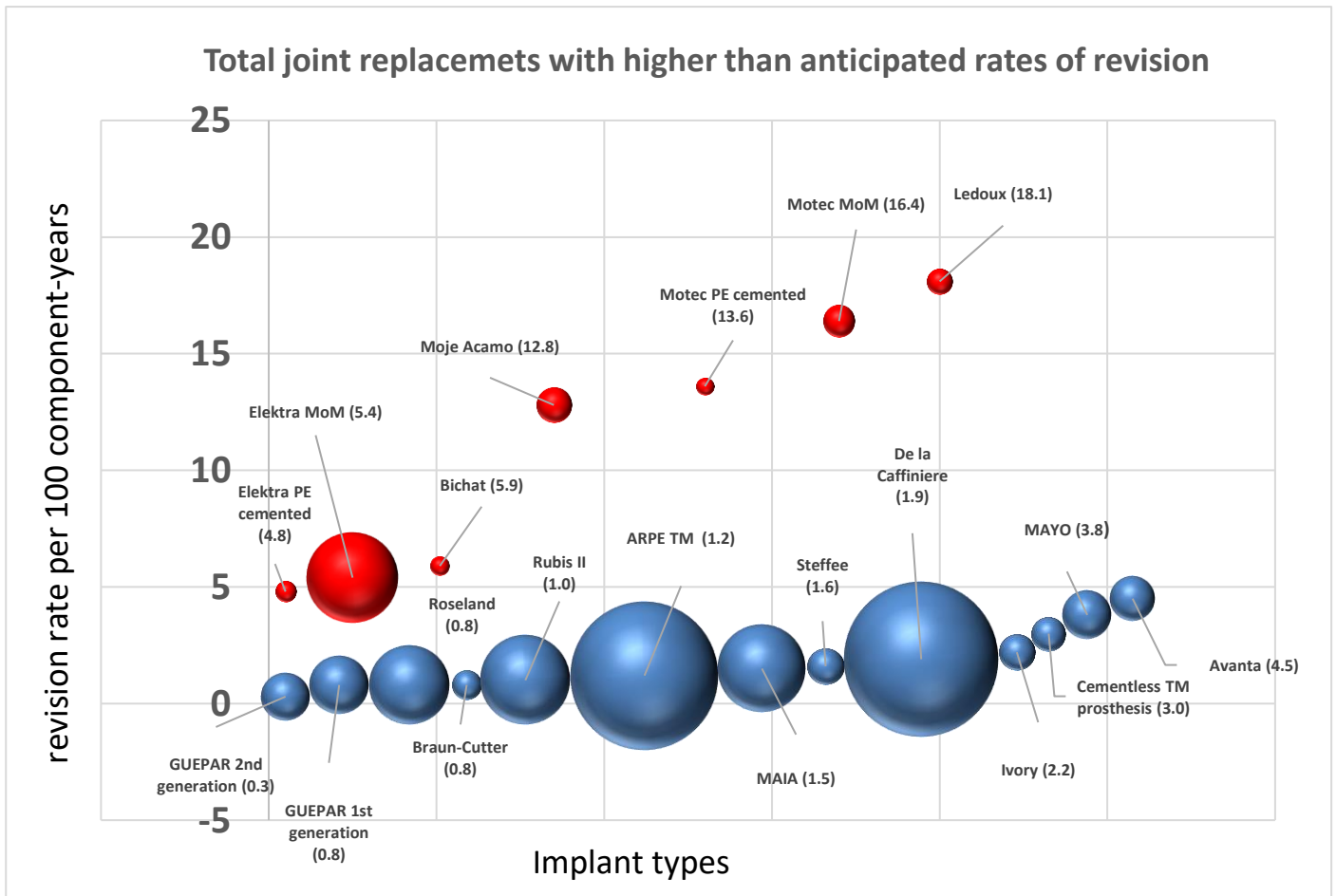
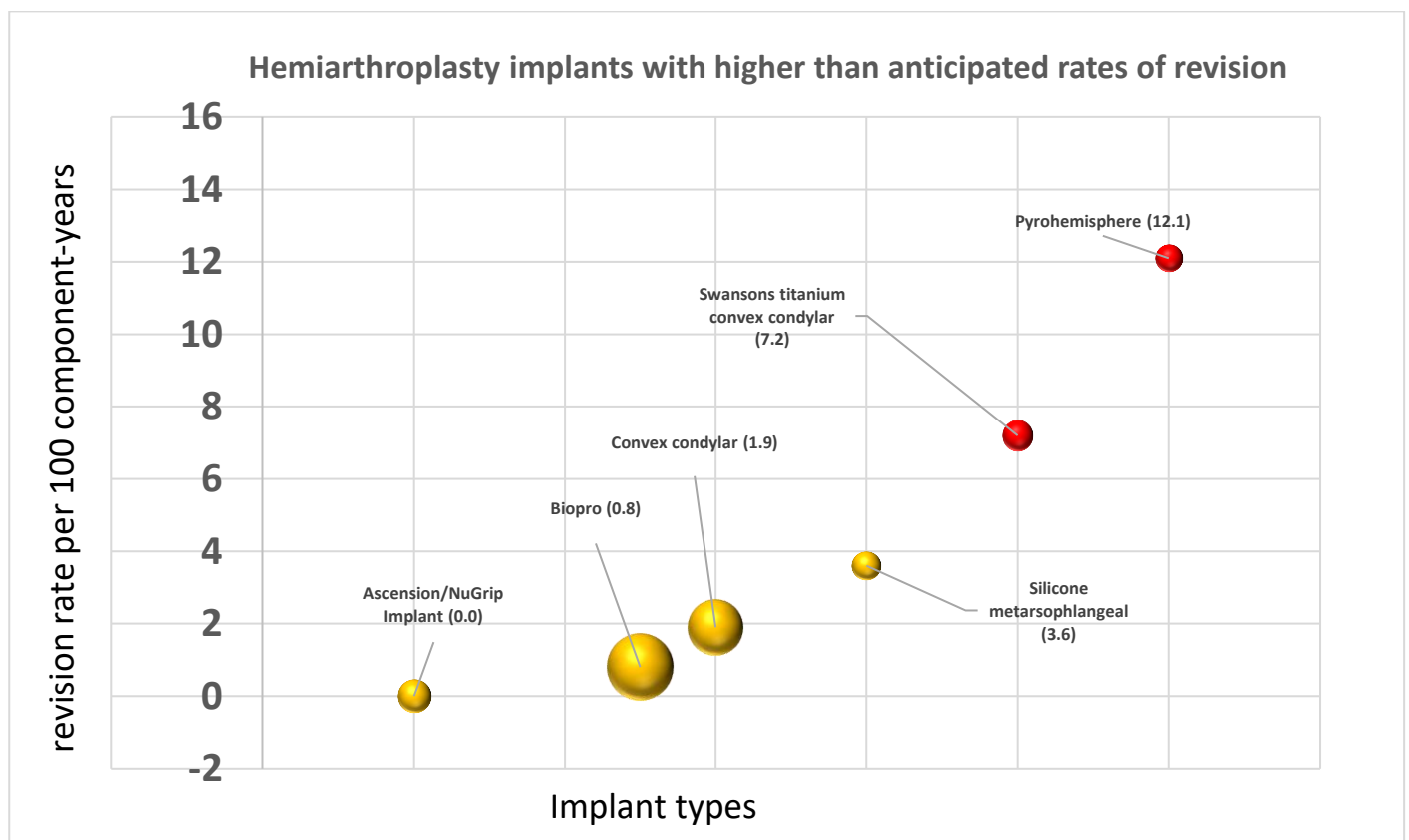


Figure 61: Implants highlighted in red have a higher than anticipated rate of failure. The size of the spheres corresponds to the number of implant-years for each implant. The Y axis is the failure rate per 100 component-years.

## Hemiarthroplasty

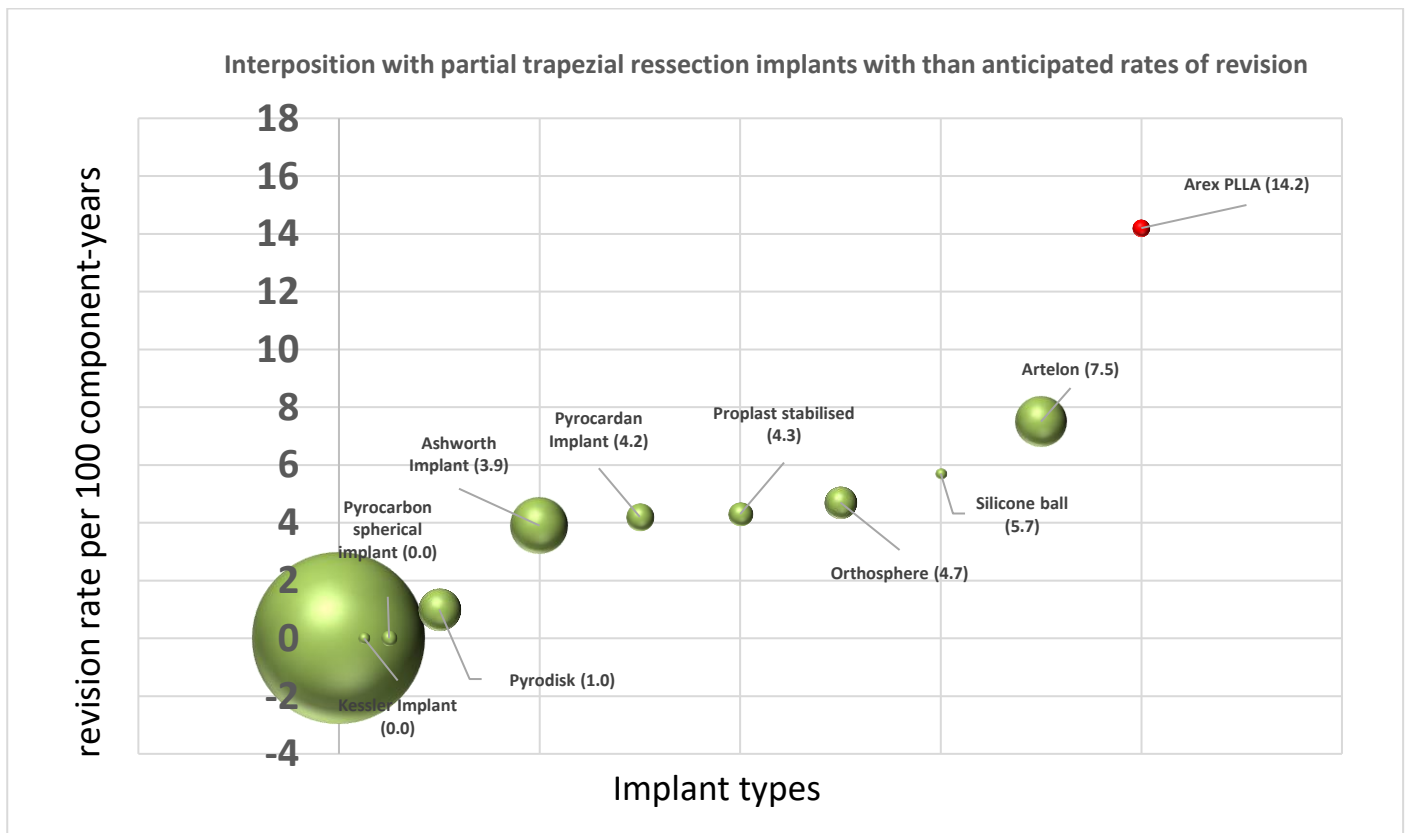
The hemiarthroplasty group had a combined failure rate of 2.5 per 100-implant years. Two hemiarthroplasty implants had a failure rate greater than twice that of the group (> 5.0 per 100 component years). These implants (The Pyrohemisphere and Swanson titanium convex condylar) were identified as having a higher than expected rate of failure which differed from other types of hemiarthroplasty. (Figure 57)



**Figure 62: Implants highlighted in red have a higher than anticipated rate of failure. The size of the spheres corresponds to the number of implant-years for each implant. The Y axis is the failure rate per 100 component-years.**

## Interposition with partial trapezial resection

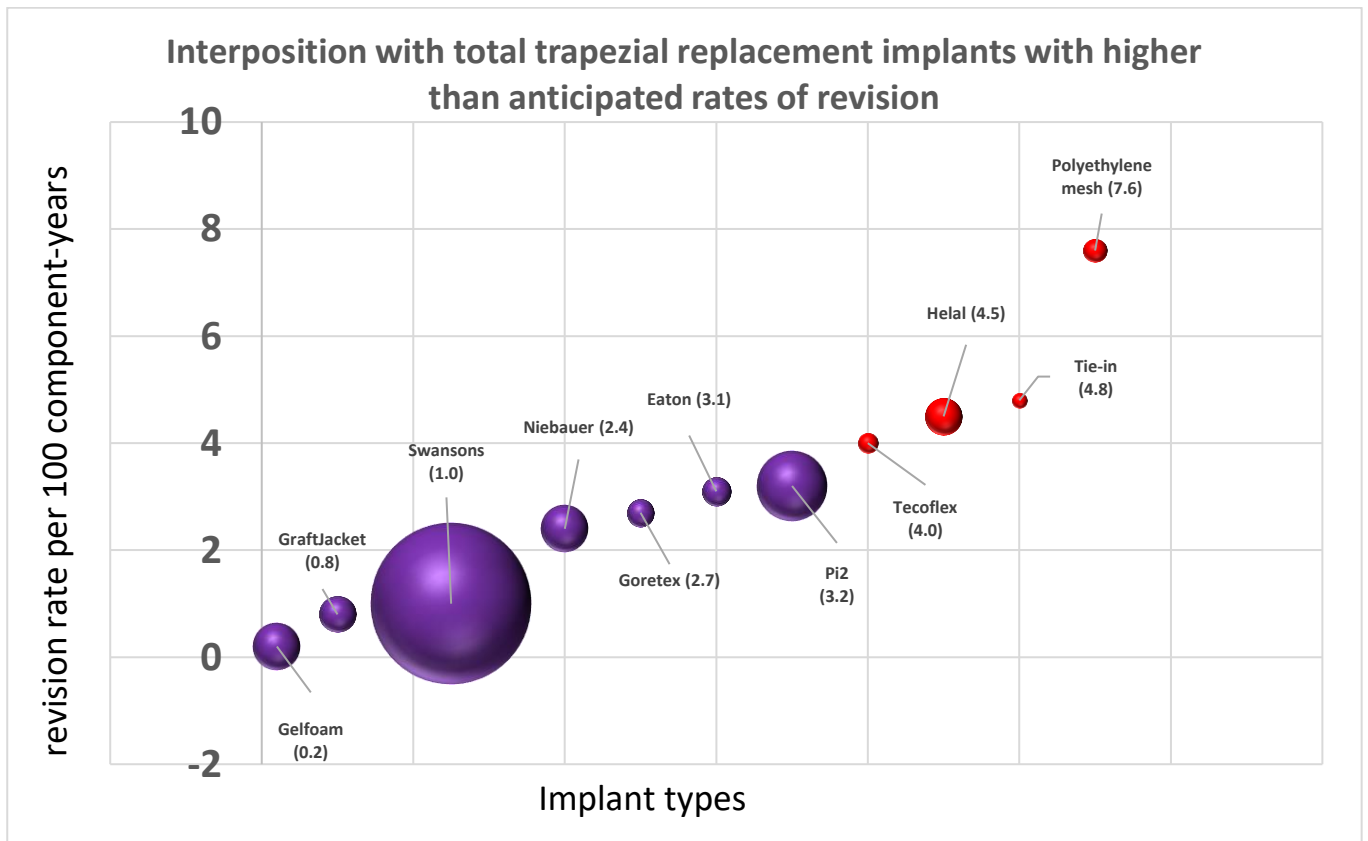
The interposition with partial trapezial resection group had a combined failure rate of 4.5 per 100 implant-years. One implant in the interposition with partial trapezial resection group had a failure rate greater than twice that of the group (> 9.0 per 100 component years). The Arex PLLA implant was identified as having a higher than expected rate of failure which differed from the other implants in the interposition with partial trapezial resection group. (Figure 58)



**Figure 63: Implants highlighted in red have a higher than anticipated rate of failure. The size of the spheres corresponds to the number of implant-years for each implant. The Y axis is the failure rate per 100 component-years.**

## Interposition with total trapezial resection

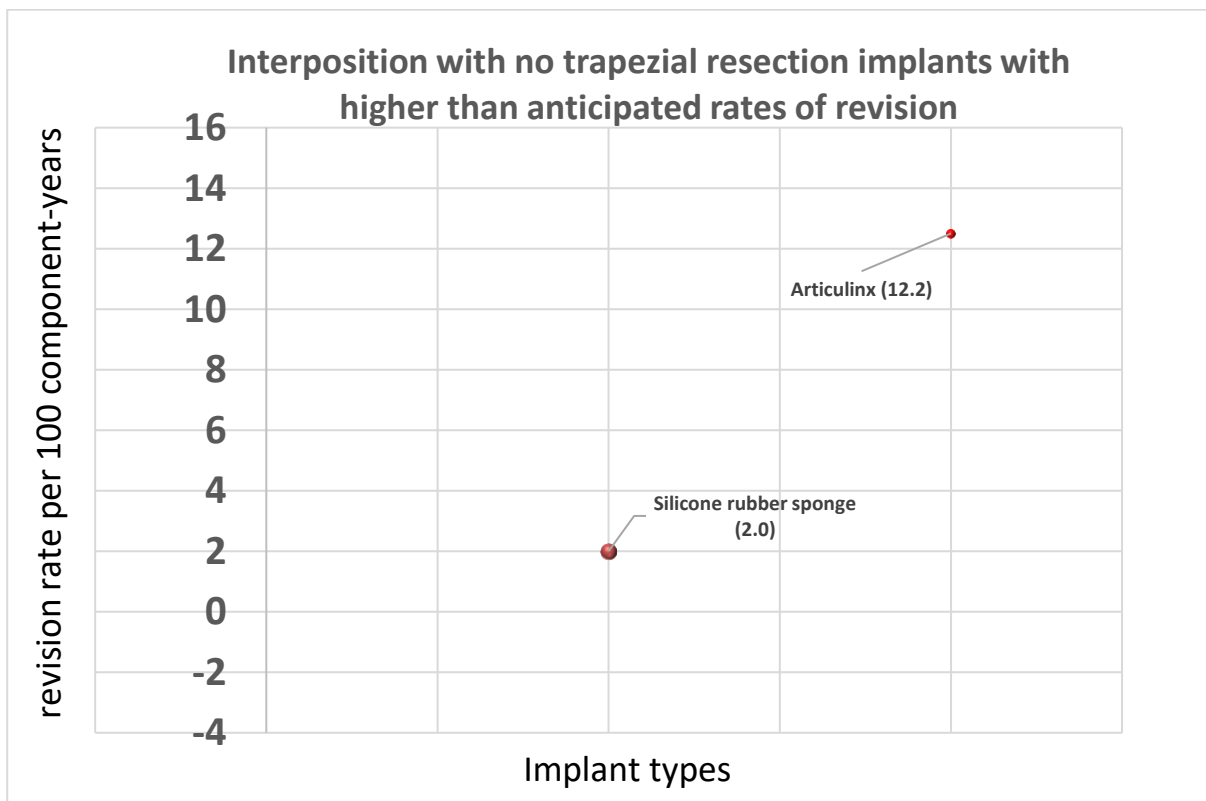
Four implants in the interposition with total trapezial replacement group had a failure rate greater than twice that of the group (>3.4 per 100 component years). These implants (Polyethylene mesh, Halal prosthesis, Tie-in implant, and Tecoflex implant) were identified as having a higher than expected rate of failure which differed from other types of implants in the interposition with total trapezial resection group. (Figure 59)



**Figure 64: Implants highlighted in red have a higher than anticipated rate of failure. The size of the spheres corresponds to the number of implant-years for each implant. The Y axis is the failure rate per 100 component-years.**

## Interposition with no trapezial resection

One implant in the interposition with no trapezial resection group had a failure rate greater than twice that of the group (> 9.0 per 100 component years). The Articulinx implant was identified as having a higher than expected rate of failure which differed from the other implant in the interposition with no trapezial resection group. (Figure 60)



**Figure 65: Implants highlighted in red have a higher than anticipated rate of failure. The size of the spheres corresponds to the number of implant-years for each implant. The Y axis is the failure rate per 100 component-years.**

## Discussion

This systematic review focuses on complications and revision arising from basal thumb implant surgery and identifies implant and implant groups which have low complication and failure rates which have favourable design features. Directly comparing all available implants to identify the implants with good outcomes is a difficult task due to the heterogeneity of implants available and lack of high-quality evidence. The majority of evidence available was level IV, retrospective case series. 95% (119/125) of studies included in this review were retrospective observational studies (Level III-IV). Although high level evidence (Level I: randomised controlled trials or Level II: well conducted cohort studies) are required to show convincing benefit of one procedure over another, poorly performing implants or techniques can be convincingly identified and avoided even with low level evidence (159).

The following paragraphs will discuss in detail the thirteen common implant related complications, identify the causes, and implant design features leading to each complication.

### Aseptic Loosening

Aseptic loosening was largely encountered in the TJR and the hemiarthroplasty group, and was the most common cause of implant failure in TJR. The 10-year revision rate due to aseptic loosening for the TJR was 14% compared to the hemiarthroplasty group which was 4.15% (Figure 41). A higher rate of loosening in a TJR design may be due to the presence of two components (trapezial and metacarpal) being susceptible to loosening. The most common reasons for aseptic loosening were surgical technique, incorrect implant positioning, poor bone quality of the trapezium, and the design of the implant. An example of surgical technique causing aseptic loosening was the trapezial treading technique, performed before inserting the Elektra prosthesis. Rates of aseptic loosening for this particular implant improved once this technique was abandoned (133). Implant positioning is technically demanding as the trapezial space is limited, and the bone and joint surfaces



are small. These factors all contribute to technical difficulty and correct implant positioning (128). In addition, the bone quality of the trapezium is often poor, as many patients are post-menopausal women with osteoporosis, and once the dense cortical bone joint surface is resected, weak cancellous bone remains. The porosity of cancellous bone provides less surface area for contact between the bone and implant and therefore a less secure bond (130, 138). An example of implant design causing aseptic loosening is having a metacarpal stem with a circular cross-section, as seen with the MOJE implant. This design may encourage rotational shift and contribute to loosening (124). An anatomical metacarpal stem is considered an improved design, such as the MAIA and second generation GAUPAR prosthesis (160, 161) . Other factors thought to contribute to this complication include patients with higher demand hands e.g. younger age and male gender (162), the implant material and its biocompatibility and lack of osteointegration (133, 134). The best method of fixation remains inconclusive as cemented as well as press-fit fixation were both susceptible to aseptic loosening.

## Dislocation

Implant dislocation was encountered across all design groups and carried an overall high proportion of revision if encountered (figure 42). The implant design group with the highest 10-year revision rate of dislocation was the interposition with no trapezial resection group: 15% 10-year revision. This may be due to lack of implant stability in an already narrowed space as no trapezial resection was undertaken. This group also, contained the smallest numbers and is therefore much more susceptible to bias, therefore the revision rate maybe over estimated. The most commonly reported direction of dislocation was volar (19 cases), radial (18 cases), dorsal (17 cases), and dorso-radial (8 cases). Ulnar dislocation (2 cases) were seemingly less common. Anatomically this makes sense as the trapezoid abuts the ulnar side of the trapezium. Although dislocation was seen across all groups, the proportion

of dislocations which proceeded to implant revision differed among the different groups. Interposition with partial trapezial resection and total trapezial resection groups had lower proportions of implants which were revised due to dislocation than did the total joint replacement and hemiarthroplasty groups. 60% and 61% in the interposition with partial and total trapezial resection groups respectively versus 85% and 68% in the hemiarthroplasty and total joint replacement groups respectively. This suggests that dislocation after a total joint replacement or hemiarthroplasty are perhaps more painful or symptomatic compared to the interposition groups. Closed reduction may also be a viable option for the interposition groups leading to an overall lower proportion of dislocations requiring revision. It is an important finding as the same complication has different outcomes, consequence and severity depending on design concept. The most common author reported cause of dislocation in the total joint replacement group was post fall or other trauma (118, 125, 127). In contrast, the most common author reported cause of dislocation in the interposition with total trapezial resection group was weak capsular support, inadequate capsular repair or ligament reconstruction and non-adherence of the implant to the capsule (61, 163, 164). The presence of osteophytes, particularly incomplete excision of the ulnar osteophyte (165) was commented as a reason for dislocation by a number of authors (118, 128). The presence of a Z deformity caused by dorsal subluxation as seen in stage III and IV OA was also felt to contribute to implant dislocation (64, 105, 133). Other contributors were over or under sizing of the implant, too short a length of immobilisation, foreign body reactions and method of fixation both cemented and press fit.

### Persistent pain

Pain is the main symptom addressed by surgical management of basal thumb arthritis, and thus failure to treat this symptom accounts for a large proportion of implant revisions. Persistent pain was overall the most common complication encountered. 10-year revision

rates due to persisting pain were higher in the groups which had a partial trapezial resection, no trapezial resection, or hemiarthroplasty, 23%, 30% and 8.53% respectively, compared to the total trapezial resection and TJR groups, 1.26% and 2.01% respectively (Figure 43). Persisting pain may exist because the source of pain; the trapeziometacarpal joint, was incompletely removed in the former groups. The design groups with the lowest rates of persisting pain were in fact the total joint replacement and interposition with total trapezial replacement groups, possibly as all of the arthritic joint was completely excised or replaced. Although persisting pain was more commonly encountered in the interposition with total trapezial replacement group than the TJR group, the proportion of patients proceeding to an implant revision was greater in the latter group (13% compared to 27%). This may be due to a perception that the cause of the persisting pain, in the context of TJR, is due to more surgically treatable causes, such as scapho-trapezio-trapezoid (STT) joint OA. Thus, a salvage procedure of trapeziectomy is still available for the TJR. The most common author suspected reason for persisting pain was non-implant related such as progression of OA and involvement of the STT joint, and development or concurrent other sites of OA such as other carpal joints (91), metacarpophalangeal joint, and radiocarpal joint (122, 166). Other possible implant related causes of persisting pain include implant mispositioning, a non-anatomical design (96), oversizing of an implant, concurrent implant dislocation or peri prosthetic fracture (136) and presence of stabilising screws if used (41, 103).

#### Foreign body reaction

The phenomenon of foreign body reaction in basal thumb implant arthroplasty was overall the 4<sup>th</sup> most common reason contributing to implant revision. This complication relates to the material chosen for the implant as well as the design and can be diagnosed histologically with the presence of a multinucleated giant cell reaction to a foreign body. Foreign body reaction was most common in the interposition with partial trapezial resection group (figure

44) and rates of foreign body reaction were driven up in this group due to the Artelon spacer (102, 167, 168). This material (porous polyurethane) and silicon spacers (169-171) have numerous reports of foreign body reaction. Other materials which have also been implicated in foreign body reaction include polythene mesh (77), Dacron (172), Gortex (43), Polylactic acid (101) and Permacol porcine dermal matrix xenograft (82). Some authors have suggested that a foreign body reaction is caused by fragmentation of an implant, that small wear particles increase antigenicity as opposed to the gross implant structure (164). Fragmentation maybe more likely in base of thumb implants due to the larger loads (up to 120N) transmitted across the joint. This may also help explain why foreign body reaction in silicone base of thumb implants is much more common than for silicone implants used for interphalangeal joint replacement. Although much rarer, not only softer materials used for interposition but several accounts of foreign body reaction to metal TJR in the context of nickel allergy has been reported. Especially in TJR design with a metal on metal ball and socket design (130, 134, 173)

### Implant Fracture

Implant fracture occurred across all design groups, similar to foreign body reaction implant fracture too relates to the material the implant is composed of. The highest 10-year revision rate due to implant fracture was the interposition with partial resection and total trapezial replacement groups, 6.54% and 2.15% respectively (Figure 45). Both groups contained implants composed of silicone rubber which has a propensity to fracture. The implants which were implicated in implant fracture were the: Ashworth implant (97, 174, 175), Kessler implant (176), interposition silicone-rubber button (59), Swanson's trapezial implant (58, 164, 170, 175-178), Helal prosthesis (69) and Eaton trapezial implant (62). The design of these prosthesis may contribute to implant fracture as each of the implants mentioned contains a metacarpal stem and trapezial head. This design may encourage for motion to

take place at the junction between the prosthesis head and the metacarpal stem, therefore contribute to implant fracture (97, 164). Other reported causes for implant fracture were heavy use of the hand or trauma (142, 162).

### Subluxation

Subluxation is a complication that is related to dislocation, and was most commonly encountered in the hemiarthroplasty group (figure 46). However less than 1% of cases with subluxation in this group proceeded to a revision, suggesting subluxation is a radiological finding and is unlikely cause clinical symptoms. Similar to the complication of dislocation, the most common author reported reason for subluxation in the total trapezial replacement group was again weak capsular support and inadequate ligament reconstruction (55, 58, 176, 179). Other suspected reasons for subluxation were cold flow deformation and silicone wear overtime (180), pre-existing Z-hyperextension deformity of the thumb (55, 60), and oversizing of the prosthesis (60, 68). The bone quality of the trapezium was again suspected as a reason for subluxation in the total joint replacement group (113, 181).

### Peri-prosthetic Fracture

Peri-prosthetic fractures occurred most frequently in the interposition with partial trapezial resection group (figure 47), however two implant types contributed to the cases of trapezial fracture; The Orthosphere (93) implant and the Ashworth Implant (182). The Orthosphere implant carried a high rate of implant subsidence which was undoubtedly a contributing factor to the trapezial fractures seen with this implant. Although periprosthetic fracture was less encountered in the TJR and hemiarthroplasty groups, a larger proportion of patients proceeded to implant revision. In the TJR and hemiarthroplasty groups revision post a peri-prosthetic fracture was 37% and 29% respectively, compared to 0% in the interposition with partial trapezial resection group suggesting it is a more severe complication in the former

groups if encountered. It is a complication which occurred most frequently after a fall or some other form of trauma (122, 128, 139, 166). A few peri-prosthetic fractures were reported to occur intraoperatively during insertion of the implant during metacarpal or trapezial reaming. (120, 134, 183).

### Post-operative infection

Overall, the rate of revision due to an infection was low, 0.69% in 10-years. However, if encountered, it was a severe complication, as 45% of implants required a revision if an infection was implicated. It was more commonly encountered in the interposition groups compared to the TJR and HA groups (Figure 48). It is difficult to comment on why this maybe. Perhaps it is related to length of splinting or patient compliance with post-operative antibiotics. Patients after a TJR or HA maybe more compliant due to a perception that it is more extensive surgery which needs more care. The differences seen may also relate to bias due to the overall rarity of the complication.

### Osteolysis, implant subsidence, periprosthetic ossification, radiological loosening, and implant resorption/wear

The complications of osteolysis, implant subsidence, periprosthetic ossification, radiological loosening and implant resorption/wear are likely to be asymptomatic incidental radiological findings on routine follow up x-rays, as revision due to these complications were rare.

### Osteolysis

The complication of osteolysis was most frequently encountered in the interposition with partial and total trapezial replacement groups; 124 cases out of the reported 192 in the interposition with total trapezial replacement group were from the study by Creighton et al (184) evaluating silastic trapezial implants. Although frequently encountered, osteolysis was infrequently a cause for revision, only 4.70% of cases with osteolysis were revised. This

supports the common finding that radiological changes demonstrated do not correlate with clinical symptoms leading to implant revision (184). The presence of osteolysis in silastic trapezial implants with the formation of bony cysts is believed to be due to foreign body reactions (182, 184). Other author suspected causes included implant movement occurring around the metacarpal stem (55), a stress shielding effect caused by the implant (71, 131)

### *Implant Subsidence*

Implant subsidence was a complication which was encountered more frequently than one which caused implant revision. The complication occurred most frequently in the interposition with partial trapezial resection group. As mentioned previously, the Orthosphere implant contributed a massive 53 out of 56 cases reported (93, 94). The authors suspect that implant subsidence is high in this implant due to the small area of implant and bone contact and the support for the implant is provided by cancellous bone (94). Furthermore, it is a ceramic implant and the modulus mismatch between cancellous bone and the implant is likely to contribute to implant subsidence. In the total joint replacement and hemiarthroplasty groups implant subsidence was encountered but again was an infrequent cause for revision. Semere A et al (122) reported a high rate of subsidence in the Roseland prosthesis; however, this was not correlated with clinical symptoms and did not require surgical management. Similar to osteolysis, implant subsidence is also a sign of stress shielding (122). Several authors (134, 142) again note poor trapezial bone quality as a cause for implant subsidence.

### *Peri-prosthetic ossification*

Peri-prosthetic ossification is a complication exclusive to total joint replacements. Similar to osteolysis and implant subsidence, peri-prosthetic ossification is also a radiological finding, that does not frequently lead to implant revision. Cooney WP (107) theorized peri-prosthetic

ossification may be due to pre-existing heterotrophic ossification of support ligaments, and due to the heat produced by polymerization of methacrylate. Although it is not clear if similar factors apply; the development of periprosthetic ossification in total hip arthroplasty is associated with male gender, hypertrophic osteoarthritis, ankylosing spondylitis, diffuse idiopathic skeletal hyperostosis and has been shown to decrease with the use of NSAIDS such as indomethacin (185).

#### *Radiological loosening with peri prosthetic lucency*

Radiological loosening is purely a radiological finding that shows radiolucent lines along the edge of implants. This was a common finding in TJR, hemiarthroplasty and interposition with total trapezial replacement groups. The common denominator in each of these implants is an intramedullary metacarpal stem. None of the encountered 305 cases were revised due to the presence of periprosthetic lucency. The study by Stillwater et al (146) note that the presence of a radiolucent lines 1mm or less in pyrolytic carbon implants such as the Pyrohemisphere is normal. This is due to Pyrocarbon implants contain a radiopaque graphite core and a coating of pyrolytic carbon which is radiolucent. The study by De Smet et al found younger age was related to radiological loosening (157) and the study by Jennings et al (186) found loosening was more common in osteoarthritic hands as compared to rheumatoid hands, both suggesting that loosening maybe related to higher demand hands.

#### *Implant resorption/wear*

Resorption or wear of implants was a complication rarely encountered. The complication was reported only in four implant types, none of which required a revision. Silicone synovitis is potentially a reason for implant resorption in silicone implants (187). Implant subluxation may result in abnormal implant wear, for example ulnar implant wear secondary to radial



implant subluxation (64). Implants with greater stability may also be more at risk of wear (188)

### All cause failure

The all cause 10-year revision rates were highest in the interposition with no trapezial resection and partial trapezial resection groups. The main cause for revision in these groups was persisting pain (Figure 58 and 60). As discussed above it is likely that the pain associated with basal thumb arthritis is best treated with total excision of the trapezium or replacement of the joint. The TJR and hemiarthroplasty groups had similar overall 10-year failure rates of 24% and 25% respectively. The main complications which lead to implant failure in the both groups were aseptic loosening, dislocation and persisting pain (Figures 56 and 57). The implant group with the overall lowest all-cause failure was the interposition with total trapezial resection group; 10-year failure rate of 17%. The most common complications leading to revision in this group was dislocation, subluxation and foreign body reactions (Figure 59).

### Limitations

#### *Implant classification*

Currently a large number of different implants are available for treatment of base of thumb OA. Previous reviews on implant arthroplasty (54, 189) proceeded not to conduct meta-analysis due to the heterogeneity of the implants. However, meta-analysis and data synthesis in this review was possible. By grouping implants by their basic design, an assumption is made that all implants within each group are the same, however this is not true. There is much heterogeneity in the implants between as well as within each group. The identified implants were divided into five classes based on the Vitale classification of trapezial implants(54). Although this system groups implants broadly by basic design concept, much heterogeneity still exists within implants of the same group or class. Heterogeneity within a class of implants can be related to implant design, material and

method of fixation. For example, the total joint replacement group contained implants with a ball-socket design (ARPE and De la Caffiniere prosthesis) as well as reverse ball-socket designs (Rubis II and MOJE prosthesis) with the socket component of the implant on the metacarpal surface. Total joint replacement implants may be composed of different materials, for example ceramic (MOJE prosthesis), and cobalt-chromium (De la Caffiniere prosthesis). Furthermore, implants may be cemented (GUEPAR and De la Caffiniere) or have press-fit fixation (MOTEC, Roseland and ARPE prosthesis). Despite the heterogeneity, these implants were all classed as total joint replacements. Implant design, material used and method of fixation are all important factors when considering the complications which lead to implant failure. Although heterogeneity exists with each class of implant, it is much less than between classes of implants. Therefore, it provided a broad overview on the basic design which an implant with an ideal morphology may contain.

#### *Method of data synthesis*

The complication and failure rates of the implants and implant groups were calculated by the method employed in the first stage of screening by the AOANJRR to identify orthopaedic prosthesis with higher than anticipated rate of failure. The method is to calculate the number of revisions per implant-years. This method provides a good estimate of overall rates of revision however the main limitation is that it is a linear model which does not account for changes in rate of revision over time. An assumption is made that the risk of revision for an implant or class of implants does not vary over time, however, it is likely that joint replacements follow a 'U' shaped rate of failure similar to other mechanical devices. An initial high rate of failure followed by a plateau phase, again followed by a high rate of failure as the implant components reaches its life expectancy<sup>24</sup>. A more informative

model to estimate rates of revision would be a cumulative percent revision or Kaplan-Meier curve as this would account for changes in rate of revision over time. In this scenario however, it was not possible to use a cumulative percent revision to model the data as it was sourced from the published literature, of which majority of the studies were retrospective case series which contained incomplete data sets. A year by year account of the exact time of revision, the number failed, number lost to follow up, and number of deaths would be required to derive the true population at risk to accurately determine cumulative percent revision. It is therefore best calculated from prospectively collected data such as in implant registries. Although the method used to derive failure rates carries limitations, a major advantage of using this method was that it allowed data to be combined from all levels of evidence (except case reports). This was advantageous as the majority of included studies were retrospective case series. It was also a useful tool to standardise complication and failure rates between implants and implant groups to determine with clarity which implants or implant groups carried high or low complication and failure rates.

#### *Search strategy and data collection*

The review was limited to English language papers only. A large number of articles reporting on trapezial implant arthroplasty exists in the foreign language literature. Over 100 articles in French, German, Spanish, Italian, Dutch, Norwegian, Hebrew, Czech and Finnish were excluded on this criterion. A more comprehensive review could include all

published articles in all languages. This would be advantageous as basal thumb implant arthroplasty is more popular in Europe than it is in America(190) and Australia.

The review also included articles without limitations on date of publication. Therefore, some articles were included which reported on implants which were no longer in use or available e.g. the original design de la Caffiniere prosthesis (191). Including such implants adds little value to current practice and may have artificially driven up failure rates especially as these implants were discontinued due to high rates of complications and failure. It was however important to assess the earlier models of implants to determine unfavourable design characteristic.

The data items collected focused on complications and failures and did not collect items on other outcomes such as range of movement, Kapandji score and pinch and grip strength, which are equally important factors in considering the performance of an implant.

## Conclusion

The most pertinent results of the above review are the overall failure rates of the trapezial implant groups. The interposition with total trapezial resection group contained the overall lowest rates of failure. Similarly, of the non-implant techniques discussed earlier, total trapeziectomy with ligament reconstruction and interposition also contained the lowest overall rates of failure. This supports the conclusion that total trapeziectomy and interposition (of some material, implant or tendon) is one of the most effective surgical method of treating base of thumb arthritis. Therefore, it follows that a trapezial implant with an ideal morphology should be used as an interposition spacer post total trapeziectomy. The main reasons for implant failure in implants used as spacers post total trapeziectomy

were dislocation and subluxation. Hence, a new implant design should have specific features in place to confer implant stability to reduce dislocation and subluxation rates.

# **CHAPTER 3**

## **3D printing and validation studies**

## CHAPTER 3: 3D printing and validation studies

Chapter 3 research outputs:

Published:

- Ganhewa AD, Wu R, Chae MP, Tobin V, Rozen WM, Hunter-Smith DJ. 3D Printing in Surgical Planning and Research: A Validation Study. ANZ J. Surg. 2018; 88(S1) 71-79

### Introduction

3D printing in medicine is an area which is rapidly expanding and currently has multiple applications. An idea for a trapezoidal implant that complies with the basic design concept of interposition with total trapezoidal resection is a 3D printed trapezium which contains the same morphology as a native trapezium. Although the most widely used application of 3D printing in surgery are anatomical models used for teaching and surgical planning (192-195), a quick search of the literature reveals many examples of how 3D printing can be used for personalised implants and prosthetics which take in to account an individual's unique anatomy. To our knowledge, a 3D printed trapezium currently does not exist. The following paragraphs discuss customized 3D printed implants and prosthesis which have so far been trialled successfully.

Since the introduction of 3D printing in the late 1980's, instead of using mass-produced medical implants there has been notable a shift towards individualised treatment (196). Many companies around the world are leading the way in creating 3D printed patient specific implants (PSI), such as LayerWise in Belgium. An early application of 3D printed implants was in creating customised hearing aids to fit exactly in an individuals' external ear canal (197). It was an advantageous body region to use 3D printed technology as there is variation

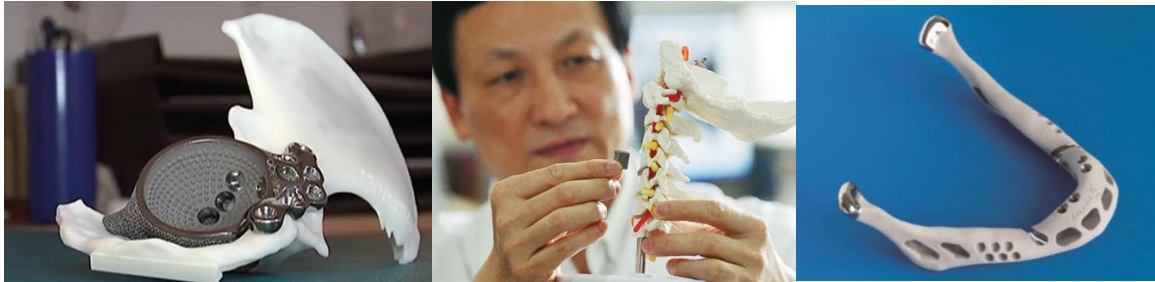
in anatomy between individuals' ear canals, and it was to be used ex-vivo therefore, contained less regulatory hurdles before implementation. Laser technology is used to create a digital impression of the external auditory canal which is in turn transformed into a 3D printed model. It is now estimated that 99% of externally worn hearing aids are made using 3D printing technology. Similarly, another application for externally worn and individualised 3D printed objects are bespoke orthotics and insoles.



**Figure 66. 3D printed hearing aids (Banks, IEEE Pulse, 2013)**

3D printing can be used to create customised implants or produce standard implants more rapidly. Customised implants provide more options to surgeons in treating complex cases in which standard implants are insufficient. Customized 3D printed implants have been successfully trialled in orthopaedic surgery, spinal surgery and maxillofacial surgery (198). A portion of a 12-year-old patient's vertebrae was replaced by a 3D printed piece, post resection of a spinal cord tumour at Peking University in 2014. The Mayo clinic also performed a one-off hip replacement using a custom-made hip prosthesis on a patient in her 20's with early onset osteoarthritis. Similarly, in 2012 LayerWise, the 3D printing Belgian company produced a customised acetabular implant for a 16-year-old with Recklinghausen's disease. The patient had a deformed acetabulum which could only be replaced with a bespoke implant. The cases describe 3D printed implants replacing a portion of skeletal anatomy. However, a complete replacement of the mandible was done using a 3D printed mandible in a patient with chronic mandibular osteomyelitis. (Figure 62)





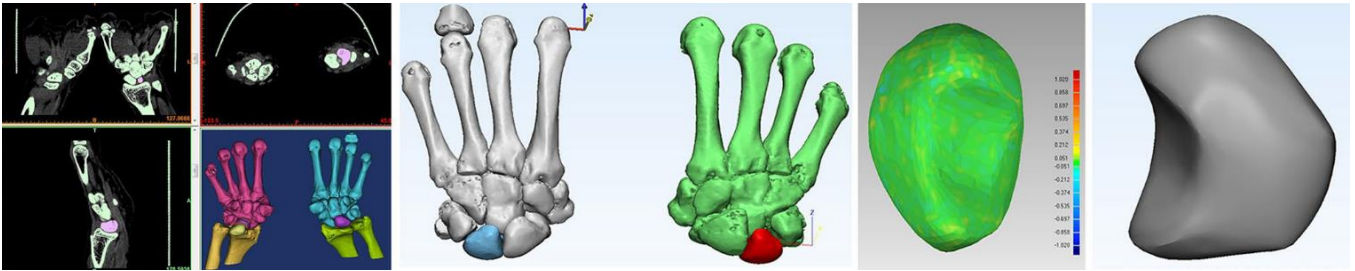
**Figure 67. Custom made acetabular implant for patient with Recklinghausen's disease (left) (reuters.com, 5<sup>th</sup> November 2018), 3D printed vertebrae piece to fit exactly the vertebral deficit post spinal cord tumour resection (centre) (forbes.com, 5<sup>th</sup> November 2018), 3D printed mandibular implant (right) (csmres.co.uk, 5<sup>th</sup> November 2018)**

3D printed implants can be made from various materials including metals (such as gold, tantalum, stainless steel, titanium alloy and cobalt chromium), ceramics (such as metallic oxides, calcium phosphate and glass ceramics), polymers (such as ultra-high molecular weight polyethylene, polymethyl methacrylate, polylactic acid, polyglycolide and polyhydroxybutyrate) and other composites. Many orthopaedic PSI, to date, are printed in metal. However, the modulus mismatch as seen with standard metal implants leads to stress shielding and causes osteolysis and aseptic loosening of the implant. Ceramic based implants also lack elastic modulus compatibility to bone and contain a low fracture threshold which is inappropriate for weight bearing joints. The polymers too, are frequently used however, maybe too flexible or weak for load bearing. To address these concerns, new materials, such as polyetheretherkone (PEEK), are being trialled for this purpose. The paper by Honigmann et al describe printing using PEEK to create PSI for cranial defects, a midface-zygomatic bone implant and total scaphoid bone replacement (196).



**Figure 68. Patient specific implants printed in polyetheretherkone. Cranial defect (left), maxillary-zygomatic implant (centre) and scaphoid bone replacement (right) (Honigmann, Biomed Res Int, 2018)**

Similar to the total scaphoid bone replacement, a total lunate replacement has been performed using a 3D printed lunate for a patient with avascular necrosis of the lunate (Kienbock's disease). Xie et al describe the process of 3D printing the patient's lunate (199). MRI scans were taken of both (affected and unaffected) hands. Using an image processing platform 3D surface models were created of the unaffected wrist's lunate and mirrored to match the affected side. The surface model then appears to have been 3D printed in metal. The patient proceeds to surgery to have the necrotic lunate completely excised and the 3D printed lunate prosthesis placed in the lunate space with correct anatomical alignment. The authors comment that the surrounding scapho-lunate ligament and lunate-trapezoid ligaments were released and not repaired. However, a tight closure of the joint capsule was performed. The position and stability of the implant was confirmed intra-operatively using fluoroscopy while manipulating the wrist. The patient was followed up for 12 months at which point no subluxation or dislocation of the implant was noted on x-ray. The authors comment on the implant stability which is provided uniquely by bony congruity of the adjacent scaphoid, capitate and triquetrum (199).



**Figure 69. The process of creating a 3D surface model from the unaffected wrist, and mirroring the image to match diseased wrist's lunate (Xie, Arch Orthop Trauma Surg, 2018)**

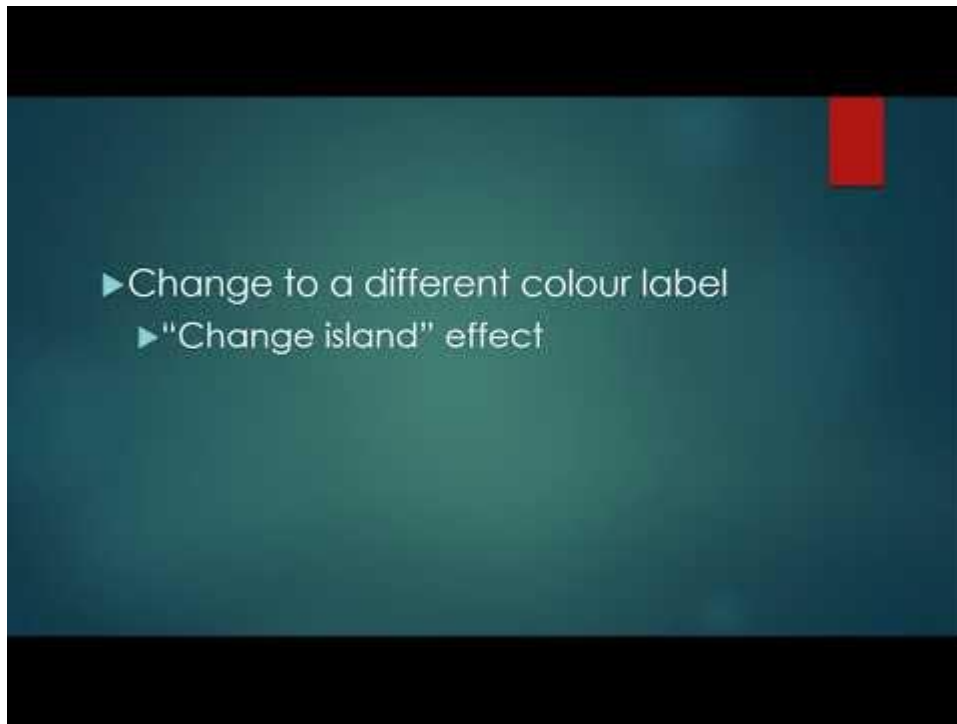The authors fail to mention the exact image processing software, and the material the prosthesis was printed in. However, a good result was achieved in the patient's wrist range of movement which equalled to 90% or greater in wrist extension, flexion, ulnar deviation, radial deviation and power grip. A visual analogue scale, presumably for pain, was rated as 2. The authors conclude 3D printed lunate prosthesis is a viable treatment option for stage IIIc Keinbock's disease. The above case demonstrates proof of concept that it is possible to 3D print carpal bones to be used as patient specific implants to replace diseased ones.

### How to 3D print a trapezium

All 3D printing is done in a stepwise fashion; therefore, 3D printing a patient specific implant is no different. Prior to printing, the desired section of a patient's anatomy must first be imaged usually by standard imaging modalities such as CT and MRI. The scanned anatomy is presented slice by slice in Digital Imaging and Communication in Medicine (DICOM) format which can then be uploaded to, opened, and processed by a computer aided design (CAD) software program such as 3D slicer (Surgical Planning Laboratory, Boston, MA, USA) (200). A virtual 3D surface model is created through a process of segmentation. The virtual model can then be saved as a stereolithography (STL) file, which can be recognised and

opened by 3D printer software to be printed in a nominated material. Depending on the geometry of the object, support structures may need to be added to the surface model to ensure the integrity of the printed object during the printing process. Usually once printing is complete some post-processing of the model or implant is required. For example, support structures may need to be removed manually, and metal components often display a rough finish which may need to be polished or heat treated (197). The following paragraph describes in greater detail the process of creating a virtual 3D surface model from DICOM images using the CAD program 3D slicer 4.6.2.

Firstly, CT or MRI scan images in DICOM format are uploaded to the *3D slicer program*. Once uploaded the contrast is adjusted to adequately view the images. Using the “Editor” module, a “thresholding effect” is applied to create a single label map. The “threshold effect” (which uses Hounsfield units to highlight structures of a certain density) can then be adjusted to maximally include the object of interest and exclude undesired background structures. Once the desired threshold is applied, any additional label visually connected to the desired object is deleted. This process is continued slice by slice in all planes: coronal, sagittal and transverse until the object of interest is completely islanded, again, on all planes and in all slices. One of two things can be done at this stage: “Change island effect” to label the object of interest with a different colour label to the background or “save island effect” to delete any back-ground label therefore only the object of interest remains labelled. The object of interest is then uniformly filled with the same colour label, on all slices, in all planes, using “paint effect”. It is essential to colour the object interest completely solidly. Any patches which remain unfilled will in turn not be 3D printed. Once satisfied the object of interest is adequately segmented, a 3D surface model can now be created using “make model effect”. The surface models and its details, such as volume and surface area can be viewed in the “Models” module.



**Figure 70. The following video demonstrates the steps involved in creating a 3D surface model from DICOM images in 3D slicer program**

#### Validation studies

The CAD program *3D slicer* (200) has been developed for DICOM image analysis with capabilities of processing medical imaging to create 3D surface models, as described above. A surface model is a 3D visualisation of segmented structures from an imaging modality such as CT or MRI. The surface models created using 3D slicer are only as accurate as the segmentation undertaken of the object of interest. This process relies on the ability and judgement of the user to decide which pixels to include or exclude when segmenting out the anatomy of interest. If one was to consider all the stages required to create a 3D printed object; the segmentation process used to create the surface model has been shown to introduce the greatest degree of variability (201). Therefore, validating the method of creating surface models (as well as the surface models themselves) using 3D slicer is a pre-

requisite to using the program for research purposes and accurately 3D printing a prosthetic trapezium.


The purpose of the following validation studies was to:

1. Assess the accuracy of the surface models generated by 3D slicer
2. Quantify the effect of smoothing function on the surface models
3. Assess inter and intra user variability of segmentation when creating surface models on 3D slicer.

#### Methods:

##### *Accuracy of surface models produced by 3D slicer*

The volume of objects derived by 3D slicer were compared with the volume of the same objects derived by water displacement. Volumetric analysis by 3D slicer and water displacement was done on small garden rocks (which were approximately the size of carpal bones) purchased from Bunnings garden warehouse. The rocks were labelled 1-50 and placed through the Frankston hospital Emergency Department (ED) CT scanner. The CT images of the rocks were uploaded on to 3D slicer program version 4.6.2. The volume of each rock was derived by creating a surface model of each rock as described previously. The process of segmentation was largely automated using 'threshold effect' as rocks have a uniform and high density. Volumetric analysis by water displacement was undertaken on each of the 50 garden rocks by using a 50ml syringe with its nose blocked and handle removed. The syringe was partially filled with an arbitrary amount of water and each garden rock was consecutively placed inside the partially water filled syringe. The number of millilitres by which the water was displaced was recorded for each rock, to the accuracy of 1ml.




**Figure 71. Photograph of the 50 rocks used for volumetric analysis by water displacement (left) and Screenshot of 3D reconstructed virtual models of the rocks by 3D slicer (right).**

*Quantifying the effect of smoothing function on the surface models*

The surface models of the same small garden rocks were created with and without the effect of smoothing function. A further 10 large beach rocks were collected from mount Eliza beach, which were also placed through the Frankston Hospital CT scanner. Surface models of the rocks were created, again with and without the effect of the smoothing function. The effect of smoothing on large and small objects were compared.





**Figure 72. The surface models of the rocks created with smoothing effect (top) and without smoothing effect (below).**

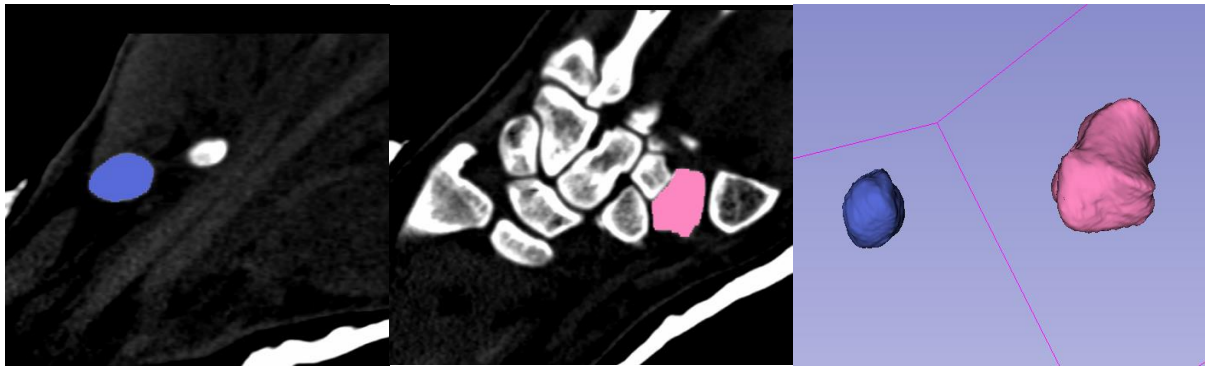


### *Inter and intra-user variability in creating surface models with 3D slicer*

Inter and intra user variability when creating surface models is more critical when majority of the segmentation process must be done manually, for example when segmenting carpal bones. The bones have variable density due to the presence of cortical and cancellous bone. Therefore, unlike the rocks, it is not possible to segment the bones using only thresholding.

To assess user variability in segmenting, low risk ethics approval was granted by the Peninsula Health ethics committee to access 50 CT wrist scans for research purposes. The scans were obtained from the Frankston Hospital radiology department. Each scan was anonymised and labelled 1-50. Each scan was then re-assigned a new number in an effort to blind the researchers when the same scan was segmented twice. Each CT scan was uploaded to 3D slicer and the volumes of the trapezium and pisiform bones were derived by creating surface models of the carpal bones of interest.

To compare intra-user variability, two surface models of the trapezium and pisiform bones were created by a single individual (DG) on two separate occasions. To compare inter-individual variability, surface models of the trapezium and pisiform were created by two individuals (DG and RW) independently. The volumes of the surface models were recorded for each attempt and compared for any significant differences as well as reliability using the interclass correlation co-efficient (ICC).



**Figure 73. Screenshot of segmented trapezium (Pink, middle) and Pisiform (Purple, left) and 3D virtual surface model of trapezium and pisiform (right)**

#### *Statistical analysis*

The distribution of data populations were assessed using the Shapiro Wilk test. Data which did not pass were analysed using non-parametric tests - either the Wilcoxon Signed Rank test or a One-Way Repeated Measures analysis of Variance on Ranks to examine the statistical significance of the difference between repeated measurements made by one or between two individuals respectively. These tests investigated difference and did not investigate consistency or reliability.

The Interclass Correlation Coefficient (ICC) is a measure of consistency of measurements of the same items which are made by multiple researchers and was used to determine the reliability and agreement between results. ICC estimates and their 95% confidence intervals were calculated by both absolute agreement and consistency of agreement using a two-way random-effects models. Interpretation of the of the ICC estimate may be made as follows: “values less than 0.5, between 0.5 and 0.75, between 0.75 and 0.9, and greater than 0.90 are indicative of poor, moderate, good, and excellent reliability, respectively” (202)

All tests were conducted using STATA (v14).

## Results

### *Accuracy of surface models produced by 3D slicer*

<i>N=50</i>	<i>Water displacement</i>	<i>3D Slicer</i>	<i>Difference</i>
	<i>mm<sup>3</sup></i>	<i>mm<sup>3</sup></i>	<i>mm<sup>3</sup></i>
<i>Median ± (95%) CI</i>	<i>5300 ± 632</i>	<i>5313 ± 621</i>	<i>32 ± 123</i>
<i>Mean ± standard deviation</i>	<i>5608 ± 2282</i>	<i>5597 ± 2243</i>	<i>11 ± 445</i>

**Table 19. Shows the results of volumetric analysis of rocks by water displacement and 3D slicer**

The two data populations (volume measurements of the rocks by water displacement and 3D Slicer) were assessed for normality using the Shapiro-Wilk test and failed ( $P < 0.05$ ). Thus, non-parametric tests were used to assess their differences using the Wilcoxon Signed Rank test. This found there was not a statistically significant difference between the rock volume measurements made by volume displacement and 3D Slicer ( $Z = 0.893$ ,  $P = 0.374$ ).

Volumetric analysis of rocks by *3D slicer* and water displacement had an ICC of 0.996 (CI 0.993-0.997) corresponding to excellent reliability of agreement between the two methods.

*Quantifying the effect of smoothing function on the surface models*

*Large beach rocks*

Two repeats of the volume measurements were made with and without the smoothing effect. All four data sets were normally distributed therefore a two-way ANOVA was used to determine any statistically significant effect of smoothing.

The difference in the mean volumes of the models with and without smoothing are greater than would be expected by chance ( $P = 0.030$ ). Therefore, a statistically significant difference exists in the volume of the surface models of the large beach rocks created with and without the smoothing effect.

<i>N=10</i>	<i>Mean volume (mm<sup>3</sup>) without smoothing ± SD</i>	<i>Mean volume (mm<sup>3</sup>) with smoothing ±</i>
<i>Beach rocks trial 1</i>	<i>146704 ± 71225</i>	<i>146722 ± 70278</i>
<i>Beach rocks trial 2</i>	<i>145338 ± 71248</i>	<i>145377 ± 70329</i>

**Table 20. Shows the volume changes as a result of using the smoothing function when creating surface models of the large beach rocks**

*Small garden rocks*

The two data sets did not contain normally distributed data by the Shapiro-Wilk test ( $P < 0.05$ ) therefore non-parametric the test (Wilcoxon signed-rank test) was used to detect significant differences between two data sets ( $P = 0.000$ ). Therefore, a statistically significant difference exists in the volume of the surface models of the small garden rocks created with and without the smoothing effect.

<i>N=50</i>	<i>Mean volume (mm<sup>3</sup>) without smoothing ± SD</i>	<i>Mean volume (mm<sup>3</sup>) with smoothing ±</i>
<i>Garden rocks</i>	<i>6113 ± 2298</i>	<i>6109 ± 2297</i>

**Table 21. Shows the volume changes as a result of using the smoothing function when creating surface models of the small garden rocks**

*Intra-user and inter-user variability in creating surface models with 3D slicer*

The normality test (Shapiro-Wilk) also failed for the intra- and inter-variability studies, therefore non-parametric tests were again used to investigate whether there were significant differences between repeated measurements made by one individual or by two. There was no statistically significant difference between the repeated measurements made by one individual who was blinded to the CT scan identities (first versus second measurement,  $p=0.76$  by Wilcoxon Signed Rank Test). Similarly, there was no statistically significant difference between measurements made by two individuals (measurements from DG vs RW,  $p=1.00$ , by One Way Repeated Measures analysis of Variance on Ranks). These tests report only statistically significant differences, but do not give an indication of variability and/or reliability of measurements; for this the ICC were calculated for the intra- and inter-variability studies.

	<i>N</i>	<i>Mean volume (mm<sup>3</sup>) ± standard deviation</i>
<i>Trapezium Volume 1</i>	48	2266 ± 628
<i>Trapezium Volume 2</i>	48	2326 ± 585
<i>Difference</i>		53 ± 879
<i>Pisiform Volume 1</i>	47	839 ± 308
<i>Pisiform Volume 2</i>	47	888 ± 307
<i>Difference</i>		14 ± 415

**Table 22. Shows the volumes of the trapezium and pisiform surface models (average ± standard deviation) created using 3D slicer by a single individual (DG) multiple times**

The intra-user variability or agreement between blinded repeat measurements of the same trapezium and pisiform bones had an average ICC of 0.86 (CI 0.75,0.92). This corresponds to “good” reliability between repeated measurements (204). This result was statistically significant (P=0.00).

	<i>N</i>	<i>Mean mm<sup>3</sup></i>
<i>Trapezium Volume DG</i>	48	2256 ± 619
<i>Trapezium Volume RW</i>	48	2345 ± 541
<i>Difference</i>		89 ± 895
<i>Pisiform Volume DG</i>	47	857 ± 317
<i>Pisiform Volume RW</i>	47	870 ± 286
<i>Difference</i>		13 ± 465

**Table 23. Shows the volumes of the trapezium and pisiform surface models (average ± standard deviation) created using 3D slicer by two individuals (DG and RW)**

The inter-user similarity or agreement between blinded repeat measurements of the same trapezium and pisiform bones had an average ICC of 0.95 (CI 0.95,0.97). This corresponds to “Excellent” reliability between repeated measurements (203). This result was statistically significant (P=0.00).

## Discussion

The main reported limitation in 3D printing, along with additional cost and time required to prepare the 3D printed object, is the accuracy of the 3D print (204). The current series of studies were aimed at validating SM used in the process of creating 3D printed objects. Validation of the SM created using 3D slicer was necessary, as the potential for user variability is introduced during the segmentation process. This is due to the combination of automated as well as manual segmentation used. Automated segmentation uses thresholding to highlight structures of a certain density or Hounsfield unit. Manual segmentation is done visually to include or exclude structures deemed necessary or unnecessary. The choice of the thresholding value as well as the manual segmentation relies on user judgment and experience, in the domain of anatomy concerned, as well as familiarity with the software in use. Hence the requirement to validate the process and accuracy of SM to ensure the resultant 3D printed objects can be accurately and reliably produced.

Volumetric analysis of rocks by Archimedes principles of water displacement and use of 3D slicer generated SM showed no statistical significance between the groups and excellent reliability of agreement between the two methods, therefore validating the accuracy of SM produced and volumetric analysis by 3D slicer. In this instance, majority of the segmentation of the CT images of the rocks were done using automated segmentation as each rock appears isolated from one another and is of uniform density. The current results however may not be applicable to scenarios which require both automated and manual segmentation e.g. anatomical structures of varying density, such as bone and soft tissue.

The study done to assess smoothing function in 3D slicer showed that adding the smoothing effect does have a significant effect on the volume and hence, size of the resulting surface model. However, the commonly used statement 'statistically significant but



not clinically significant' might be applicable in this scenario as the differences were between 10-30mm<sup>3</sup> between the models. Furthermore, the effect of smoothing on large compared to small objects appears to be different. The surface models of the large rocks with the smoothing function are smaller than the surface models without it. However, for the smaller rocks the reverse is true; adding the smoothing effect had an increase in size of the volume of the surface models. This is likely related to the algorithms employed by the software when applying the smoothing effect to surface models; in larger objects perhaps, the peaks of the triangulated model is capped, compared to smaller objects where the troughs in the triangulated model is filled to achieve the effect of smoothing. As the volumes of a potential 3D printed trapezium would reflect more closely that of the small rocks it can be hypothesised that the resulting surface model and hence the 3D printed trapezium may be larger than the native bone. However, as the volume increase is minor it is unlikely to have any clinically significant effect. Furthermore, unlike segmentation of rocks which are largely automated using thresholding, greater inter and intra user variability is introduced when segmenting carpal bones such as a trapezium due to requirement of more manual segmentation. This is likely due the variability in density of the bone as well as unique morphology especially in aging bones with osteophytes.

The study done to validate inter and intra-user variability also showed no statistical differences and good to excellent reliability of agreement between a single and multiple user. The inter-user ICC was higher suggesting greater reliability between users compared to a single user. A limitation of the study was analysing the result of two users, as opposed to more than two. Excellent inter-individual reliability may be explained as both users are colleagues who were taught and used the same methods of segmentation. The study can be strengthened by having greater than two users and from different centres. Another reason for the lower intra-user reliability may be due to a learning curve associated with

using 3D slicer and the segmentation process. Furthermore, the absolute error difference for larger volume objects such as the trapezium was greater than for smaller volume objects such as the pisiform.

A review of the literature revealed a small number of other studies which validate the process and accuracy of 3D printing. The study by Smith et al (201) used segmented CT images of the shoulder and hip joints to produce 3D printed reconstructions, which were then compared to the original cadaver specimens as well as the virtual surface model through 3-way shape analysis using laser scanning. The overall reproducibility from cadaver to 3D printed model had a root mean square error (RMSE) of 0.3 +/- 0.4mm. The RMSE from cadaver to surface model was 0.3+/-0.4mm and virtual model to 3D print was 0.1+/-0.1mm, which suggests that the greatest error occurred in the segmentation process and accuracy of segmentation was the critical factor in determining accuracy of the 3D print (201).

The study by McMenamin et al assessed the accuracy of 3D printing by comparing 3D printed upper limb prosections to the original. The image processing software Aviso was used in this study to segment the structures of interest using a combination of tools including thresholding. Quantitative analysis using callipers of structures 10mm or more showed a mean absolute error of 0.32mm. Repeatability and intra-observer variability was assessed by repeated measurements of maxillary dentition of the original specimen and a 3D reconstruction. The ICC for the repeated measurements (0.998,  $p < 0.001$ ) of the original specimen was similar to that of the 3D printed model (0.998,  $p < 0.001$ ). The authors conclude by advocating the use of 3D printed replicas as teaching aides due to high accuracy and reproducibility (205).

The validation study by cone et al, again compare 3D printed replicas of animal long bones to the original specimens found the overall discrepancy in dimensions of 1%. The 3D printed models over represented the dimensions. The authors conclude that the 3D printed models have high repeatability, with prints being slightly larger than the original bones (206). The study by Khalil et al validated 3D printed models of premolars by volumetric analysis by water displacement of the models and originals showed the mean volume difference ranged from 0.7 % to 1.9%. The authors conclude a high degree of accuracy of printed teeth compared to natural teeth (207). Similarly, the validation study by Maschio et al compared 3D printed mandibles to their respective dry specimens and found the mean absolute difference of 8 distances between the 4 mandibles was 0.37mm. This study also found that the error difference decreased for distances greater than 12mm from 3.76% to 0.93%. The authors conclude that the low-cost 3D printers used in this study produced models of similar dimensional accuracy to that of other well-established 3D printers (208).

## Conclusion

The image computing platform *3D slicer*, can be used to generate accurate surface models which would in turn result in accurate 3D printed objects. The program is independent of user variability and shows good to excellent agreement between a single user and multiple users.

# **CHAPTER 4**

## **Anatomy of the trapezium and individual variation**

## CHAPTER 4: Anatomy of the trapezium and individual variation

Chapter 4 research outputs:

Published:

- Ganhewa AD, Chae MP, Tobin V, Rozen WM, Hunter-Smith DJ. Detailed Morphological Anatomy of the Human Trapezium: A Clinical Anatomical Study. ANZ J. Surg. 2018; 88(S1) 71-79

Presented:

- Ganhewa AD, Chae MP, Tobin V, Hunter-Smith DJ, Rozen WM. The aging carpus. Oral presentation, Surgical symposium Peninsula health 2018, Frankston Hospital.

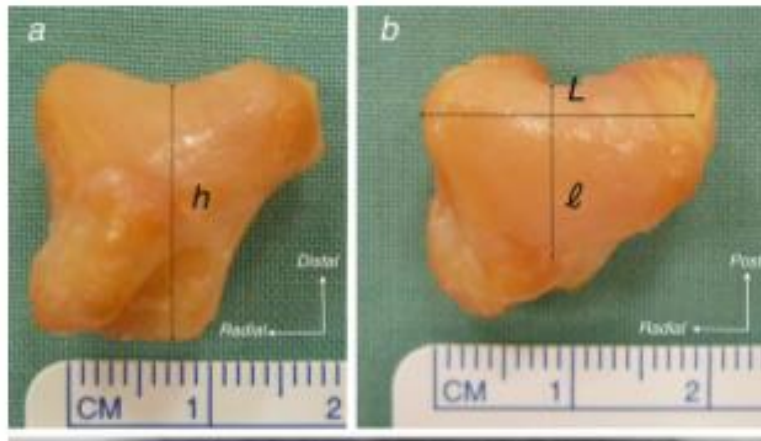
### Introduction

A trapezial implant with an identical morphology to the native trapezium can be imminently achieved in the form of a 3D printed trapezium. To go forth with such a design requires good knowledge and understanding of the morphology, functional anatomy and biomechanics of a native trapezium; in healthy as well as diseased states. This understanding is critical as it would also be applicable to the implant. A 3 D printed trapezium would literally be a reflection of the native.

### Morphology and functional anatomy

#### *The healthy trapezium*

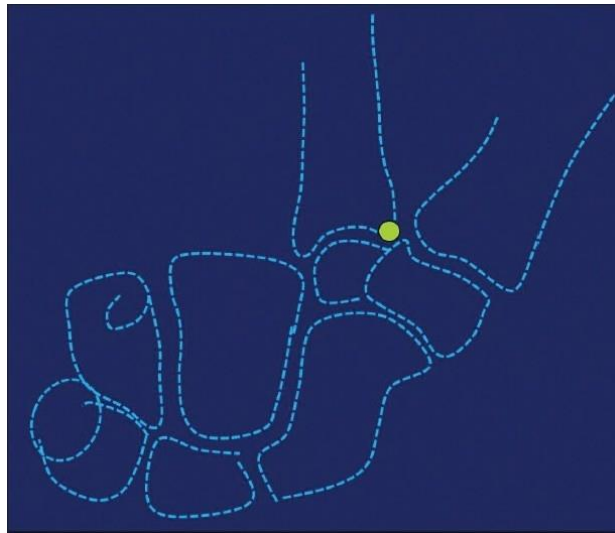A healthy trapezium is approximately the size of a small brazil nut. Similar to other aspects of the skeletal system, the trapezium too contains some sexual dimorphism. The study by Loisel et al found the average length, width and height of trapezium bones measured on CT to be larger in men than women. On average, for both men and women combined, dimensions of length, width and height were 19.2mm, 11.4mm and 11.6mm respectively (209). The study by Schneider et al also found that the trapezium and metacarpal, and therefore the articulating surfaces, were smaller in women than in men (210).



**Figure 74. The dimensions of a healthy trapezium (Loisel, Surg Radiol Anat, 2015)**

The differences in trapezia between men and women seem to exclusively be associated with size, and the normalised volume or proportion of the trapezium with respect to net volume of the carpus remains relatively constant between genders. The study by Crisco et al showed that although the average volume of the healthy trapezium was  $2394.8\text{mm}^3$  in men and  $1547.1\text{mm}^3$  in women, the relative volume of the carpus which each bone occupies stays fairly constant. These findings support the theory that the differences in trapezium size encountered between genders can be accounted for by isometric scaling i.e. A male trapezium is a larger version of a female trapezium and vice versa. (211)

The unique morphology of the metacarpal surface of the trapezium has been described as a 'twisted saddle' or 'biconcavoconvex'. The metacarpal articular surfaces are convex in the volar-dorsal direction and concave in the radio-ulnar direction. These curvatures place the centre of rotation at the volar-ulnar aspect of the of the trapezio-metacarpal joint.



**Figure 75. The circle represents the centre of rotation of the TM joint (Indian J Plas Surg, 2011)**

Several studies have been done to assess the curvature and congruity of the trapeziometacarpal (TM) joint, such as the studies by Conconi et al (212) and Xu et al (213). These studies found that the male TM joint was significantly more congruous than the female. However, this variation in congruity can again be accounted for by joint size and a linear relationship was found between joint size and congruity. The trapezium and metacarpal are larger in men, therefore leading to a more congruous joint.

There is conflicting evidence regarding whether the actual joint curvatures in men and women are significantly different. The study by Schneider et al found no differences in shape of the bones between the genders in healthy adults (210). The study by Marquez et al also suggest no significant difference exists in the curvatures (214). In contrast to these studies are the findings by Ateshian et al, stating that the metacarpal surface of the trapezium has different curvature characteristics between males and females which are independent of changes due to size. However this study uses specimens with OA stages I,II and III which could be a confounding the results (215). The study by Xu et al also found gender differences in the joint curvatures (213) and thinner cartilage, up to 20% thinner in women than men. The authors explain that the decreased congruity and thinner cartilage results in less contact surface between the trapezium and metacarpal and

therefore greater load through the joint for a given activity. This may be an important biomechanical factor in the aetiology of the female predominance of the disease.

Apart from gender differences, differences related to ethnicity have also been described in the trapeziometacarpal joint curvatures. Although not strictly quantified, by observation, the concavity in the radio-ulnar direction was described to have a greater radius of curvature in Asian trapeziums than Caucasian ones. The Asian trapeziums were flatter and contained a more gentle slope (216). The study by Marzke confirms this observation as higher dorso-volar curvatures of the metacarpal and trapezium was found in European populations compared to Asian, African and indigenous Australian populations (214). Both authors hypothesize whether the difference in joint curvature relates to the differences in prevalence of OA seen between ethnic populations: A higher prevalence in Europeans and a lower one in Asians.

A further prominent feature of the trapezium is deep a groove on the volar surface to house the flexor carpi radialis (FCR) tendon as it passes to insert at the base of the 2<sup>nd</sup> metacarpal. Other functional anatomy include articular facets present ulnarly for the second metacarpal and the trapezoid and inferiorly for the scaphoid.

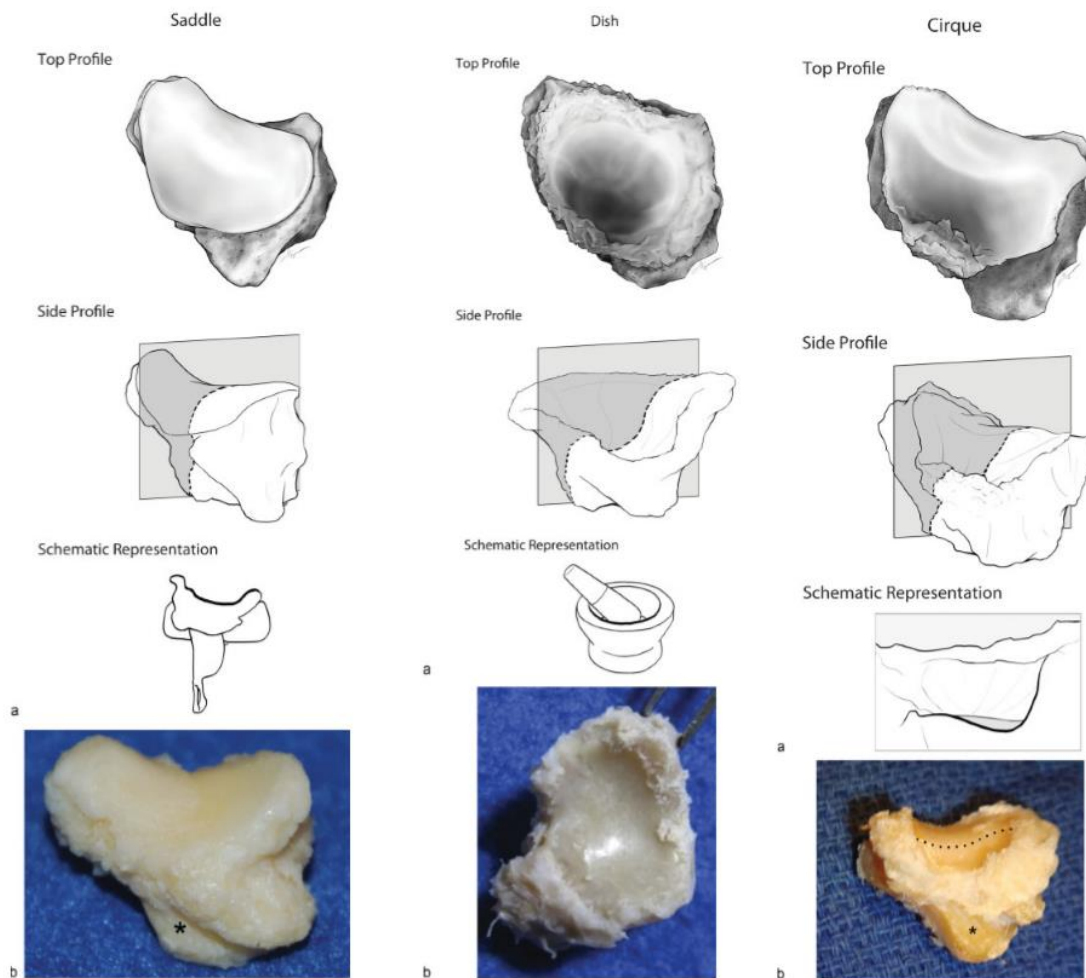
### *The osteoarthritic trapezium*

The morphology of the osteoarthritic trapezium varies to that of a healthy trapezium. The most striking changes are seen in severe stages of arthritis. With advancing OA, a decrease in trapezial height, an increased thickness in subchondral bone, osteophyte formation, thinning of the articular cartilage and dorso-radial subluxation of the metacarpal are seen (217).

The study by Van Nortwick et al (218) describe three distinctive trapezial morphologies which result from osteoarthritic wear: Saddle, dish and cirque shapes. The saddle shaped wear pattern preserves the convexities and concavities of a healthy trapezium with preferential radial and volar wear. The saddle shaped trapeziums were found to have the least severe stage of OA,



predominantly stage II, prior to trapeziectomy. There was also a male predominance (6 out of total 9) toward a saddle wear pattern. The dish shaped trapezium was characterized by complete eburnation of the trapezium metacarpal surface, and concavity in the radio-ulnar as well as dorso-volar directions. Circumferential rimming osteophytes were also a feature. The dish shaped morphology was seen mainly in female specimens (11 out of 12) and had the most severe staging of OA, predominantly stage III and IV, prior to trapeziectomy. Finally, the cirque shaped morphology was distinguished by a 'concave volar slope' with the presence of a volar osteophytes. There was again a female predominance (6 out of 7) with this wear pattern and a majority of specimens were stage III. The authors hypothesise whether the wear patterns observed represent divergent wear from the native saddle shape or represent a continuum of progression from saddle to cirque to dish shape. These observed patterns are consistent with the study done by Pellegrini et al (219), who also found preferential volar wear of the trapezium which is described as starting with a precursor lesion "chondromalacia" which then progresses to eburnation, where all cartilage is lost and the joint surface assumes a polished appearance due to wear. Interestingly dorsal wear progressing to eburnation was predominant in the male specimens. Both of the descriptive observational anatomical studies show gender differences in the wear patterns.



**Figure 76. The different wear patterns of the trapezium (Van Nortwisk, J Wrist Surge, 2013) (218). The ‘saddle’ shape wear pattern is represented in the left column, the ‘dish’ shape centrally and the ‘cirque’ on the right column. The top 2 rows show a schematic representation of each wear patten from superior view and lateral view. In the lateral view the trapezium is divided into radial and ulnar sections. The 3<sup>rd</sup> row of images are cartoon representations of the objects used to describe the trapezial morphology. The final row are human trapeziums which have been removed surgically.**

The study by Xu et al (213) found the dorso-radial, volar-radial and volar-ulnar surfaces of the trapezium had a higher grade of cartilage wear than the dorsal-ulnar surface. These regions correspond to area of the joint deemed as high load bearing. This study also found that the curvatures of the trapezium became less convex and more concave with age and progression of OA. The changes are most pronounced in the end stages of disease and results in a more congruent joint. Although congruity is increased in an osteoarthritic joint this did not result in a greater contact area between the trapezium and metacarpal and less load through the joint, as

would be expected. This finding is explained by osteoarthritic joints possessing thinner layers of articular cartilage. The thinner cartilage accommodates less and provides less deformation under the same load which results in less surface area of contact. The opposing effects on area of contact, with increased congruity and thinner articular cartilage results in similar load being transmitted across an osteoarthritic joint as compared to a healthy one. Radiologically the increased congruence and thinner cartilage can be observed as joint space narrowing.

Dorsal subluxation of the first metacarpal is a frequent finding in base of thumb OA. However, a degree of subluxation or “overhang” of the metacarpal in relation to the trapezium is physiological as the articular surface of the metacarpal is 33% larger than that of the trapezium. The study by Rust et al investigating the alignment of non-arthritic trapeziometacarpal joints found that increasing subluxation occurs with aging (220). Even in healthy individuals, with no radiological or clinical features of OA, a significant difference was found in the degree of subluxation in the dorso-radial direction in the group of patients aged 46 and over than the younger group. The study by Kurosawa measures the angles associated with increasing subluxation of the metacarpal. An increase in the facet angle as well as the dorsal subluxation angle is seen with advancing OA (221). The subluxation of the joint alters the transmission of load through the joint with increased stress distribution in the radial compartment. The study by Nufer et al found increased trabecular density and connectivity in the radial third of osteoarthritic trapeziums with radial subluxation compared to normal healthy trapeziums. The authors conclude the changes in bone are adaptations to shift in stress distribution (217).

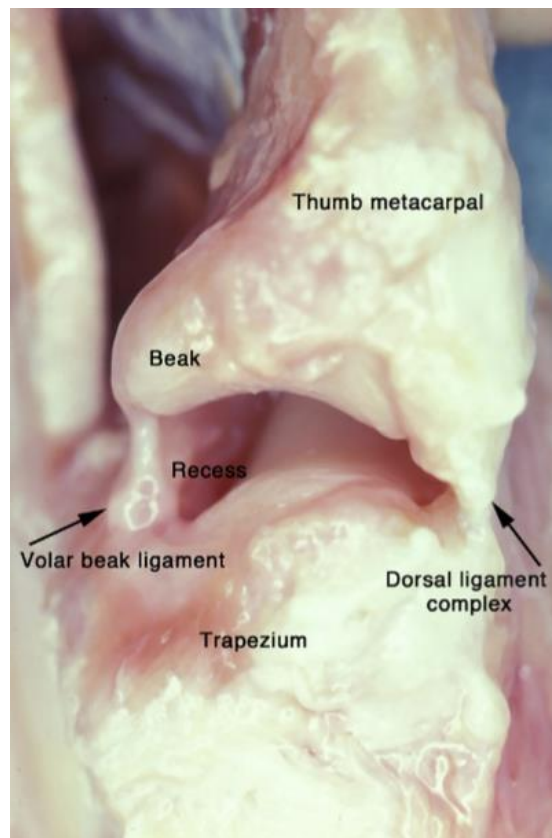
The variation in anatomy of the trapeziums between individuals, due to age, gender, ethnicity, as well as the morphological changes which take place as a result of OA are important factors when considering implant design and supports the premise individualisation of implants such as with a 3D printed trapezium is ideal.

## Biomechanics: forces and stability

### *Bony stability*

Mobility and stability are opposing concepts which are inversely proportional to one another. The biconcavo-convex or saddle shape of the TM joint has two reciprocal saddles which interlock perpendicularly. Therefore, in a resting position (without opposition) it lacks stability, is relatively lax and only loosely congruous. This arrangement allows for a broad range of movement in multiple planes including flexion-extension, abduction, adduction, rotation and circumduction. However, as the joint undergoes opposition a 'cork-screw' like twisting motion takes place which pulls the surrounding ligamentous structures taut and increases joint congruity. At the limits of opposition, the joint is tightly congruous and stable which allows for a strong and stable pinch and grip.

Activation of the thenar musculature provides rotational torque to compress the joint to opposition and increase congruity. Abductor pollicis brevis abducts the thumb, while opponens pollicis provides rotation to allow flexor pollicis brevis, flexor pollicis longus and adductor pollicis to further compress the joint. Much of the increase in bony congruity achieved through joint compression is conferred by the volar 'beak' of the metacarpal engaging with the trapezial recess. This then acts as a pivot point. The primary stabilising ligament which tightens is the dorsal ligament complex. In the final phases of opposition, the dorsal ligament complex becomes oblique and tense. The net effect of opposition (joint compression, insertion of volar beak into trapezial recess and tightening of the dorsal ligament complex) transforms an incongruous and unstable joint into a congruous and rigidly stable one (222)



**Figure 77. The loosely congruous resting TM joint with supporting ligament structures (Edmunds, J Hand Surg Am, 2011) (222).**

*Ligamentous stability*

The three main supporting ligaments of the TM joint are the dorsal ligament complex, the volar beak ligament, and the intermetacarpal ligament (figure 77).

The dorsal ligament complex consists of sub-ligaments composed of the dorsal radial and posterior oblique. The ligament complex takes origin at the trapezium and inserts into the radial base of the thumb below the insertion of the APL tendon. As described above, in the final phases of opposition which is required for a stable power and pinch grip, tightening of the dorsal ligament complex prevents subluxation of the volar beak from the trapezium. It is the single most important ligamentous joint stabiliser and prevents dorsal subluxation and dislocation of the joint. If the dorsal ligament complex is completely disrupted the TM joint will dislocate even if the volar beak ligament remains intact (222).

The volar beak ligament in comparison is weak and has less structural integrity (223). It has been identified by several names by different authors appointing differing levels of significance. The same structure has been identified as the palmar beak ligament (224), the anterior oblique ligament (225), the volar ligament and the ulnar ligament. This ligament remains lax in the resting position of the thumb as well as during opposition, and therefore does not play a major stabilising role to the joint. The ligament however is pulled taut and prevents dorsal subluxation of the thumb during extension or in the 'hitchhikers' position (222). It was proposed by Pellegrini that degeneration of the ligament was crucial in the pathogenesis of developing base of thumb OA, however this belief has been rebutted by others as the ligament is often a thin attenuated structure which does not confer significant stability to the TM joint (222).

The intermetacarpal ligament traverses between the thumb and index finger metacarpal and prevents complete dislocation of the 1<sup>st</sup> metacarpal if the volar and dorsal ligaments are cut or torn. During ligament reconstruction procedures such as using APL, it is the function of the inter metacarpal ligament which is reinforced between the 1<sup>st</sup> and 2<sup>nd</sup> metacarpals (222).

### Forces

The above paragraphs establish that the TM joint is lax and unstable in all but the final phases of thumb opposition, and relies on ligamentous support for stability. Once the joint is in final phases of opposition, as is the requirement for pinch and power grip, it is stable due to tightening of the dorsal ligament complex and increased bony congruity by means of the metacarpal beak engaging with the trapezial recess. This acts as the pivot point where maximal load transmission occurs. Because it is a relatively small area, like a stiletto heel, even small forces are magnified thus subjecting the joint to large amounts of pressure. Cooney et al found through mathematical modelling that forces at the finger tips in lateral pinch were multiplied by 12-fold at the joint (226).

## Pressure = Force / Surface area



**Figure 78. Pressure equation (Force per unit area). Arrows point to areas of maximal force transmission; stiletto heel (left) (pinterest.com, 17<sup>th</sup> January 2019) and metacarpal beak (right) (Edmunds, J Hand Surg Am, 2011)**

Keeping with the analogy of the stiletto, if stood on, it is the unsuspecting bystander's foot which gets damaged. Similarly, the pressure transmitted through the volar beak of the metacarpal over many decades has the same damaging effect on the trapezium, in particular the trapezial recess. This notion is supported by anatomical findings which show preferential volar wear of the trapezium in early OA i.e. the vicinity of the trapezial recess (222, 224). Furthermore, the surgical technique of performing an extension osteotomy on the metacarpal is destined to re-distribute load away from the already worn volar-radial surface towards the dorsal-ulnar surface which still has preserved cartilage. This is certainly an important biomechanical factor contributing to the pathogenesis of base of thumb OA.

In summary, trapezial morphology between individuals is largely similar, however some variation exists depending on gender, ethnicity and stage of OA. The TM joint in a resting position is non-congruous and relies on ligaments, particularly the dorsal ligament complex for stability to prevent

dislocation. Finally, the TM joint has a relatively small area of load bearing, therefore is subject to high forces over time believed to play a role in the development of base of thumb OA.

### Anatomical study of the trapezium and carpal bone size

An anatomical study of the trapezium was done to guide correct implant sizing. Precise sizing of an implant is crucial to its stability. Under and oversizing has previously been shown to lead to dislocation or subluxation of the implant. Although a 3D printed trapezium is morphologically identical to a native one, correct sizing still remains a priority. An ideal method of sizing the implant would be to create a bespoke implant using the patient's own pre-operative imaging. However, in many circumstances this may not be possible, appropriate or practical. Therefore, an implant with standard sizing may instead be required. Possible scenarios may include, if the patient's own trapezium is not available or appropriate to create a bespoke implant, such as in cases of severe OA where the trapezium morphology is significantly altered or in cases of failed trapeziectomy where no pre-operative imaging is available. Furthermore, in bilateral cases of base of thumb OA, the contralateral hand cannot be used for sizing for the same reason.

From the discussion above, trapezium anatomy varies with gender in relation to size. However, further investigation of other demographic factors which may influence trapezium size should ideally be undertaken for optimal sizing. Thus, an anatomical study of the trapezium and carpal bone size was conducted to determine variation in trapezium size, and normalised trapezium size according to gender, age and stage of osteoarthritis. The CT and cadaveric study by Loisel et al investigating trapezium anatomy found there may be correlations between trapezium size and other local anatomy such as width of radial epiphysis and forearm length (209). To further build on this concept, the size (in volume) of all other carpal bones was derived to determine if any correlation exists between the size of other carpal bones and trapezium size. A further advantage of determining whole carpal



volume is the percentage volume of the trapezium can be determined, which again can be used to estimate the appropriate volume of the implant to fill the trapezoidal space.

## Methods

A cross-sectional anatomical CT based study of the trapezium was done with ethics approval granted for the use of anonymised CT wrist scans through Peninsula Health Low Risk Ethics Committee. The studies were performed at a single institution, Frankston Public Hospital, and the data was entirely collected by DG.

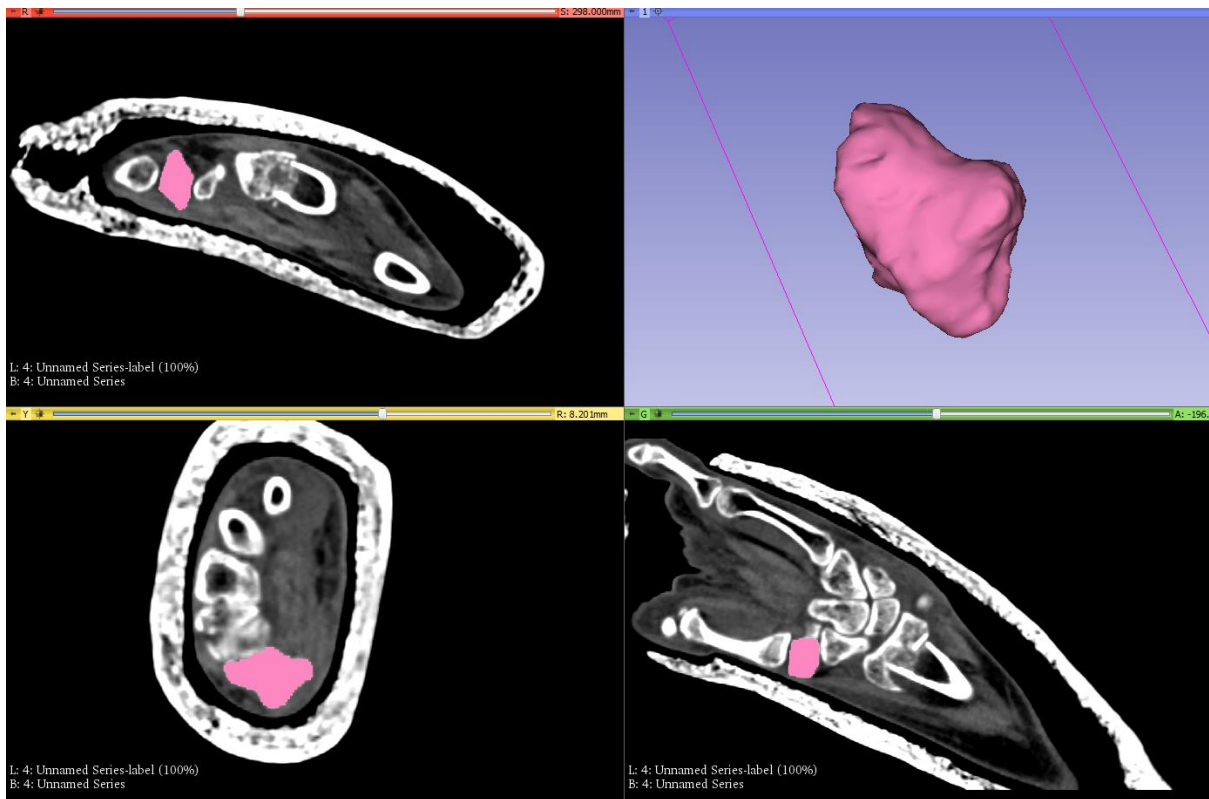
### *CT wrist selection*

60 CT wrist scans with resolution 0.5-1mm thick slices were obtained from the Frankston hospital radiology department. The scans were anonymised of any identifying detail. Scans which did not image the whole carpus, contained metalware or evidence of avascular necrosis of any carpal bone were excluded. Demographic details (age and gender), side of scan (left or right), clinical reason for CT scan and Eaton-Littler stage of OA using sagittal views were recorded for each scan. Stage I OA was recorded if no evidence of OA seen.

### *Evaluation of trapezium and carpal bone size*

The volume and surface area were derived for each carpal bone, including the trapezium, by creating 3D surface models (480 surface models in total) using *3D slicer* through a process of automated and manual segmentation as described in chapter 3. The process of creating surface models on 3D slicer using CT images was separately validated (chapter 3, validation studies), therefore 3D slicer provides accurate volumetric analysis and is not subject to user variability when creating surface models of the carpal bones. The

normalised volume of the trapezium was calculated for each scan as a percentage volume of the trapezium from the total volume of the carpus.



**Figure 79. Label map of CT wrist and 3D surface model of trapezium created on 3D slicer.**

#### *Other data sets:*

Further data sets investigating carpal bone volume were obtained through collaboration with research groups from Brown University (211) (Providence, Rhode Island, USA) and Auckland University (210) (Auckland, New Zealand). The main purpose of collecting additional data sets were to increase numbers in the study and also provide a more comprehensive data base of trapezial and carpal bone volume.

The data set from Brown university contained the volumes of all carpal bones from 60, young (age <30 years) and healthy individuals, without evidence of base of thumb OA. Results from this data set have been previously published in the paper “A digital database of wrist bone anatomy and carpal kinematics” which the authors specifically created and

made available for collaboration among different research groups. Volumes were again derived from CT images through segmentation and creating surface models(227).

The data set from Auckland University too has previously been published (210) however has not previously been made available for collaboration. This data set contained only the volumes of the trapezium from 61 individuals without base of thumb OA. The volumes were again derived using CT images and segmentation.

### *Statistical analysis:*

#### *Distribution of data*

Statistical analysis was done by using Stata v14 courtesy of Dr. Vicky Tobin. Distribution of each data set (Peninsula health, Brown university, and Auckland University) was assessed for normality using the Shapiro-Wilk test.

#### *Age*

Spearman correlation test was done to determine any significant correlation between carpal bone size and age. Furthermore, the population was divided into two (<40 years, >40 years) and three (<30, 31-60,>61 years) age categories significant differences in trapezium volume in different age categories were determined using the Kruskal-Wallis test.

#### *Gender*

The population was divided by gender and significant differences in carpal size were determined using the Wilcoxon-Mann-Whitney test.

### Eaton stage of OA

Comparison of trapezial size by Eaton stage of OA (I, II, III, IV) was determined using an ANOVA including only the dataset from Peninsula health as the other sets did not contain any osteoarthritic trapezia.

### Relationship of trapezial volume to local anatomy

Multiple linear regression analysis was conducted using the 7 remaining carpal bone volumes (Table 16) as the independent variables and the trapezium volume as the dependent variable. The data used was from the Peninsula health data set using 50 CT wrists. Once all independent variables which were not significant were excluded ( $P < 0.05$ ) further single linear regression was conducted with the single most significant independent variable.

## Results

### Demographics Peninsula Health

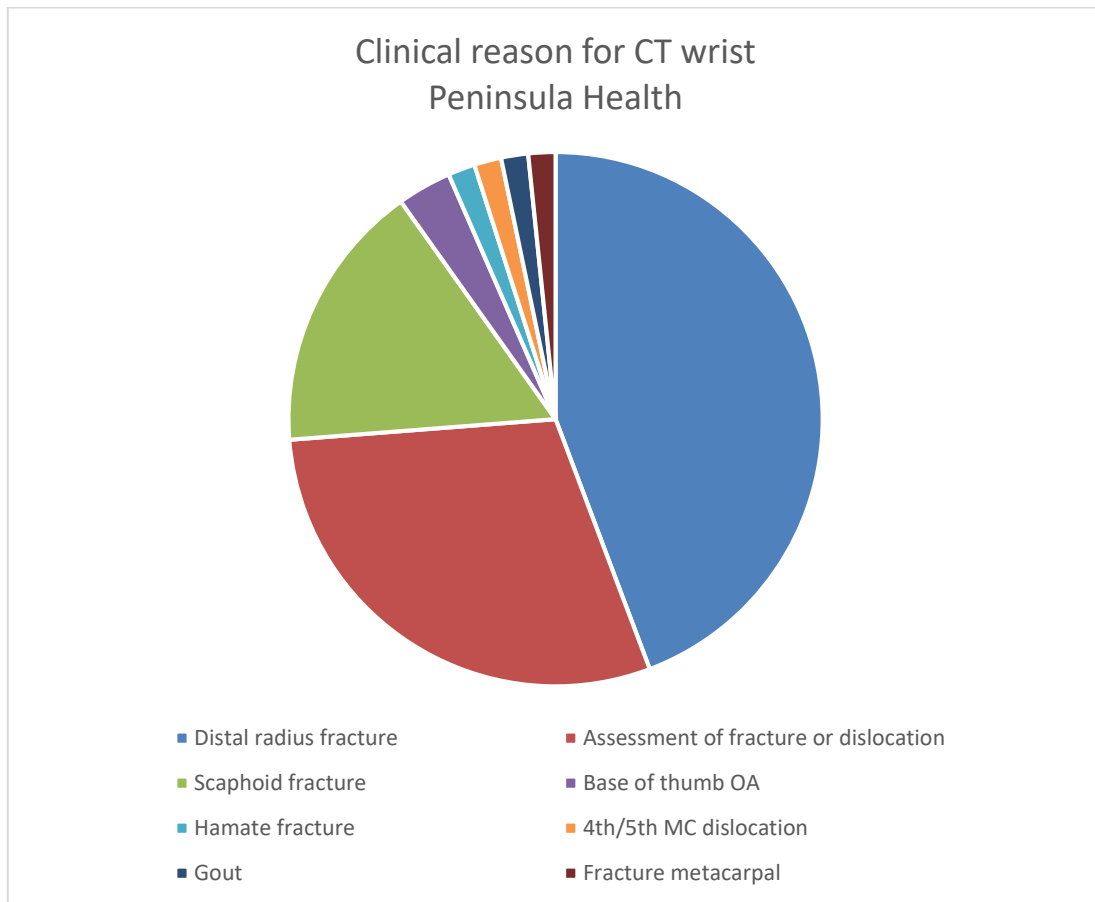
A total of 60 CT scans were included in the study, 47% (28/60) were of female patients. The mean age of the patients at the time of the scans were 51.2 years. The mean age of female patients in the study was 59.5 years. The mean age of male patients in the study was 43.9 years.

<i>Demographic</i>	<i>Female</i>	<i>Male</i>	<i>Total</i>
<i>N</i>	<i>28</i>	<i>32</i>	<i>60</i>
<i>Mean age</i>	<i>59.5</i>	<i>43.9</i>	<i>51.2</i>

**Table 24. Basic demographics of the population by age and gender**

The clinical reason for the CT scans were fracture distal radius (27), fracture metacarpal (1), fracture scaphoid (10), base of thumb OA (2), fracture hamate (1), dislocation of 4/5<sup>th</sup>

MC (1), gout (1), and assessment of fracture or dislocation (18). The scans were performed in the right hand 77% (46/60) of the time.



**Figure 80. Clinical reason for CT wrists in the Peninsula health population**

Greater proportion of patients (61%) with early stages of OA (stage I/II ) were male.

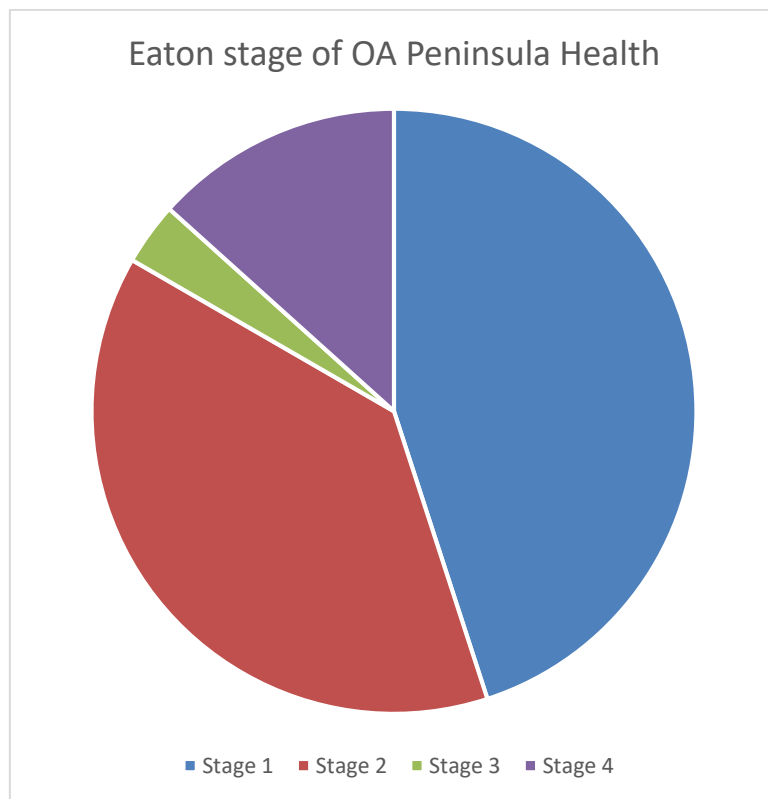
Greater proportion of patients (89%) with severe (stage III/IV) OA were female.

The mean age of patients with stage I/II OA was 43.3 years, and mean age of patients with stage III/IV OA was 77.2 years. The average Eaton stage for patients under age of 40 years (N=21) was 1.3, and over the age of 40 years (N=39) was 2.13.

The mean Eaton-Littler stage of OA was 1.85. The mean Eaton stage of OA for female patients (2.32) was greater than the average Eaton stage of OA for male patients (1.44).

<i>N=60</i>	<i>Stage I</i>	<i>Stage II</i>	<i>Stage III</i>	<i>Stage IV</i>
<i>N</i>	27	23	2	8
<i>%</i>	45	38.3	3.3	13.3

**Table 25. Number and percentage of total peninsula health population by stage of OA**



**Figure 81. Proportion of patients with each Eaton stage of OA**

*Demographics Brown University*

The data set was composed of 60 patients, 50% of the population were female. The mean age of the patients were 24.7 years. Mean age of the female patients were 24.4 years, and mean age of the male patients were 25 years. Age demographic was not available for 20 of the patients.

<i>Demographic</i>	<i>Female</i>	<i>Male</i>	<i>Total</i>
<i>N</i>	30	30	60
<i>Mean age</i>	24.4	25.0	24.7

**Table 26. Basic demographics of the Brown university population by age and gender**

The clinical reason for imaging all subjects were for study and research purposes. All subjects were healthy without any base of thumb OA, for the purposes of the study was classified as Eaton stage 1.

<i>N=60</i>	<i>Stage I</i>	<i>Stage II</i>	<i>Stage III</i>	<i>Stage IV</i>
<i>N</i>	60	0	0	0
<i>%</i>	100	0	0	0

**Table 27. Number and percentage of population by stage of OA**

#### *Demographics Auckland University*

The data set from Auckland university contained 61 patients, 52.5% (32/61) were female.

The mean age of the female patients were 42.8 years, and the mean age of the male patients were 40.3 years.

<i>Demographic</i>	<i>Female</i>	<i>Male</i>	<i>Total</i>
<i>N</i>	32	31	61
<i>Mean age</i>	42.8	40.3	41.6

**Table 28. Basic demographics of the Auckland university population by age and gender**

The imaging was again done for research purposes and all patients were healthy without any evidence of base of thumb OA.

<i>N=61</i>	<i>Stage I</i>	<i>Stage II</i>	<i>Stage III</i>	<i>Stage IV</i>
<i>N</i>	<i>60</i>	<i>0</i>	<i>0</i>	<i>0</i>
<i>%</i>	<i>100</i>	<i>0</i>	<i>0</i>	<i>0</i>

**Table 29. Number and percentage of population by stage of OA**

The data sets from Peninsular Health and Auckland University were normally distributed ( $P=0.153$  and  $P=0.188$  respectively), however the data from Brown University was not normally distributed (Shapiro-Wilk test 0.00129) therefore combined data set analysis was done using non-parametric tests.

#### *Gender*

On average, the absolute volume of the male carpal bones were 30-35% bigger than female carpal bones. The difference in size was statistically significant for all carpal bones.

<i>Median carpal bone volume (mm<sup>3</sup>)</i>	<i>Female</i>	<i>Male</i>	<i>Mean difference</i>	<i>% difference (female/male)</i>	<i>Significant difference (P&lt;0.05)</i>
<i>Trapezium</i>	<i>1679.52</i>	<i>2462.5</i>	<i>782.98</i>	<i>68.20%</i>	<i>≤ 0.01</i>
<i>Scaphoid</i>	<i>2024.73</i>	<i>3001.76</i>	<i>977.03</i>	<i>67.45%</i>	<i>≤ 0.01</i>
<i>Lunate</i>	<i>1441.03</i>	<i>2222.07</i>	<i>781.04</i>	<i>64.85%</i>	<i>≤ 0.01</i>
<i>Triquetrum</i>	<i>1165.19</i>	<i>1666.71</i>	<i>501.52</i>	<i>69.91%</i>	<i>≤ 0.01</i>
<i>Pisiform</i>	<i>601.81</i>	<i>866.385</i>	<i>264.575</i>	<i>69.46%</i>	<i>≤ 0.01</i>
<i>Trapezoid</i>	<i>1050.44</i>	<i>1506.1</i>	<i>455.66</i>	<i>69.75%</i>	<i>≤ 0.01</i>
<i>Capitate</i>	<i>2699.965</i>	<i>3915.48</i>	<i>1215.515</i>	<i>68.96%</i>	<i>≤ 0.01</i>
<i>Hamate</i>	<i>2062.26</i>	<i>3029.79</i>	<i>967.53</i>	<i>68.07%</i>	<i>≤ 0.01</i>
<i>Total carpus</i>	<i>12901.99</i>	<i>18719.64</i>	<i>5817.65</i>	<i>68.92%</i>	<i>≤ 0.01</i>

**Table 30. Gender differences in carpal bone volume (Data sets from Peninsula Health and Brown University)**



On average the percentage volume of the trapezium which occupied of the net volume of the carpus did not significantly vary between the genders ( $P>0.05$ ).

<i>Mean % carpal bone volume-Female</i>	<b><i>Eaton stage of OA</i></b>		
	<i>Stage 1</i>	<i>Stage 2</i>	<i>Stage 3/4</i>
<i>Trapezium</i>	12.43%	13.24%	17.11%
<i>Scaphoid</i>	16.20%	15.63%	14.52%
<i>Lunate</i>	11.34%	11.13%	11.76%
<i>Triquetrum</i>	9.13%	9.58%	9.39%
<i>Pisiform</i>	4.77%	5.22%	5.11%
<i>Trapezoid</i>	8.70%	8.92%	8.70%
<i>Capitate</i>	21.10%	20.30%	19.09%
<i>Hamate</i>	16.93%	15.98%	14.32%
<i>Total carpus</i>	100%	100%	100%

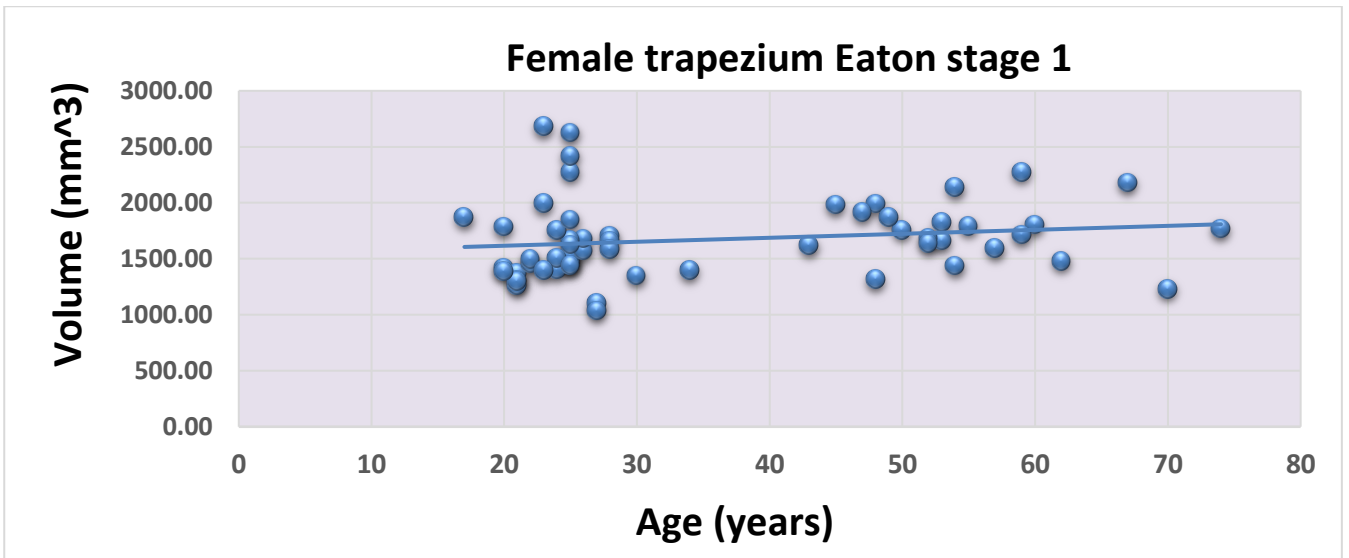
**Table 31. Mean percentage volume of each carpal bone with respect to the net volume of the carpus by female gender and stage of Eaton**

<i>Mean % carpal bone volume-Male</i>	<b><i>Eaton stage of OA</i></b>		
	<i>Stage 1</i>	<i>Stage 2</i>	<i>Stage 3/4</i>
<b><i>Trapezium</i></b>	<b><i>12.61%</i></b>	<b><i>13.10%</i></b>	<b><i>16.69%</i></b>
<i>Scaphoid</i>	<i>16.26%</i>	<i>16.56%</i>	<i>14.77%</i>
<i>Lunate</i>	<i>11.97%</i>	<i>11.95%</i>	<i>10.02%</i>
<i>Triquetrum</i>	<i>9.01%</i>	<i>8.75%</i>	<i>8.41%</i>
<i>Pisiform</i>	<i>4.83%</i>	<i>4.86%</i>	<i>5.39%</i>
<i>Trapezoid</i>	<i>8.20%</i>	<i>15.73%</i>	<i>8.35%</i>
<i>Capitate</i>	<i>20.78%</i>	<i>20.85%</i>	<i>18.35%</i>
<i>Hamate</i>	<i>16.51%</i>	<i>8.21%</i>	<i>18.02%</i>
<i>Total carpus</i>	<i>100%</i>	<i>100%</i>	<i>100%</i>

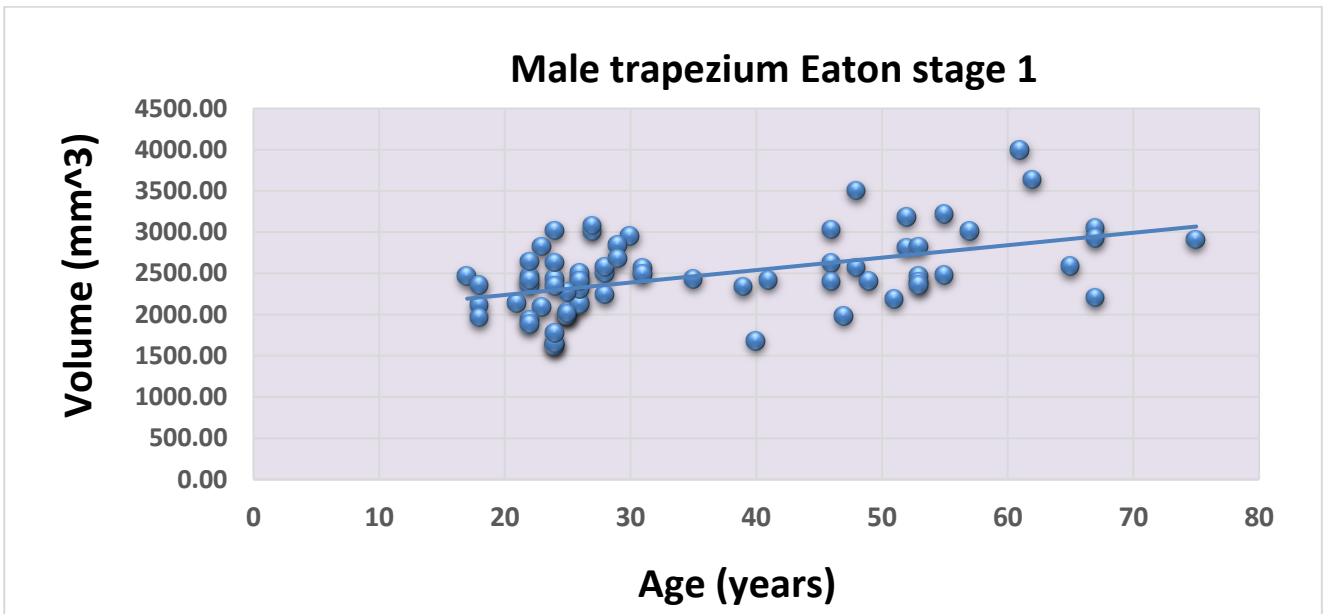
**Table 32. Mean percentage volume of each carpal bone with respect to the net volume of the carpus by male gender and stage of Eaton**

*Age*

The Spearman-correlation between age and Eaton stage 1 trapezium was statistically non-significant for female gender ( $p=0.052$ ) and statistically significant for male gender ( $p<0.001$ ). The Spearman-correlation between age and Eaton all stages of Eaton trapezium was statistically significant for both female gender ( $p<0.001$ ) and male gender ( $p<0.001$ )



**Figure 82. Scatter-plot showing correlation between age and Eaton stage 1 trapezium in female gender**



**Figure 83. Scatter-plot showing correlation between age and Eaton stage 1 trapezium in male gender**

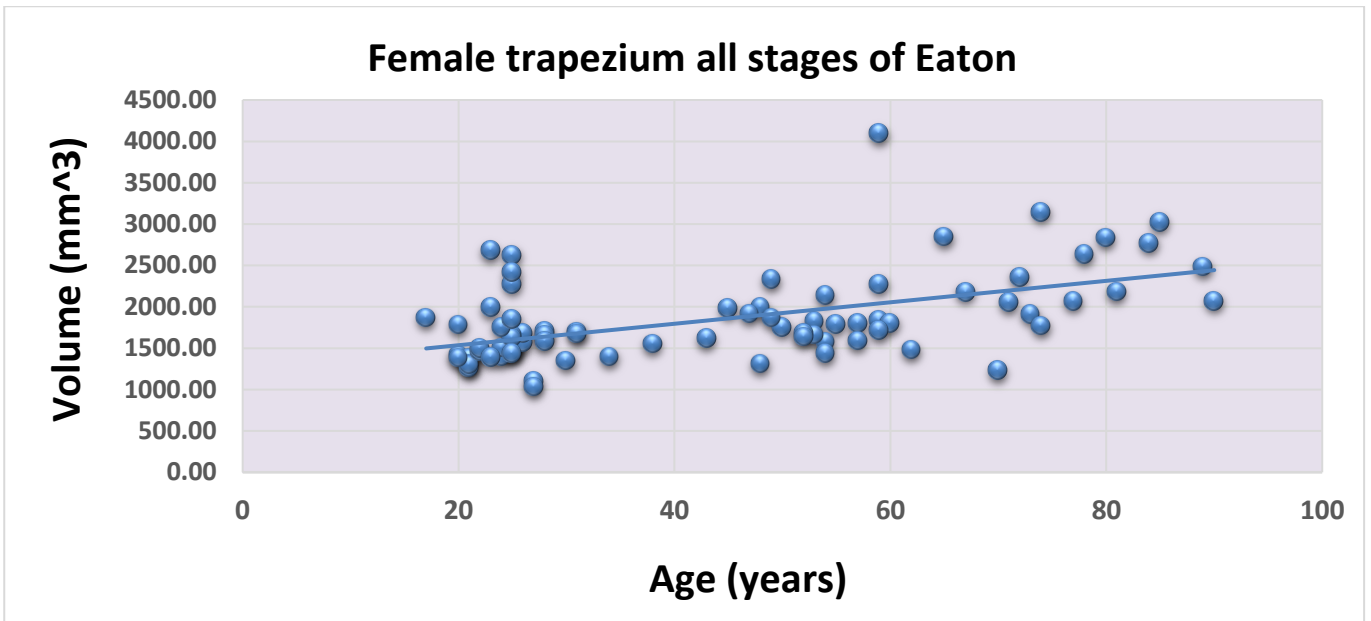


Figure 84. Scatter-plot showing correlation between age and trapezium volume in all stages of Eaton, in female gender

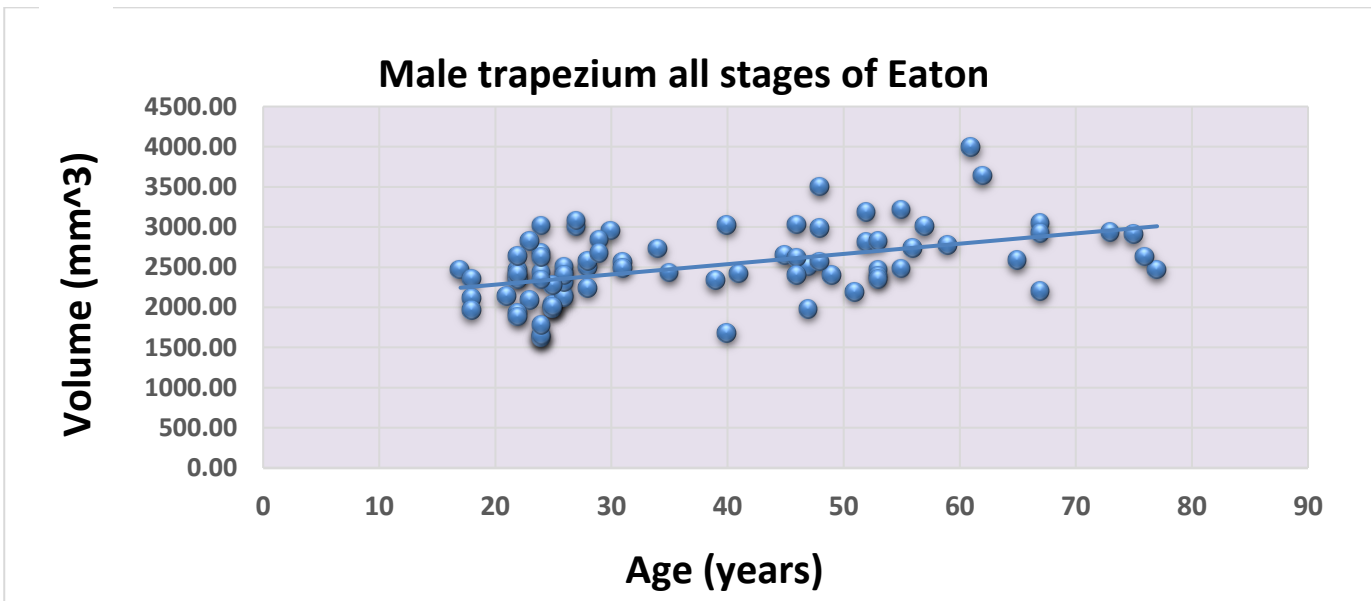


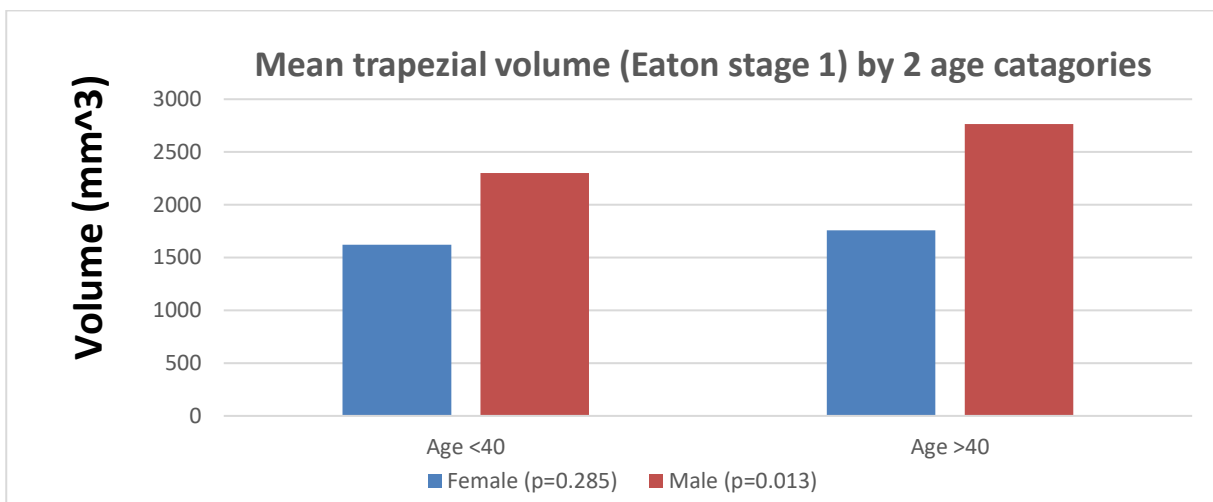
Figure 85. Scatter-plot showing correlation between age and trapezium volume in all stages of Eaton, in male gender

The mean difference in trapezium volume in age groups under 40 years and above 40 years was not statistically significant for females with Eaton stage 1 trapezium. However, there was a significant difference when age was divided into 3 categories. The mean difference in trapezium

volume in all stages of Eaton when comparing 2 (<40, >40 years) or 3 (<30, 31-60, >60 years) age categories was statistically significant for both genders.

Mean volume of Eaton 1 trapezium (mm <sup>3</sup> )	Age <40	Age>40	Kruskal-Wallis test (p-value)
Female	1621.14	1758.07	P=0.285
Male	2300.69	2765.67	P=0.013

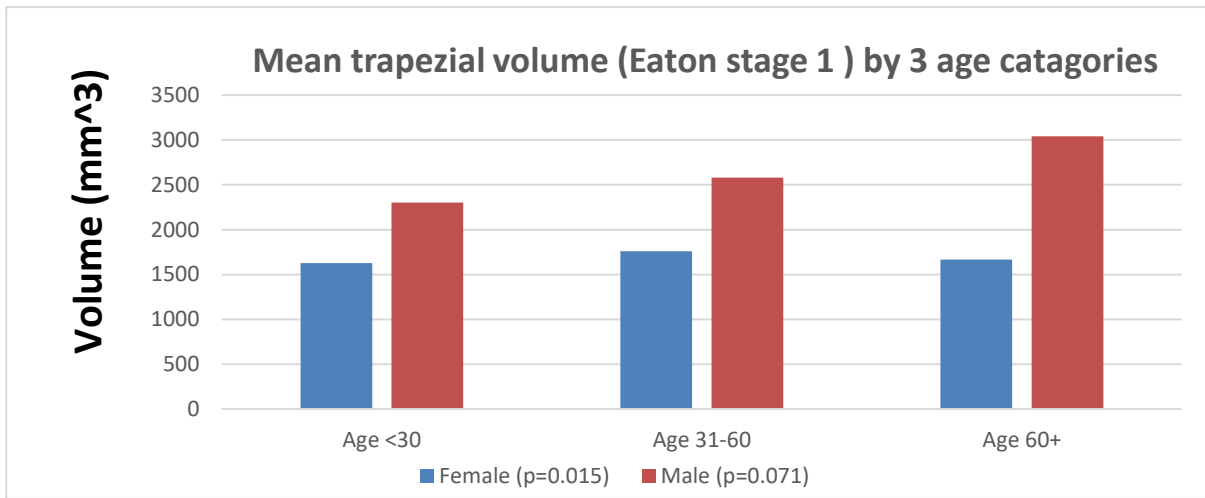
**Table 33. Difference in mean volume of Eaton 1 trapezium by gender in patients aged <40 years and > than 40 years.**



**Figure 86. Difference in mean volume of Eaton 1 trapezium by gender in patients aged <40 years and > than 40 years.**

Mean volume of Eaton 1 trapezium (mm <sup>3</sup> )	Age <30	Age 31-60	Age 61+	Kruskal-Wallis test (p-value)
Female	1627.49	1758.63	1665.63	P=0.015
Male	2300.87	2580.10	3042.24	P=0.071

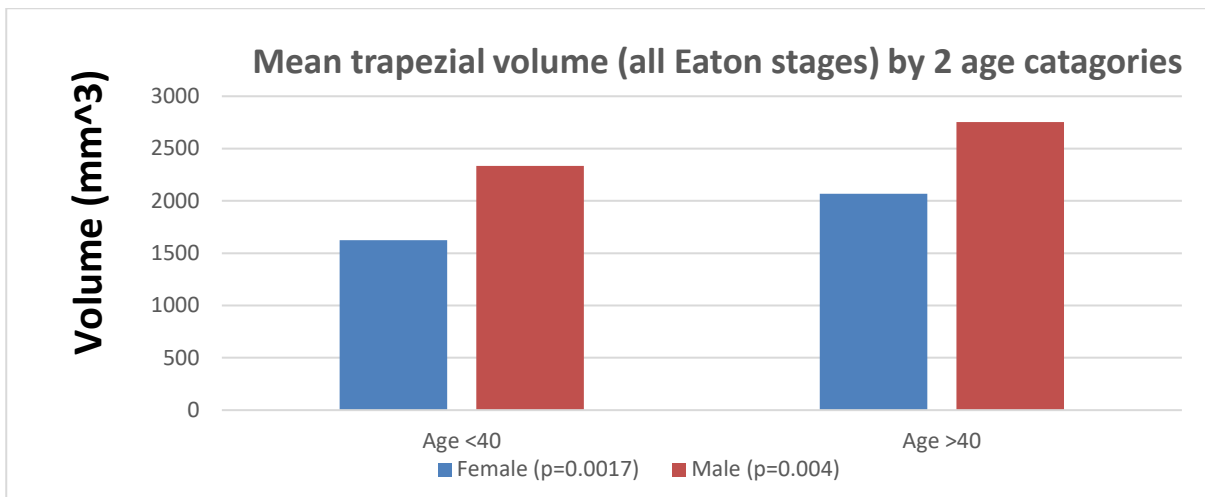
**Table 34. Difference in mean volume in Eaton stage 1 trapezium by gender in patients comparing 3 age categories <30, 31-60 and >61.**



**Figure 87. Difference in mean volume in Eaton stage 1 trapezium by gender in patients comparing 3 age categories <30, 31-60 and >61.**

Mean volume of trapezium all Eaton stages (mm <sup>3</sup> )	Age <40	Age >40	Kruskal-Wallis test (p-value)
Female	1622.83	2068.32	P=0.0017
Male	2334.39	2752.30	P=0.004

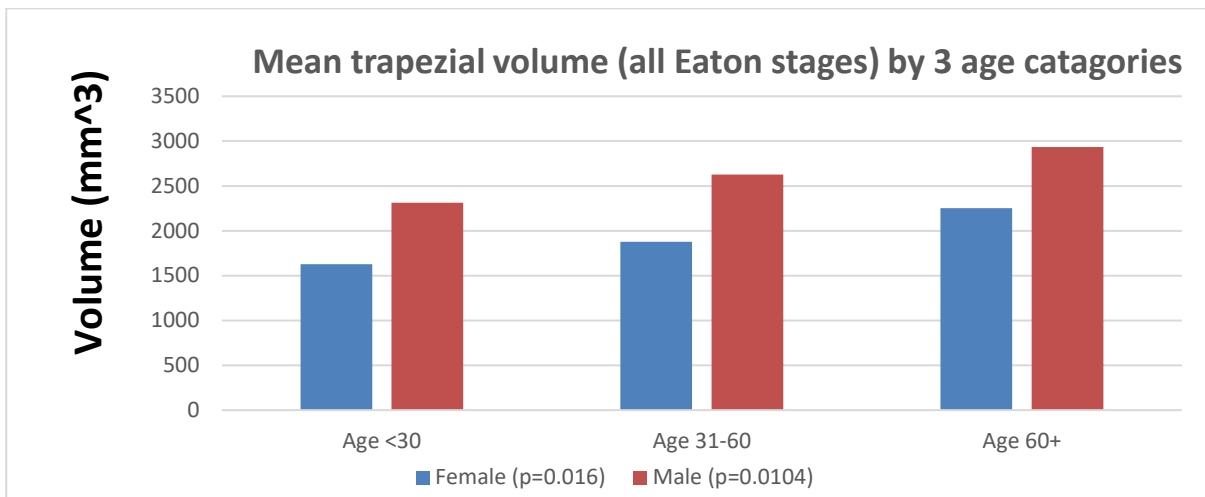
**Table 35. Difference in mean volume of trapezium in all Eaton stages by gender in patients aged <40 years and > than 40 years.**



**Figure 88. Difference in mean volume of trapezium in all Eaton stages by gender in patients aged <40 years and > than 40 years.**

Mean volume of trapezium all Eaton stages (mm <sup>3</sup> )	Age <30	Age 31-60	Age 61+	Kruskal-Wallis test (p-value)
Female	1627.49	1877.63	2252.79	P=0.016
Male	2312.16	2625.13	2932.44	P=0.0104

**Table 36. Difference in mean volume of trapezium in all Eaton stages by gender in patients comparing 3 age categories <30, 31-60 and >61.**



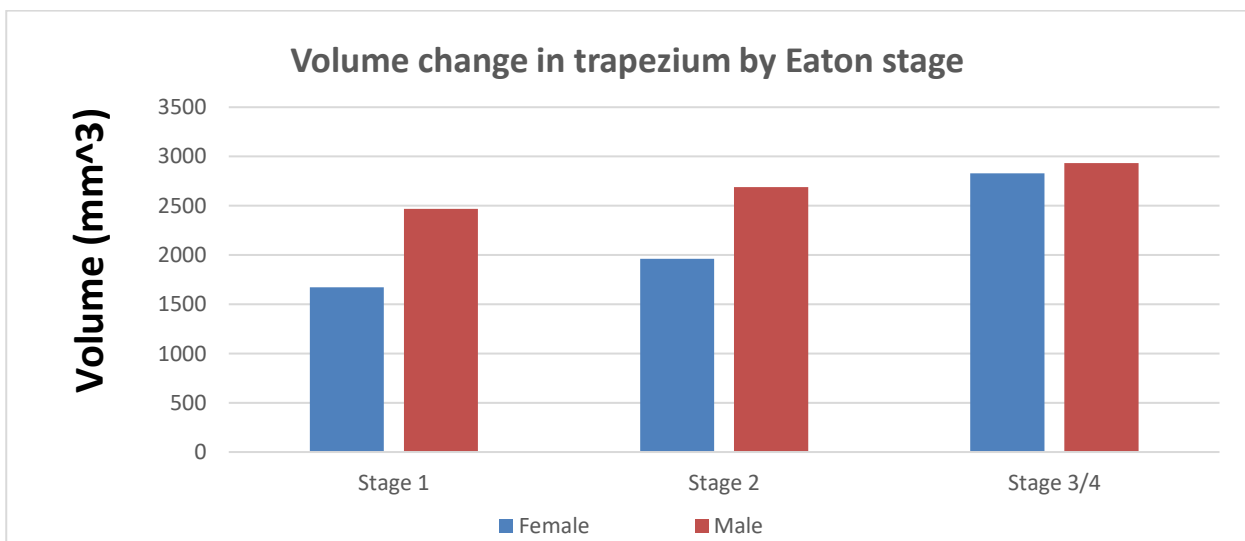
**Figure 89. Difference in mean volume of trapezium in all Eaton stages by gender in patients comparing 3 age categories <30, 31-60 and >61.**

*Eaton stage of OA*

There was a statistically significant difference in the mean trapezium volume between Eaton Stage 1 vs Eaton stage 4 OA ( $p=0.002$ ) and Eaton stage 2 vs Eaton stage 4 ( $p=0.019$ ).

The difference in mean volume of the trapezium between the Eaton stages of OA remained statistically significant post adjustment for variation due to gender ( $p<0001$ ).

The difference in mean volume of the trapezium between the Eaton stages of OA was no longer statistically significant once adjusted for variation due to age ( $p=0.954$ ).





## Figure 90. Difference in mean volume of trapezium by Eaton stage of OA

### *Relationship of trapezium volume to local anatomy*

Multiple linear regression analysis was used to predict the volume of the trapezium modelled on the volume of each carpal bone. The regression model had a high R value (0.85), but only one independent variable, the lunate volume, was found to have a statistically significant relationship with the trapezium volume  $P=0.004$ , all other carpal volumes had a P value  $>0.05$ .

$$\text{Volume trapezium} = 584.665 + (0.0458 * \text{Volume Scaphoid}) + (0.713 * \text{Volume Lunate}) + (0.0263 * \text{Volume Triquetrum}) + (0.390 * \text{Volume Pisiform}) + (0.127 * \text{Volume trapezoid}) - (0.215 * \text{Capitate}) + (0.135 * \text{Volume Hamate})$$

$$R = 0.850$$

$$R^2 = 0.723$$

$$\text{Adjusted } R^2 = 0.675$$

## Figure 91. Multiple linear regression model with all carpal bones included

	<b>Coefficient</b>	<b>Standard Error of Coefficient</b>	<b>P value</b>
<b>Constant</b>	584.665	214.954	0.010
<b>Scaphoid</b>	0.0458	0.0952	0.633
<b>Lunate</b>	0.713	0.232	0.004
<b>Triquetrum</b>	0.0263	0.295	0.929
<b>Pisiform</b>	0.390	0.333	0.248
<b>Trapezoid</b>	0.127	0.203	0.537
<b>Capitate</b>	-0.215	0.174	0.224
<b>Hamate</b>	0.135	0.202	0.507

**Table 37. Multiple linear regression of trapezium volume as explained by each of the other carpal bone volumes**

The independent variable which had a statistically significant relationship with the trapezium volume was lunate volume ( $P=0.004$ ). Therefore, all other independent variables were excluded and single linear regression was conducted between the lunate volume and trapezium volume. This relationship was strongly positive (Pearson's coefficient 0.83) and statistically significant ( $P<0.001$ ). As the gradient coefficient was 0.845, this denotes that the volume of the trapezium increases by  $0.845\text{mm}^3$  for each  $1\text{mm}^3$  increase in the lunate volume. Furthermore, the  $R^2$  of 0.693 denotes that 69.3% of the variation in trapezium volume can be explained by this model which relates only trapezium volume to lunate volume.

$$\text{Volume trapezium} = 628.760 + (0.845 * \text{volume Lunate})$$

$$R = 0.832$$

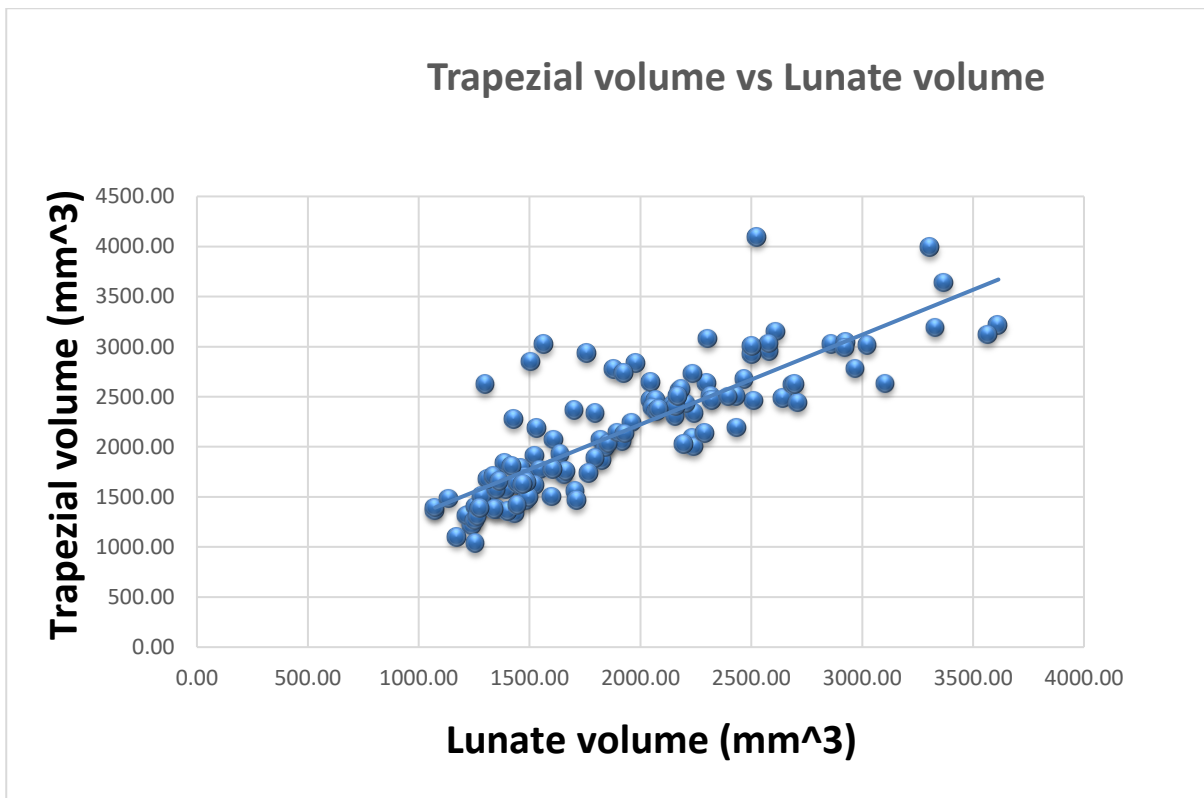
$$R^2 = 0.693$$

$$\text{Adjusted } R^2 = 0.686$$

**Figure 92. Linear regression model using only volume Lunate**

	<b>Coefficient</b>	<b>Standard Error of Coefficient</b>	<b>P value</b>
<b>Constant</b>	628.760	174.813	<0.001
<b>Lunate</b>	0.845	0.0821	<0.001

**Table 38. Linear regression of trapezium volume as explained by the volume of the Lunate**



**Figure 93. Scatter plot showing linear relationship between Lunate volume and trapezoidal volume**

### Discussion

Does size really matter? If it doesn't, it should, if concerning a 3D printed trapezoidal implant. From the previous chapter on implant complications, the main reason for implant failure in the interposition with total trapezoidal resection group was dislocation or subluxation of the implant. As well as lack of implant stability due to an inadequate capsular repair or ligament reconstruction, one of the other causes of dislocation and subluxation was incorrect implant sizing, with either over or under-sizing the implant.

An anatomical study of trapezoidal volume and percentage trapezoidal volume was done to determine differences in trapezoidal size between demographics to guide implant sizing. Furthermore, trapezoidal size as it correlates to other carpal bone volume was investigated to predict the required size of a 3D printed trapezium in cases where the patient's native

trapezium is unavailable or inappropriate to use as a template to create the 3D printed implant.

### *Gender*

The absolute volume of the trapezium in male patients was larger than in female patients. On average, the male trapezium was 32% larger ( $P < 0.05$ ). This finding is consistent with the published literature, and maybe an important biomechanical factor contributing to the female predominance of base of thumb OA, as the articulating surface area would also be larger in the male trapezium. Therefore, per unit surface area more pressure would be transmitted through the female joint on a daily basis. Although the absolute volume showed significant gender differences, the percentage volume the trapezium occupied in the net carpus did not vary between genders. This finding is again consistent with the published literature which support the premise female and male trapezia are merely scaled versions of one another. The main difference relating to size as opposed to morphology (211). In a healthy individual the trapezium occupies on average 12-13% of the net volume of the carpus (Tables 17, 18). This finding is again important in implant sizing as a standard 3D printed trapezium implant could theoretically be scaled up or down in volume to match the required size for the patient regardless of their gender status.

### *Age*

The changes in trapezial and carpal bone volume relating to age are complex due to the confounding effects of OA and female gender. Osteoarthritis is strongly age related as prevalence steadily increases with age over 30 years, and there is a strong female predominance in base of thumb OA. To isolate the effect of age on the trapezium, the data was analysed stratified by gender and Eaton stage 1 OA. With this stratification there was not a statistically significant correlation (Spearman's-correlation test) in trapezial volume

and increasing age in Eaton stage 1 in female gender (Figure 82). However, there was a statistically significant correlation in male gender. The non-significant result in female gender may be due to the small number of elderly female patients without base of thumb OA. A larger sample size maybe have yielded significant results. Interestingly, when all stages of Eaton were included the age-related increase in trapezial volume was statistically significant in both genders (Figure 84 and 85). To further analyse the positive correlation with increasing trapezial volume and increasing age, the data was divided into two and three age categories to find significant differences in means. For both genders, significant differences in mean trapezial volume was found in Eaton stage 1 trapezia when comparing 3 age categories (<30, 31-60, >61). However as this was done using non-parametric tests, no post hoc analysis was possible to pinpoint between which age categories the significant differences exist. The results of table 34 shows the largest volume of the female Eaton stage 1 trapezium in Age 31-60-year-old age category. The smaller volumes in the 60+ category can again be explained by small sample sizes in the 60+ category as majority of females over 60 would have evidence of OA. A larger sample size therefore may have given similar results in the female gender comparable to male gender which shows increasing trapezial volume as age increases. These results raise the possibility that trapezial volume may increase independently with age although there is an interaction with OA. Therefore, implant sizing should ideally take in to account a patient's gender and age.

#### *Eaton stage of OA*

The data used to analyse the effect of Eaton stage of OA on the trapezium contained only the Peninsula health population, as the other data sets contributed only Eaton stage 1 trapezia. Statistically significant difference in trapezial volume was found between Eaton stage 1 and Eaton stage 4, and Eaton stage 2 and Eaton stage 4. These differences in

mean volume remained statistically significant when adjusted for variation due to gender. However, as above there was an interaction between stage of OA and age, and the mean differences were no longer statistically significant when adjusted for variation due to age. Furthermore, the increase in trapezium volume due to stage of OA is most strikingly illustrated when observing the percentage volume of the trapezium increase with the stage of OA (Table 17 and 18). Percentage trapezium volume increases in both genders from ~12-13% of the net carpus to ~17% volume of the net carpus. It is likely the increase in volume is due to development of osteophytes. The advantage of knowing the approximate percentage volume of the trapezium is that it can be used to predict the volume of the 3D printed trapezium required in an Eaton stage III/IV wrist. We can assume the calculated trapezium volume of a stage III/IV wrist equals ~17% of the net carpal volume, therefore it is possible to calculate the approximate volume the trapezium would have been prior to the onset of OA, when the trapezium would have accounted for ~12-13% of the wrist rather, such as in a stage I/II wrist. The predicted volume can be used to scale the standard 3D printed trapezium implant to fit the stage III/IV wrist, as if it were still a stage I/II wrist.

#### *Relationship of trapezium volume to local anatomy*

The relationship of each carpal bone volume and the volume of the trapezium was investigated to predict the required volume of the trapezium in cases of previously failed trapeziectomy which require revision surgery, potentially with a 3D printed trapezium. The current study was undertaken with the premise that the dimensions of the trapezium correlated with other local anatomy based on the concepts described by Loisel et al who suggested it might be possible to predict trapezium height from the length of the forearm (209). Furthermore, the study by Crisco et al showed that carpal bone dimensions (height, length and width) increased with increasing volume and it was possible to approximately

predict the volume of each carpal bone based on the volume of another. Each of these studies used only healthy subjects without the presence of OA.

Multiple linear regression analysis on the data set from Peninsula health (containing all Eaton stages of Trapezia) showed that the volume of the Lunate had the most significant correlation with the volume of the trapezium. The regression analysis using all carpal bones had an R of 0.85 and  $R^2$  0.72 as compared to an R of 0.832 and  $R^2$  of 0.693 for the single linear regression using only the volume of the Lunate. The slightly higher R and  $R^2$  value in the former model can be explained by the presence of multiple variables. Furthermore, the  $R^2$  of 0.693 in the Lunate only single linear regression denotes that 69.3% of the variability in the trapezium can be accounted for by the lunate. Thus, the Lunate is the best predictor of trapezium volume. As all stages of Eaton were included the equation can be broadly applied in all Eaton stages of trapezia, including cases of previous trapeziectomy.

### *Implant sizing*

An ideal method of sizing would be to replace the patient's own trapezium with a morphologically identical bespoke 3D printed implant. It would be individualised to fit the patient's anatomy exactly in terms of size and morphology. For this to be a viable option the patient requires essentially a morphologically normal trapezium on pre-operative imaging, ideally CT, to create the 3D printed trapezium. From the review of the literature concerning trapezium anatomy it is clear that in severe stages of OA such as Eaton stage III and IV trapezium morphology is significantly altered; decreased trapezium height, osteophyte formation and volar wear. Creating a 3D printed implant from such a template trapezium is not ideal because the instability of a native stage III/IV trapezium is likely to be conferred to the morphologically identical 3D printed implant. Therefore, creating a bespoke trapezium



implant directly from the patients pre-operative imaging would theoretically only be possible in Eaton stage I and II where the normal trapezial morphology is essentially preserved.

Similar to the case described in chapter 3 discussing replacement of the Lunate due to avascular necrosis (199), using the mirror image of the trapezium in the contralateral hand is the next best option. The concept has been proven in this case report. Although there would undoubtedly be differences in size and morphology between the two hands of an individual, the difference would be less so than two individuals matched for age, gender and stage of osteoarthritis. Similar to creating a bespoke implant using the patient's native trapezium of the treating hand, the contralateral hand trapezium too must contain an essentially morphologically normal (stage I and II) and intact trapezium. Therefore, imaging and correctly staging the contralateral hand is indicated if one was to choose this method of implant sizing.

The above options of using the native trapezium in the treating hand or mirrored trapezium of the contralateral hand may not be viable in cases of bilateral stage III/IV OA or if the patient has previously undergone trapeziectomy. Such cases devoid the use of the patients own trapezium as a template to create the 3D printed implant, therefore a standard implant containing the morphology of a healthy trapezium would be required instead.

The anatomical study of the trapezium conducted contains information on trapezial volume in different gender, and age demographics, as well as stage of OA. To collect the data on trapezial and other carpal bone volume 3D surface models were created from 60 CT wrists scan. The surface models of the stage I and II trapeziums have the potential to be 3D

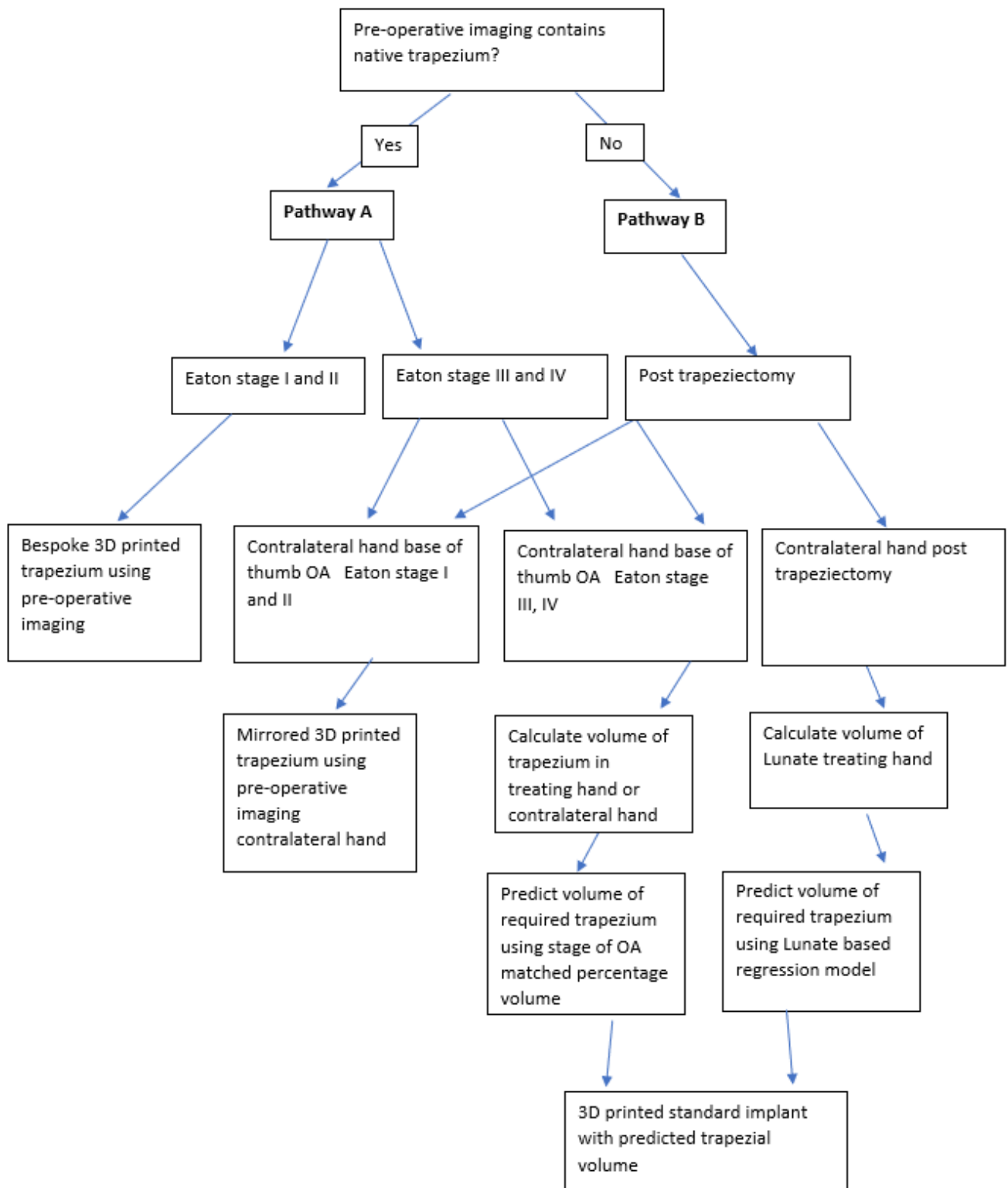
printed and used as a trapezoidal implant. As there are significant differences in trapezoidal size between the genders and different age groups it is important to match for age and gender. Therefore, these surface models provide a bank of potential implant sizes which can be matched to a patient based on age and gender.

The data set can further be used to size a standard 3D printed implant by predicting the ideal volume of the desired implant in stage III/ IV OA and in cases post trapeziectomy. From the anatomical study the gender difference in trapezium was related to absolute size of the trapezium. Thus, the percentage volume which the trapezium occupied of the net carpal volume did not significantly differ between genders. This is in keeping with similar findings that male and female trapeziums are scaled versions of one another. Therefore, percentage volume can be used to predict the desired volume hence size of the implant. For example, a female patient with stage III/IV OA is likely to have a trapezium which occupies 17.11% of the net volume of the carpus, however a female patient with stage I OA is likely to have a trapezium which occupies 12.43% of the net volume of the carpus (Table 17). Therefore, the percentage difference between stage III/IV vs stage I is 4.68%. If the patient contains a stage III/IV trapezium (either in the treating hand or contralateral hand) the volume of this trapezium can be used to predict the required volume of a standard trapezium, i.e. by decreasing calculated volume by 4.68%. Using the CAD software program Mesh mixer allows manipulation of the surface models to scale up or down according to requirements.

Failing the above methods, in cases where the patient requires revision surgery for failed trapeziectomy, the required volume of the standard implant can be predicted using the regression model based on the volume of the lunate.

## Conclusion

Correct sizing is crucial to implant stability. The anatomical study of the trapezium provided a basis for developing a system to size the implant appropriately. The following algorithm summarises the suggested methods of sizing a 3D printed trapezium in different scenarios.



**Figure 94. Sizing algorithm for 3D printed trapezium**

# **CHAPTER 5**

## **Discussion**

## CHAPTER 5: Discussion

### Morphology of an ideal implant: A 3D printed trapezium

“Nature is an incredibly clever, efficient and novel innovator. Often the solution to many of our engineering problems can be found within natural characteristics, whether it comes from flora, fauna or geological phenomena. When we imitate nature’s engineering to optimize our lives, we refer to it as biomimicry. Biomimicry can be seen in aerodynamics, architecture, agriculture and medicine.”

~ Gaia.com, 8<sup>th</sup> January 2019

The above statement encapsulates exactly the concept of a 3D printed trapezium. It is biomimicry in motion; using the morphology created by nature as a template for an implant. The morphology of the native trapezium has essentially been sculpted by natural selection over tens of millions of years. Modern humans have basal thumb joints which are flatter and less congruous than the great apes (Chimpanzees and Gorilla). The hypothesis being that flatter and less congruous joints therefore lead to greater range of motion (257). Purpose built out of necessity, it is the shape which is most ideal for the functions of the thumb: To have high mobility and dexterity, as well as stability to oppose all other digits in power and pinch grip. These capabilities of the thumb facilitate the functional lives we opt to live. Therefore, it is intuitive to restore the original morphology which nature intended in order to restore optimal function. The requirements of an ideal implant would include adequate treatment of pain, restoration of thumb length and stability, correction of an adduction deformity if present, have acceptable complication and failure rates, have a low cost of manufacture, be technically feasible, and offer the patient a fast road to recovery. This must all be implemented in the context of the ethics of implementing new technology. The following paragraphs discuss how a 3D printed trapezium could potentially meet these requirements.

## Adequate treatment of pain

The primary symptom which progresses the patient with base of thumb OA towards surgical management is pain. To recap earlier discussions from chapter 1, approximately one third of patients with base of thumb OA present with pain. However, only a fraction of these patients respond to conservative management, therefore the remaining majority require surgical intervention. Thus, alleviating pain is one of the main (if not the main) goals of any base of thumb arthritis surgery. Many of the operations (non-implant and implant based) are able to fulfil this surgical goal. Optimal treatment of pain using an implant however requires complete resection or replacement of the whole joint, as the TJR and interposition post total trapezial resection had the lowest rates of persisting pain (chapter 2). Although TJR encountered lower rates of persisting pain it had a higher revision rate than the interposition with total trapezial resection group (figure 43). Therefore, an implant used together with a complete trapeziectomy is the most effect method of treating pain as performing the total trapeziectomy is the single most important surgical step in adequately treating pain. It then follows that an implant with an ideal morphology too should be one which is used post total trapeziectomy. A 3D printed trapezium meets this requirement as it is designed to be used post trapeziectomy. Using a 3D printed trapezium is therefore expected to achieve good pain relief.

## Restoration of thumb stability

Instability of the thumb due to attenuation of stabilising ligaments and preferential volar wear of the trapezium results in volar collapse of the metacarpal and dorsal-radial subluxation of the metacarpal base. This is most pronounced in particularly severe stages (Eaton stage III and IV) of disease. Thumb instability and metacarpal subluxation contribute to weakness in pinch and grip strength as well as formation of a Z-deformity. A healthy trapeziometacarpal joint is stable in pinch and power grip due to the morphology of the joint particularly as the volar beak engages with the trapezial recess. Furthermore, the trapezium is inherently stable in the wrist as traumatic dislocation of a healthy native trapezium is exquisitely rare (228). By nature's own design, the carpal bones possess inherent stability. This is due to the unique morphology and intricate articulation of one carpal bone with another. Like a 3D jigsaw puzzle each of the eight carpal bones assumes its place to form a

stable wrist. It is expected that a 3D printed trapezium would restore thumb stability by providing an exact anatomical match to the native trapezium in stage I and II disease, as discussed in chapter 4. In severe stages, and in cases requiring revision post failed trapeziectomy, the arthritic trapezium could be replaced by a trapezium with normal morphology matched by gender and age or according to the size of the Lunate (figure 94). By individualising the implant to the patient's anatomy, the bony stability conferred by a native trapezium is expected to be restored. To restore ligament stability, good capsular repair and ligament reconstruction could also be done in conjunction. If sufficient capsular tissue exists to ensure implant coverage and stability this alone may be sufficient, alternatively specific ligament reconstruction using APL or FCR may be required employing similar techniques to Weilby or Burton-Pellegrini procedures. Adding specific features to the implant such as anchoring points may also improve stability and help reduce subluxation and dislocation rates of the implant.

#### Restoration or improvement of thumb strength

Along with pain one of the other symptoms treated by base of thumb surgery is weakness in pinch and grip strength. The weakness encountered is due to a mixture of pain and instability. As a 3D printed trapezium implant is expected to achieve good pain relief and also restore thumb stability, it follows that restoration of pinch and grip strength too can be expected. However, this would need to be confirmed in future studies investigating the outcomes of a 3D printed trapezium.

#### Retention of thumb length

Metacarpal subsidence post trapeziectomy leads to thumb shortening, and could potentially progress to form new scapho-metacarpal OA which may in turn once again lead to pain and disability. Shortening of the thumb is one of the undesirable outcomes of simple trapeziectomy and trapeziectomy with LRTI, therefore one of the aims of using an implant is to restore thumb length. Using a 3D printed trapezium will prevent metacarpal subsidence by acting as a spacer between the metacarpal base and scaphoid. Furthermore, implant subsidence is unlikely to occur as the group of



implants with the lowest rates of implant subsidence was the interposition with total trapezial resection group which a 3D printed implant belongs to (Figure 50). Further to the above, it is expected that a 3D printed trapezium will have the ability to restore the original thumb length as the implant will be sized according to the patient's individual anatomy (chapter 4, figure 94). Restoring original length would in turn restore optimal function and cosmesis.

### Correction of adduction deformity

The Zigzag, 'Z', or adduction deformity of the thumb seen in severe stages of OA is secondary to volar wear of the trapezium, and ligament attenuation which leads to volar collapse of the metacarpal column and dorso-radial subluxation of the metacarpal base. The collapsed metacarpal prevents abduction of the thumb resulting in the adduction deformity. Compensatory hyperextension therefore takes place at the MCP joint leading to the zigzag appearance. Therefore, addressing the root (i.e. the base) of the problem by restoring the original morphology of the trapezium should theoretically restore the metacarpal to its original place. Further collapse would also be prevented especially if done in conjunction with good ligament and capsular repair.

### No implant related complications

Implant related complications are the main obstacles to overcome when using an implant, including a 3D printed trapezium implant. Chapter 2 is dedicated to exploring all implant related complications in the five trapezial implant design groups: TJR, hemiarthroplasty, and interposition with no, partial and total trapezial resection. The design group which a 3D printed trapezium belongs to is "interposition with total trapezial resection" therefore, it may be possible to anticipate and overcome potential complications encountered by assessing the complications encountered by other implants in this group. The most frequent complications in this design group were dislocation, subluxation and foreign body reaction. Foreign body reactions are more concerned with the material used to manufacture the implant as opposed to the morphology of the implant itself. The material used for the implant is just as critical to its success as the morphology of the implant. Especially when

considering the elastic modulus of the material which may impact morphology due to deformation under pressure. Elastic modulus is also important when considering its effects on the articulating bones surrounding the implant. If a large elastic modulus mismatch exists between bone and the implant it may lead to further complications such as osteolysis and implant subsidence. Although the ideal material for a trapezium implant is beyond the scope of the current project, foreign body reactions were not encountered with Pyrocarbon implants. Furthermore, Pyrocarbon maybe an ideal material as it also contains similar elastic modulus to cortical bone.

Dislocation and subluxation rates are expected to be lower with the 3D printed trapezium due to the inherent stability provided by its analogous morphology to a native trapezium. As presented in chapter 2 discussion, inadequate capsular repair or ligament reconstruction was a leading cause of dislocation in the interposition with total trapezium resection group. Therefore, addressing this point with good capsular re-enforcement and ligament reconstruction would likely help reduce dislocation and subluxation rates. Further anchoring the 3D printed trapezium with a mechanism, such as, with using Mitek anchors extending to the trapezoid and second metacarpal base are viable options to potentially enhance stability. Incorrect implant sizing was one of the other causes of dislocation. The algorithm described in chapter 4, which uses the patient's own trapezium, the contralateral hand's trapezium or using the volume of the lunate will guide the surgeon in sizing the implant correctly. Trauma and excessive use of the hand were also noted to be caused of subluxation and dislocation in this group of implants. Although addressing this point is partly beyond the control of the hand surgeon, and relies more on patient compliance to hand therapy and advice, it may be sensible to err on the side of caution to immobilise the patient in a splint or cast for 4-6 weeks while continuing hand therapy to minimize potential early dislocations or subluxations.

#### Acceptable failure rates

A 0% implant failure rate within the life span of the patient is ideal. However, this maybe an unattainable ideal. Joint replacements, like any other mechanical device follows a 'U' shaped rate of failure with time. An initial high rate of failure is followed by a plateau phase, which is again followed

by a high rate of failure as the implant components reaches its life expectancy (159). Although creating an implant with a 0% failure rate is highly unlikely, it is still worth striving for, as doing so may lead to an implant with an acceptable or even excellent failure rate. Precisely defining what is an acceptable failure rate is important for decision making. This is to either accept or reject continued use of an implant. Many of the complications implicated in trapezial implants ultimately lead to implant failure. All-cause failure rates were higher in all the implant arthroplasty groups when compared to the non-implant techniques of simple trapeziectomy, trapeziectomy +/- LRTI and joint fusion. The AOANJRR states that “a commonly accepted benchmark standard (for hip replacement) is a 5% cumulative revision at 10 years”. However, no such implant registry or benchmark exists to define an acceptable failure rate for a trapezial implant. As discussed in Chapter 2, the AOANJRR identifies implants with higher than expected failure rates by doubling the overall failure rates within a class of implants. Using a similar train of thought, an acceptable benchmark for an ideal trapezial implant could be defined as twice the failure rate of trapeziectomy with LRTI. The argument for proposing twice the failure rate of trapeziectomy +/- LRTI as the acceptable benchmark is supported by two valid reasons. Firstly, trapeziectomy +/- LRTI is the operation which is currently most widely practiced by hand surgeons in Australia, America and around the world to surgically treat base of thumb OA (190, 229). Secondly, trapeziectomy +/- LRTI contains the lowest all-cause failure rates when comparing the different implant and non-implant techniques (figure 55). Therefore, twice the failure rate of trapeziectomy +/- LRTI is a plausible benchmark to set as a gold standard for an ideal trapezial implant. The literature review assessing failure rates of non-implant arthroplasty derived an all-cause failure rate of 2.4% in 10 years for trapeziectomy +/- LRTI. Therefore, the proposed acceptable benchmark for all cause failure of an ideal trapezial implant is 4.8% in 10 years. Furthermore, an implant which matches or has a lower rate of failure than 2.4% in 10 years could be considered to have an excellent rate of failure.

### Operation technically feasible

Incorporating a 3D printed trapezium into practice would theoretically have a short learning curve for a hand surgeon. As a total trapeziectomy is the first step, this would not add any extra learning

burden since trapeziectomy is standard practice by most hand surgeons. After performing a trapeziectomy, the 3D printed trapezium is inserted into the trapezoidal space. Thus, the novel aspect of the operation is placement of the implant in proper orientation into the trapezoidal space. Due to the implant having identical morphological features to a native trapezium, orientation of the implant would only have one correct possibility. Furthermore, the trapezoidal space is influenced by the morphology of the surrounding carpal bones and base of the first metacarpal forming its walls. Thus, the morphology of the space would also optimally accommodate the implant in one orientation. It is more than likely that it is not possible to place the implant incorrectly or would be easily recognized if placed incorrectly. Anatomical landmarks can be used to further guide orientation. One of the most important anatomical features of the trapezium, and therefore the implant, is the FCR groove (figure 74). The FCR groove should be oriented to sit ulnarly, facing inward and towards the carpal tunnel. It is expected that insertion of the implant maybe more challenging in cases where previous trapeziectomy has been performed and implant arthroplasty done as a secondary salvage procedure post primary trapeziectomy. The trapezoidal space in such cases maybe contracted and collapsed requiring extensive ligament and capsular release to help accommodate the implant. The methods used to size the implant would be derived from “pathway B” of the sizing algorithm (Figure 94), deriving size from matched percentage volume of the trapezium or using lunate volume. These are secondary means of sizing and carry limitations with greater risk of incorrect sizing compared to using one’s own trapezia as a template. Similar challenges may again be encountered in cases of severe (Eaton stage IV) OA as the space may again be collapsed and unable to accommodate a healthy shaped trapezium shaped implant. In such cases having a number of possible implants of different sizes may help to accommodate for these potential challenges.

### [Fast post operation recovery](#)

One of the other areas for improvement using implant arthroplasty is to secure shorter periods of convalescence and a faster road to recovery. Broadly, recovery post hand surgery can be broken into fixed and flexible periods. The fixed period can be defined as the length of time the patient is dictated to spend in a splint or plaster-cast post-operatively. It is a fixed period (both physically and

figuratively) as it would be constant for every patient; undergoing the same operation; by the same surgeon. The flexible period is the time spent with hand therapy to regain mobility, strength and function. It is a flexible period as it is likely to be different for each patient and depends on individual patient compliance and how they progress through therapy. The fixed period or time spent in a splint post-operatively is less after implant arthroplasty. The systematic reviews of the implant and non-implant arthroplasty literature also gathered data on length of post-operative splinting. The length of post-operative splinting for patients having simple trapeziectomy, trapeziectomy + LRTI, and joint fusion was 5 weeks, 5.52 weeks and 6.68 weeks respectively. The average length of post-operative splinting for patients with implants in the 'interposition with total trapezium resection' group (which a 3D printed trapezium belongs to) had an average length of 4.73 weeks of splinting post-surgery. Unfortunately, out of the five implant design groups, this was the group of implants which had the longest average length of post-operative splinting. The length of splinting in this group was closer to simple trapeziectomy and trapeziectomy +/- LRTI operations than the other implant groups. This is understandable as all these operations share a common denominator of total trapeziectomy. Further studies would need to be conducted to determine optimal length of splinting specific to a 3D printed trapezium. Ideally the patient returns to pre-morbid levels or comparable to the contralateral hand in strength, mobility and confidence in using the hand with the 3D printed trapezium in situ.

#### Low cost of manufacture

Using an implant impacts the overall cost of an operation due to its manufacture, sterilisation and effects on length of operation. The length of the operation compared to simple trapeziectomy and trapeziectomy with LRTI is unlikely to be significantly affected by using a 3D printed trapezium, as the majority of the length of the operation is likely to be occupied by performing the trapeziectomy. Cost related to manufacture of the implant would depend partly on the material used and the labour involved in creating a 3D model and printing. Individual cost of a 3D printed trapezium may vary depending on whether a complete bespoke implant is required compared to a standard implant with optimal sizing. Creating a bespoke implant would be more labour and time intensive as a completely new surface model would need to be created by segmenting the patient's own trapezium using their

CT scans as a template. Using a standard implant surface model would bypass this step and be less time intensive, as the standard model would only require scaling up or down depending on the volume required. Both scenarios however require the implant to be 3D printed and carry out necessary post-processing to remove unwanted rough surfaces. Finally, sterilisation of the implant is required prior to implantation. Although there is likely to be added cost in using an implant, the current literature suggests 3D printing can be used to manufacture bespoke implants or replicate standard implants more rapidly in an efficient and cost-effective manner (chapter 3). Furthermore, cost of manufacture would depend on the material used for 3D printing. As previously suggested, an ideal material should have similar properties to cortical bone. Thus, 3D printing a bespoke implant in an ideal material is the scope of further research.

## Conclusion

Innovation in surgery has a common goal of advancing, refining or improving a given surgical technique used to treat a particular surgical condition. Using a 3D printed trapezium to replace the native trapezium in base of thumb OA is no different. The concept is novel and innovative. However, as with any novel procedure its transition to standard care has certain ethical implications. The most pertinent of them is patient safety (230). The first cohorts of patients to undergo a novel procedure lacks the body of evidence which standard procedures are likely to have. The current project provides preliminary evidence supporting the safe and effective use of a 3D printed trapezium as an implant possessing an ideal morphology for surgical treatment of base of thumb osteoarthritis. Progression of the project with further research maybe undertaken by manufacturing a bespoke implant using the suggested methods, undertaking cadaveric studies to refine the surgical procedure and investigate the biomechanics, and finally to trial an implant in a patient to present proof of concept as a case report.

# References

## REFERENCES:

1. Key AJM, Dunmore CJ. The evolution of the hominin thumb and the influence exerted by the non-dominant hand during stone tool production. *J Hum Evol.* 2015;78(Sup C):60-9.
2. Marzke MW. Evolutionary development of the human thumb. *Hand Clin.* 1992;8(1):1-8.
3. Turker T, Thirkannad S. Trapezio-metacarpal arthritis: The price of an opposable thumb! *Indian J Plast Surg.* 2011;44(2):308-16.
4. Haara MM, Heliovaara M, Kroger H, Arokoski JP, Manninen P, Karkkainen A, et al. Osteoarthritis in the carpometacarpal joint of the thumb. Prevalence and associations with disability and mortality. *J Bone Joint Surg Am.* 2004;86-A(7):1452-7.
5. Pinsolle V, Vandermeersch B. Thumb arthritis yesterday and today. Epidemiologic comparison in an ancient population. *Ann Chir Plast Esthet.* 47(1):57-61.
6. Lawrence JS, Bremner JM, Bier F. Osteo-arthritis. Prevalence in the population and relationship between symptoms and x-ray changes. *Ann Rheum Dis.* 1966;25(1):1-24.
7. Marshall M, van der Windt D, Nicholls E, Myers H, Dziedzic K. Radiographic thumb osteoarthritis: frequency, patterns and associations with pain and clinical assessment findings in a community-dwelling population. *Rheumatology.* 2011;50(4):735-9.
8. Dahaghin S, Bierma-Zeinstra SM, Ginai AZ, Pols HA, Hazes JM, Koes BW. Prevalence and pattern of radiographic hand osteoarthritis and association with pain and disability (the Rotterdam study). *Ann Rheum Dis.* 2005;64(5):682-7.
9. Becker SJ, Briet JP, Hageman MG, Ring D. Death, taxes, and trapeziometacarpal arthrosis. *Clin Orthop.* 2013;471(12):3738-44.
10. Armstrong AL, Hunter JB, Davis TRC. The prevalence of degenerative arthritis of the base of the thumb in post-menopausal women. *J Hand Surge Br.* 1994;19 B(3):340-1.
11. Van Heest AE, Kallemeier P. Thumb carpal metacarpal arthritis. *J Am Acad Orthop Surg.* 2008;16(3):140-51.
12. Eaton RG, Glickel SZ. Trapeziometacarpal osteoarthritis. Staging as a rationale for treatment. *Hand Clin.* 1987;3(4):455-71.



13. Bakri K, Moran SL. Thumb carpometacarpal arthritis. *Plast Reconstr Surg.* 2015;135(2):508-20.
14. Barron OA, Glickel SZ, Eaton RG. Basal joint arthritis of the thumb. *J Am Acad Orthop Surg.* 2000;8(5):314-23.
15. Bakri K, Moran SL. Thumb carpometacarpal arthritis. *Plast Reconstr Surg.* 2015;135(2):508-20.
16. Van Heest AE, Kallemeier P. Thumb carpal metacarpal arthritis. *J Am Acad Orthop Surg.* 2008;16(3):140-51.
17. Eaton RG, Littler JW. Ligament reconstruction for the painful thumb carpometacarpal joint. *J Bone Joint Surg Am.* 1973;55(8):1655-66.
18. Kubik NJ, 3rd, Lubahn JD. Intrarater and interrater reliability of the Eaton classification of basal joint arthritis. *J Hand Surg Am.* 2002;27(5):882-5.
19. Badia A, Khanchandani P. Thumb Carpometacarpal Joint Arthroscopy: A Classification System and Rationale for Treatment. *Operative Techniques in Orthopaedics.* 2007;17(2):125-32.
20. Spaans AJ, van Minnen LP, Kon M, Schuurman AH, Schreuders AR, Vermeulen GM. Conservative treatment of thumb base osteoarthritis: a systematic review. *J Hand Surg Am.* 2015;40(1):16-21.e1-6.
21. Villafañe JH, Silva GB, Bishop MD, Fernandez-Carnero J. Radial Nerve Mobilization Decreases Pain Sensitivity and Improves Motor Performance in Patients With Thumb Carpometacarpal Osteoarthritis: A Randomized Controlled Trial. *Archives of Physical Medicine and Rehabilitation.* 2012;93(3):396-403.
22. Villafañe JH, Silva GB, Diaz-Parreño SA, Fernandez-Carnero J. Hypoalgesic and Motor Effects of Kaltenborn Mobilization on Elderly Patients with Secondary Thumb Carpometacarpal Osteoarthritis: A Randomized Controlled Trial. *Journal of Manipulative and Physiological Therapeutics.* 2011;34(8):547-56.
23. Villafane JH, Cleland JA, Fernandez-de-Las-Penas C. The effectiveness of a manual therapy and exercise protocol in patients with thumb carpometacarpal osteoarthritis: a randomized controlled trial. *Journal of Orthopaedic & Sports Physical Therapy.* 2013;43(4):204-13.

24. Rannou F, Dimet J, Boutron I, Baron G, Fayad F, Mace Y, et al. Splint for base-of-thumb osteoarthritis: a randomized trial. *Ann Intern Med.* 2009 May 19;150(10):661-9
25. Bani MA, Arazpour M, Kashani RV, Mousavi ME, Hutchins SW. Comparison of custom-made and prefabricated neoprene splinting in patients with the first carpometacarpal joint osteoarthritis. *Disabil Rehabil Assist Technol.* 2013;8(3):232-7.
26. Sillem H, Backman CL, Miller WC, Li LC. Comparison of two carpometacarpal stabilizing splints for individuals with thumb osteoarthritis. *J Hand Ther.* 2011;24(3):216-25
27. Weiss S, LaStayo P, Mills A, Bramlet D. Prospective analysis of splinting the first carpometacarpal joint: an objective, subjective, and radiographic assessment. *J Hand Ther.* 2000;13(3):218-26.
28. Bahadir C, Onal B, Dayan VY, Gurer N. Comparison of therapeutic effects of sodium hyaluronate and corticosteroid injections on trapeziometacarpal joint osteoarthritis. *Clin Rheumatol.* 2009;28(5):529-33.
29. Fuchs S, Monikes R, Wohlmeiner A, Heyse T. Intra-articular hyaluronic acid compared with corticoid injections for the treatment of rhizarthrosis. *Osteoarthritis Cartilage.* 2006;14(1):82-8.
30. Baker RH, Al-Shukri J, Davis TR. Evidence-Based Medicine: Thumb Basal Joint Arthritis. *Plast Reconstr Surg.* 2017;139(1):256e-66e.
31. Aliu O, Davis MM, DeMonner S, Chung KC. The influence of evidence in the surgical treatment of thumb basilar joint arthritis. *Plast Reconstr Surg.* 2013;131(4):816-28.
32. Gervis WH. Excision of the trapezium for osteoarthritis of the trapezio-metacarpal joint. *J Bone Joint Surg Br.* 1949;31B(4):537-9, illust.
33. Berger AJ, Meals RA. Management of osteoarthrosis of the thumb joints. *J Hand Surg Am.* 2015;40(4):843-50.
34. Salem H, Davis TR. Six year outcome excision of the trapezium for trapeziometacarpal joint osteoarthritis: is it improved by ligament reconstruction and temporary Kirschner wire insertion? *J Hand Surg Eur.* 2012;37(3):211-9.
35. Belcher HJ, Nicholl JE. A comparison of trapeziectomy with and without ligament reconstruction and tendon interposition. *J Hand Surg Br.* 2000;25(4):350-6.

36. Salem HMM, Davis TRCFa. Degenerative Change at the Pseudarthrosis After Trapeziectomy at 6-year Followup. *Clin Orthop*. 2014;472(4):1160-5.
37. Fischer J, Shivarathre D, Quinton D. Management of long term complications following trapeziectomy. *J Bone Joint Surg Br*. 2011;93-B Supplement(III):301.
38. Nylen S, Juhlin LJ, Lugnegard H. Weilby tendon interposition arthroplasty for osteoarthritis of the trapezial joints. *J Hand Surg Br*. 1987;12(1):68-72.
39. Burton RI, Pellegrini Jr VD. Surgical management of basal joint arthritis of the thumb. Part II. Ligament reconstruction with tendon interposition arthroplasty. *J Hand Surg Am*. 1986;11(3):324-32.
40. Sigfusson R, Lundborg G. Abductor pollicis longus tendon arthroplasty for treatment of arthrosis in the first carpometacarpal joint. *Scand J Plast Reconstr Surg Hand Surg*. 1991;25(1):73-7.
41. Jorheim M, Isaxon I, Flondell M, Kalen P, Atroshi I. Short-term outcomes of trapeziometacarpal artelon implant compared with tendon suspension interposition arthroplasty for osteoarthritis: a matched cohort study. *J Hand Surg Am*. 2009;34(8):1381-7.
42. Gangopadhyay S, Davis TRC. Advances in treatment of basal joint arthritis of the thumb. *Current Orthopaedic Practice*. 2008;19(5):503-8.
43. Muermans S, Coenen L. Interpositional arthroplasty with Gore-Tex, Marlex or tendon for osteoarthritis of the trapeziometacarpal joint. A retrospective comparative study. *J Hand Surg Br*. 1998;23(1):64-8.
44. Bidwai AS, Marlow WJ, Khan Y, Waseem M. Five to eight years follow-up for trapeziectomy and Weilby ligament reconstruction for the treatment of trapeziometacarpal osteoarthritis. *Hand Surg*. 2013;18(3):369-73.
45. Vermeulen GM, Slijper H, Feitz R, Hovius SE, Moojen TM, Selles RW. Surgical management of primary thumb carpometacarpal osteoarthritis: a systematic review. *J Hand Surg Am*. 2011;36(1):157-69.
46. Wajon A, Vinycomb T, Carr E, Edmunds I, Ada L. Surgery for thumb (trapeziometacarpal joint) osteoarthritis. *Cochrane Database Syst Rev*. 2015(2):CD004631.
47. Klimo GF, Verma RB, Baratz ME. The treatment of trapeziometacarpal arthritis with arthrodesis. *Hand Clin*. 2001;17(2):261-70.

48. Schroder J, Kerkhoffs GM, Voerman HJ, Marti RK. Surgical treatment of basal joint disease of the thumb: comparison between resection-interposition arthroplasty and trapezio-metacarpal arthrodesis. *Arch Orthop Trauma Surg.* 2002;122(1):35-8.
49. Hartigan BJ, Stern PJ, Kiefhaber TR. Thumb carpometacarpal osteoarthritis: arthrodesis compared with ligament reconstruction and tendon interposition. *J Bone Joint Surg Am.* 2001 83-A(10):1470-8.
50. Li YK, White C, Ignacy TA, Thoma A. Comparison of trapeziectomy and trapeziectomy with ligament reconstruction and tendon interposition: a systematic literature review. *Plast Reconstr Surg.* 2011;128(1):199-207.
51. Gangopadhyay S, McKenna H, Burke FD, Davis TR. Five- to 18-year follow-up for treatment of trapeziometacarpal osteoarthritis: a prospective comparison of excision, tendon interposition, and ligament reconstruction and tendon interposition. *J Hand Surg Am.* 2012;37(3):411-7.
52. Conolly WB, Lanzetta M. Surgical management of arthritis of the carpo-metacarpal joint of the thumb. *Aust N Z J Surg.* 1993;63(8):596-603.
53. Amadio PC, De Silva SP. Comparison of the results of trapeziometacarpal arthrodesis and arthroplasty in men with osteoarthritis of the trapeziometacarpal joint. *Ann Chir Main Memb Super.* 1990;9(5):358-63.
54. Vitale MA, Taylor F, Ross M, Moran SL. Trapezium prosthetic arthroplasty (silicone, Artelon, metal, and pyrocarbon). *Hand Clin.* 2013;29(1):37-55.
55. Swanson AB. Disabling arthritis at the base of the thumb: treatment by resection of the trapezium and flexible (silicone) implant arthroplasty. *J Bone Joint Surg Am.* 1972;54(3):456-71.
56. Lehmann O, Herren DB, Simmen BR. Comparison of tendon suspension-interposition and silicon spacers in the treatment of degenerative osteoarthritis of the base of the thumb. *Ann Chir Main Memb Super.* 1998;17(1):25-30.
57. Burton RI, Pellegrini VD, Jr. Surgical management of basal joint arthritis of the thumb. Part II. Ligament reconstruction with tendon interposition arthroplasty. *J Hand Surg Am* 1986 11(3):324-32.
58. Bezwada HP, Sauer ST, Hankins ST, Webber JB. Long-term results of trapeziometacarpal silicone arthroplasty. *J Hand Surg Am.* 2002;27(3):409-17.

59. Minami A, Iwasaki N, Kutsumi K, Suenaga N, Yasuda K. A long-term follow-up of silicone-rubber interposition arthroplasty for osteoarthritis of the thumb carpometacarpal joint. *Hand Surg*. 2005;10(1):77-82.
60. Hook WE, Stanley JK. The early experience of silastic trapezium implants. *J Hand Surg Br*.11(1):93-7.
61. Sollerman C, Hasselgren G, Westermark J, Herrlin K. Replacement of the Os Trapezium by Polyurethane Implants. *Scand J Plast Reconstr Surg Hand Surg*. 1993;27(3):217-21.
62. Eaton RG. Replacement of the trapezium for arthritis of the basal articulations: a new technique with stabilization by tenodesis. *J Bone Joint Surg Am*. 1979;61(1):76-82.
63. Ferlic DC, Busbee GA, Clayton ML. Degenerative arthritis of the carpometacarpal joint of the thumb: A clinical follow up of eleven Niebauer prostheses. *J Hand Surg*. 1977;2(3):212-5.
64. Poppen NK, Niebauer JJ. "Tie-in" trapezium prosthesis: Long-term results. *J Hand Surg Am*. 1978;3(5):445-50.
65. Adams BD, Unsell RS, McLaughlin P. Niebauer trapeziometacarpal arthroplasty. *J Hand Surg Am*. 1990;15(3):487-92.
66. Rajan S, Nylander G, Fransson SG. The Niebauer-Cutter prosthesis in excision arthroplasty of the trapezium. *Hand*. 1982;14(3):295-303.
67. Avisar E, Elvey M, Tzang C, Sorene E. Trapeziectomy With a Tendon Tie-in Implant for Osteoarthritis of the Trapeziometacarpal Joint. *J Hand Surg Am*. 2015;40(7):1292-7.
68. Grange WJ, Helal B. Replacement of the trapezium with a silicone rubber ball spacer. *Hand*. 1983;15(1):53-6.
69. Helal B, McPherson I. Replacement of the trapezium with a silicone elastomer universal small joint spacer. *J Hand Surg Br*. 1989;14(4):456-9.
70. O'Leary ST, Grobbelaar AO, Goldsmith N, Smith PJ, Harrison DH. Silicone arthroplasty for trapeziometacarpal arthritis. *J Hand Surg Br*. 2002;27(5):457-61.
71. Ardouin L, Bellemère P. A five-year prospective outcome study of Pi2 pyrocarbon arthroplasty for the treatment of thumb carpometacarpal joint osteoarthritis. *Chir Main*. 2011;30.
72. Agout C, Ardouin L, Bellemere P. A ten-year prospective outcome study of Pi2 pyrocarbon spacer arthroplasty in carpometacarpal joint osteoarthritis. *Hand Surg Rehabil*. 2016;35(4):255-61.

73. Colegate-Stone TJ, Garg S, Subramanian A, Mani GV. Outcome analysis of trapezectomy with and without pyrocarbon interposition to treat primary arthrosis of the trapeziometacarpal joint. *Hand Surg.* 2011;16(1):49-54.
74. Maru M, Jettoo P, Tourret L, Jones M, Irwin L. Thumb carpometacarpal osteoarthritis: trapeziectomy versus pyrocarbon interposition implant (Pi2) arthroplasty. *J Hand Surg Eur* 2012;37(7):617-20.
75. Szalay G, Meyer C, Scheufens T, Schnettler R, Christ R, Schleicher I. Pyrocarbon spacer as a trapezium replacement for arthritis of the trapeziometacarpal joint; a follow-up study of 60 cases. *Acta Orthop Belg.* 2013;79(6):648-54.
76. van Aaken J, Holzer N, Wehrli L, Delaquaize F, Gonzalez IA, Beaulieu JY. Unacceptable failure of the PI2 implant. *J Hand Surg Eur.*41(9):917-22.
77. Spaans AJ, Van Heeswijk EJM, Arnold DE, Beumer A. Foreign body reaction associated with polyethylene mesh interposition used for treatment of trapeziometacarpal osteoarthritis: Report of 8 cases. *J Hand Surg Am.* 2014;39(10):2016-9.
78. Schacherer T, Schneider LH. Resection arthroplasty at the basilar joint of the thumb. *Semin Arthroplasty.* 1991;2(2):109-19.
79. Nusem I, Goodwin DR. Excision of the trapezium and interposition arthroplasty with gelfoam for the treatment of trapeziometacarpal osteoarthritis. *J Hand Surg Br.* 2003;28(3):242-5.
80. Balayssac D, Poinas AC, Pereira B, Pezet D. Use of permacol in parietal and general surgery: a bibliographic review. *Surg Innov.* 2013;20(2):176-82.
81. Knabben L, Kanagalingam G, Imboden S, Günthert AR. Acellular Dermal Matrix (Permacol®) for Heterologous Immediate Breast Reconstruction after Skin-Sparing Mastectomy in Patients with Breast Cancer: A Single-Institution Experience and a Review of the Literature. *Front Med.* 2016;3:72.
82. Belcher HJ, Zic R. Adverse effect of porcine collagen interposition after trapeziectomy: a comparative study. *J Hand Surg Br.* 2001;26(2):159-64.
83. Greenberg JA, Mosher JF, Jr., Fatti JF. X-ray changes after expanded polytetrafluoroethylene (Gore-Tex) interpositional arthroplasty. *J Hand Surg Am.* 1997;22(4):658-63.

84. Haraguchi S, Yamashita Y, Yamashita K, Hioki M, Matsumoto K, Shimizu K. Sternal resection for metastasis from thyroid carcinoma and reconstruction with the sandwiched Marlex and stainless steel mesh. *Jpn J Thorac Cardiovasc Surg.* 2004;52(4):209-12.
85. Stockeld D, Granstrom L, Backman L, Dahlgren S. Inflammatory response to subcutaneously implanted Marlex and GORE-TEX in massively obese patients. *Biomaterials.* 1992;13(4):261-3.
86. Anakwenze OA, Huffman GR. Recurrent shoulder instability and arthritis treated with graft jacket resurfacing, hemiarthroplasty, and bone grafting. *Orthopedics.* 2011;34(2):140.
87. Kokkalis ZT, Zanos G, Weiser RW, Sotereanos DG. Trapezium resection with suspension and interposition arthroplasty using acellular dermal allograft for thumb carpometacarpal arthritis. *J Hand Surg Am.* 2009;34(6):1029-36.
88. Lauwers TMS, Brouwers K, Staal H, Hoekstra LT, van der Hulst RRWJ. Early outcomes of Pyrocardan® implants for trapeziometacarpal osteoarthritis. *Hand Surg Rehabil.* 2016;35(6):407-12.
89. Odella S, Querenghi AM, Sartore R, A DEF, Dacatra U. Trapeziometacarpal osteoarthritis: pyrocarbon interposition implants. *Joints.* 2014;2(4):154-8.
90. Barrera-Ochoa S, Vidal-Tarrason N, Correa-Vazquez E, Reverte-Vinaixa MM, Font-Segura J, Mir-Bullo X. Pyrocarbon interposition (PyroDisk) implant for trapeziometacarpal osteoarthritis: minimum 5-year follow-up. *J Hand Surg Am.* 2014;39(11):2150-60.
91. Bengezi O, Vo A. Early outcomes of arthroplasty of the first carpometacarpal joint using pyrocarbon spherical implants. *Plast Surg (Oakv).* 2014;22(2):79-82.
92. Nakajima H, Masada K, Ohno H, Shinmei M. A new arthroplasty of the basal joint of the thumb using a silicone ball. *J Orthop Surg.* 1996;4(1):61-6.
93. Adams BD, Pomerance J, Nguyen A, Kuhl TL. Early outcome of spherical ceramic trapezium-metacarpal arthroplasty. *J Hand Surg Am.* 2009;34(2):213-8.
94. Athwal GS, Chenkin J, King GJ, Pichora DR. Early failures with a spheric interposition arthroplasty of the thumb basal joint. *J Hand Surg Am.* 2004;29(6):1080-4.
95. Kessler FB, Epstein MJ, Culver JE, Jr., Prewitt J, Homsy CA. Proplast stabilized stemless trapezium implant. *J Hand Surg Am.* 1984;9(2):227-31.
96. Taleb C, Berner S, Mantovani Ruggiero G. First metacarpal resurfacing with polyvinyl alcohol implant in osteoarthritis: preliminary study. *Chir Main.* 2014;33(3):189-95.

97. Ashworth CR, Blatt G, Chuinard RG, Stark HH. Silicone-rubber interposition arthroplasty of the carpometacarpal joint of the thumb. *J Hand Surg Am.* 1977;2(5):345-57.
98. Engel J, Ganel A, Patish H, Kamhin M. Osteoarthritis of the trapezio-metacarpal joint. Results of treatment with a silicone cap implant. *Acta Orthop Scand.* 1982;53(2):219-23.
99. Pereira A, Ichihara S, Facca S, Hendriks S, Gouzou S, Liverneaux P. Arthroscopic interposition in thumb carpometacarpal osteoarthritis: A series of 26 cases. *Chir Main.* 2015;34(6):307-11.
100. Semere A, Forli A, Corcella D, Mesquida V, Loret MG, Moutet F. Foreign body reaction in osteoarthritis of the trapeziometacarpal joint treated by trapezectomy and interposition of a L-poly-lactic acid "anchovy" (Arex615R). A series of eight cases. *Chir Main.* 2013;32(3):161-8.
101. Diaconu M, Mathoulin C, Facca S, Liverneaux P. Arthroscopic interposition arthroplasty of the trapeziometacarpal joint. *Chir Main.* 2011;30(4):282-7.
102. Blount AL, Armstrong SD, Yuan F, Burgess SD. Porous polyurethaneurea (Artelon) joint spacer compared to trapezium resection and ligament reconstruction. *J Hand Surg Am.* 2013;38(9):1741-5.
103. Nilsson A, Liljensten E, Bergstrom C, Sollerman C. Results from a degradable TMC joint Spacer (Artelon) compared with tendon arthroplasty. *J Hand Surg Am.* 2005;30(2):380-9.
104. Huang YC, Jazayeri L, Le W, Yao J. Failure of artelon interposition arthroplasty after partial trapeziectomy: a case report with histologic and immunohistochemical analysis. *Am J Orthop.* 2015;44(4):E117-22.
105. van der Veen FJ, White DN, Dapper MM, Griot JP, Ritt MP. Clinical Evaluation of the Articulinx Intercarpometacarpal Cushion for the First CMC Joint: A Feasibility Study. *J Wrist Surg.* 2013;2(3):276-81.
106. Dickson RA. Arthritis of the carpometacarpal joint of the thumb. Treatment by silicone sponge interposition arthroplasty. An experimental and clinical study. *Hand.* 1976;8(3):197-208.
107. Cooney WPMD, Linscheid RLMD, Askew LJMS. Total Arthroplasty of the Thumb Trapeziometacarpal Joint. *Clin Orthop Relat Res.* 1987;220:35-45.
108. van Cappelle HG, Elzenga P, van Horn JR. Long-term results and loosening analysis of de la Caffiniere replacements of the trapeziometacarpal joint. *J Hand Surg Am.* 1999;24(3):476-82.



109. De Smet L, Sioen W, Spaepen D. Changes in key pinch strength after excision of the trapezium and total joint arthroplasty. *J Hand Surg Br.* 2004;29(1):40-1.
110. Nicholas RM, Calderwood JW. De la Caffiniere arthroplasty for basal thumb joint osteoarthritis. *J Bone Joint Surg Br.* 1992;74(2):309-12.
111. Sondergaard L, Konradsen L, Rechnagel K. Long-term follow-up of the cemented Caffiniere prosthesis for trapezio-metacarpal arthroplasty. *J Hand Surg Br.* 1991;16(4):428-30.
112. Albertoni WM, Leite VM, Faloppa F, Galbiatti JA. The de la Caffiniere arthroplasty. *J Orthop Surg Tech.* 1992;7(4):175-86.
113. Boeckstyns ME, Sinding A, Elholm KT, Rechnagel K. Replacement of the trapeziometacarpal joint with a cemented (Caffiniere) prosthesis. *J Hand Surg Am.* 1989;14(1):83-9.
114. August AC, Coupland RM, Sandifer JP. Short term review of the De La Caffiniere trapeziometacarpal arthroplasty. *J Hand Surg Eur.* 1984;9(2):185-8.
115. Spaans AJ, van Minnen LP, Weijns ME, Braakenburg A, van der Molen AB. Retrospective Study of a Series of 20 Ivory Prostheses in the Treatment of Trapeziometacarpal Osteoarthritis. *J Wrist Surg.* 2016;5(2):131-6.
116. Goubau JF, Goorens CK, Van Hoonacker P, Berghs B, Kerckhove D, Scheerlinck T. Clinical and radiological outcomes of the Ivory arthroplasty for trapeziometacarpal joint osteoarthritis with a minimum of 5 years of follow-up: a prospective single-centre cohort study. *J Hand Surg Eur.* 2013;38(8):866-74.
117. Robles-Molina MJ, Lopez-Caba F, Gomez-Sanchez RC, Cardenas-Grande E, Pajares-Lopez M, Hernandez-Cortes P. Trapeziectomy With Ligament Reconstruction and Tendon Interposition Versus a Trapeziometacarpal Prosthesis for the Treatment of Thumb Basal Joint Osteoarthritis. *Orthopedics.* 2017:1-6.
118. Martin-Ferrero M. Ten-year long-term results of total joint arthroplasties with ARPE implant in the treatment of trapeziometacarpal osteoarthritis. *J Hand Surg Eur.* 2014;39(8):826-32.
119. Aparad T, Cast YS. Mid-term results of arpe® prosthesis for the basal thumb osteoarthritis. *J Bone Joint Surg Br* 2009; 91-B: 96-96.
120. Eecken SV, Vanhove W, Hollevoet N. Trapeziometacarpal joint replacement with the Arpe prosthesis. *Acta Orthop Belg.* 2012;78(6):724-9.

121. Goddard NJ. Sixteen-Year Experience of the ARPE Prosthesis for Symptomatic Trapezial-Metacarpal Osteoarthritis. *J Hand Surg Am.* 2013;38(10):e45-e6.
122. Semere A, Vuillerme N, Corcella D, Forli A, Moutet F. Results with the Roseland HAC trapeziometacarpal prosthesis after more than 10 years. *Chir Main.* 2015;34(2):59-66.
123. Zollinger PE, Ellis ML, Unal H, Tuinebreijer WE. Clinical outcome of cementless semi-constrained trapeziometacarpal arthroplasty, and possible effect of vitamin C on the occurrence of complex regional pain syndrome. *Acta Orthop Belg.* 2008;74(3):317-22.
124. Kaszap B, Daecke W, Jung M. High frequency failure of the Moje thumb carpometacarpal joint arthroplasty. *J Hand Surg Eur.* 2012;37(7):610-6.
125. Dehl M, Chelli M, Lippmann S, Benaissa S, Rotari V, Moughabghab M. Results of 115 Rubis II reverse thumb carpometacarpal joint prostheses with a mean follow-up of 10 years. *J Hand Surg Eur.* 2017:1753193416687508.
126. Thillemann JK, Thillemann TM, Munk B, Kroner K. High revision rates with the metal-on-metal Motec carpometacarpal joint prosthesis. *J Hand Surg Eur.* 2016;41(3):322-7.
127. Hansen TB, Dremstrup L, Stilling M. Patients with metal-on-metal articulation in trapeziometacarpal total joint arthroplasty may have elevated serum chrome and cobalt. *J Hand Surg Eur.* 2013;38(8):860-5.
128. Bricout M, Rezzouk J. Complications and failures of the trapeziometacarpal Maia prosthesis: A series of 156 cases. *Hand Surg Rehabil.* 2016;35(3):190-8.
129. Chug M, Williams N, Benn D, Brindley S. Outcome of uncemented trapeziometacarpal prosthesis for treatment of thumb carpometacarpal joint arthritis. *Indian J Orthop Surg.* 2014;48(4):394-8.
130. Klahn A, Nygaard M, Gvozdenovic R, Boeckstyns ME. Elektra prosthesis for trapeziometacarpal osteoarthritis: a follow-up of 39 consecutive cases. *J Hand Surg Eur.* 2012;37(7):605-9.
131. Hernandez-Cortes P, Pajares-Lopez M, Robles-Molina MJ, Gomez-Sanchez R, Toledo-Romero MA, De Torres-Urrea J. Two-year outcomes of Elektra prosthesis for trapeziometacarpal osteoarthritis: a longitudinal cohort study. *J hand Surg Eur.* 2012;37(2):130-7.

132. Ulrich-Vinther M, Puggaard H, Lange B. Prospective 1-year follow-up study comparing joint prosthesis with tendon interposition arthroplasty in treatment of trapeziometacarpal osteoarthritis. *J Hand Surg Am.* 2008;33(8):1369-77.
133. Hansen TB, Snerum L. Elektra trapeziometacarpal prosthesis for treatment of osteoarthrosis of the basal joint of the thumb. *Scand J Plast Reconstr Surg Hand Surg.* 2008;42(6):316-9.
134. Regnard PJ. Electra trapezio metacarpal prosthesis: results of the first 100 cases. *J of Hand Surg Eur.* 2006;31(6):621-8.
135. Masmajejan E, Alnot JY, Chantelot C, Beccari R. Guepar anatomical trapeziometacarpal prosthesis. *Chir Main.* 2003;22(1):30-6.
136. Alnot JY, Muller GP. A retrospective review of 115 cases of surgically-treated trapeziometacarpal osteoarthritis. *Rev Rhum Engl Ed.* 1998;65(2):95-108.
137. Lemoine S, Wavreille G, Alnot JY, Fontaine C, Chantelot C, groupe G. Second generation Guepar total arthroplasty of the thumb basal joint: 50 months follow-up in 84 cases. *Orthop Traumatol Surg Res.* 2009;95(1):63-9.
138. Perez-Ubeda MJ, Garcia-Lopez A, Martinez FM, Vilanova EJ, Molina Martos M, Lopez-Duran Stern L. Results of the Cemented SR Trapeziometacarpal Prosthesis in the Treatment of Thumb Carpometacarpal Osteoarthritis. *J Hand Surg Eur.* 2003;28(6):917-25.
139. van Rijn J, Gosens T. A cemented surface replacement prosthesis in the basal thumb joint. *J Hand Surg Am.* 2010;35(4):572-9.
140. Braun RM. Total joint replacement at the base of the thumb--preliminary report. *J Hand Surg Am.* 1982;7(3):245-51.
141. Badia A, Sambandam SN. Total joint arthroplasty in the treatment of advanced stages of thumb carpometacarpal joint osteoarthritis. *J Hand Surg Am.* 2006;31(10):1605-14.
142. Hannula TT, Nahigian SH. A preliminary report: cementless trapeziometacarpal arthroplasty. *J Hand Surg Am.* 1999;24(1):92-101.
143. Wachtl SW, Sennwald GR. Non-cemented replacement of the trapeziometacarpal joint. *J Bone Joint Surg Br.* 1996;78(5):787-92.
144. Alnot JY, Saint Laurent Y. Total trapeziometacarpal arthroplasty. Report on seventeen cases of de generative arthritis of the trapeziometacarpal joint. *Ann Chir Main.* 1985;4(1):11-21.

145. Ferrari B, Steffee AD. Trapeziometacarpal total joint replacement using the Steffee prosthesis. *J Bone Joint Surg Am.* 1986;68(8):1177-84.
146. Stillwater L, Memauri B, Ratanshi I, Islur A, Amaratunga T. Radiographic interpretation of carpometacarpal arthroplasty: correlation between radiographic loosening and clinical outcome. *Skeletal Radiol.* 2017;19:19.
147. Woodward JF, Heller JB, Jones NF. PyroCarbon implant hemiarthroplasty for trapeziometacarpal arthritis. *Tech.* 2013;17(1):7-12.
148. Martinez de Aragon JS, Moran SL, Rizzo M, Reggin KB, Beckenbaugh RD. Early outcomes of pyrolytic carbon hemiarthroplasty for the treatment of trapezium-metacarpal arthritis. *J Hand Surg Am.* 2009;34(2):205-12.
149. Aita MA, Alves RS, Longuino LF, Ferreira CH, Ikeuti DH, Rodrigues LM. Measurement of quality of life among patient undergoing arthroplasty of the thumb to treat CMC arthritis. *Rev Bras Ortop.* 2016;51(4):431-6.
150. Pritchett JW, Habryl LS. A promising thumb Basal joint hemiarthroplasty for treatment of trapeziometacarpal osteoarthritis. *Clin Orthop.* 2012;470(10):2756-63.
151. Swanson AB, de Groot Swanson G, DeHeer DH, Pierce TD, Randall K, Smith JM, et al. Carpal Bone Titanium Implant Arthroplasty; 10 Years' Experience. *Clinical orthopaedics and related research.* 1997;342:46-58.
152. Phaltankar PM, Magnussen PA. Hemiarthroplasty for trapeziometacarpal arthritis - A useful alternative? *Journal of Hand Surgery.* 2003;28 B(1):80-5.
153. Naidu SH, Kulkarni N, Saunders M. Titanium basal joint arthroplasty: a finite element analysis and clinical study. *J Hand Surg Am.* 2006;31(5):760-5.
154. Malhotra R, Garg B. Ceramic trapezio-metacarpal arthroplasty: Probably half is better than full. *Journal of Clinical Orthopaedics and Trauma.* 2016;7:88-91.
155. Moher D, Liberati A, Tetzlaff J, Altman DG, The PG. Preferred Reporting Items for Systematic Reviews and Meta-Analyses: The PRISMA Statement. *PLOS Medicine.* 2009;6(7):e1000097.
156. Wachtl SW, Guggenheim PR, Sennwald GR. Cemented and non-cemented replacements of the trapeziometacarpal joint. *Journal of Bone and Joint Surgery - Series B.* 1998;80(1):121-5.

157. De Smet L, Sioen W, Spaepen D, Van Ransbeeck H. Total joint arthroplasty for osteoarthritis of the thumb basal joint. *Acta Orthop Belg.* 2004;70(1):19-24.
158. De Smet L, Sioen W. Basal joint osteoarthritis of the thumb: Trapeziectomy, with or without tendon interposition, or total joint arthroplasty? A prospective study. *European Journal of Orthopaedic Surgery and Traumatology.* 2007;17(5):431-6.
159. Murray DW, Carr AJ, Bulstrode C. Survival analysis of joint replacements. *J Bone Joint Surg Br.* 1993;75(5):697-704.
160. Masmajejan E, Alnot JY, Chantelot C, Beccari R. Guepar anatomical trapeziometacarpal arthroplasty. *Chir Main.* 2003;22(1):30-6.
161. Toffoli A, Teissier J. MAIA Trapeziometacarpal Joint Arthroplasty: Clinical and Radiological Outcomes of 80 Patients With More than 6 Years of Follow-Up. *J Hand Surg Am.* 2017.
162. Chakrabarti AJ, Robinson AH, Gallagher P. De la Caffiniere thumb carpometacarpal replacements. 93 cases at 6 to 16 years follow-up. *J Hand Surg Br.* 1997;22(6):695-8.
163. Bellemere P, Ardouin L. Pi2 spacer pyrocarbon arthroplasty technique for thumb basal joint osteoarthritis. *Tech hand Up Extrem Surg.* 2011;15(4):247-52.
164. van Cappelle HG, Deutman R, van Horn JR. Use of the Swanson silicone trapezium implant for treatment of primary osteoarthritis : long-term results. *J Bone Joint Surg Am.* 2001;83-A(7):999-1004.
165. Pendse A, Nisar A, Shah SZ, Bhosale A, Freeman JV, Chakrabarti I. Surface replacement trapeziometacarpal joint arthroplasty--early results. *J Hand Surg Eur.* 2009;34(6):748-57.
166. Kollig E, Weber W, Bieler D, Franke A. Failure of an uncemented thumb carpometacarpal joint ceramic prosthesis. *J Hand Surg Eur.* 2017:1753193416688427.
167. Robinson PM, Muir LT. Foreign body reaction associated with Artelon: report of three cases. *J Hand Surg Am.* 2011;36(1):116-20.
168. Choung EW, Tan V. Foreign-body reaction to the Artelon CMC joint spacer: case report. *J Hand Surg Am.* 2008;33(9):1617-20.
169. Pugliese D, Bush D, Harrington T. Silicone synovitis: Longer term outcome data and review of the literature. *J Clin Rheum.* 2009;15(1):8-11.

170. MacDermid JC, Roth JH, Rampersaud YR, Bain GI. Trapezial arthroplasty with silicone rubber implantation for advanced osteoarthritis of the trapeziometacarpal joint of the thumb. *Can J Surg.* 2003;46(2):103-10.
171. Freeman GR, Honner R. Silastic replacement of the trapezium. *J Hand Surg Br.* 1992;17(4):458-62.
172. Chantelot C, Rtaimate M, Chantelot-Lahoude S, Migaud H, Fontaine C. Intracarpal synovitis related to Dacron interposition after trapeziectomy: A report of three cases. *Chir Main.* 2004;23(4):208-11.
173. Frolich C, Hansen TB. Complications related to metal-on-metal articulation in trapeziometacarpal joint total joint arthroplasty. *J Funct Biomater.* 2015;6(2):318-27.
174. Oka Y, Ikeda M. Silastic interposition arthroplasty for osteoarthrosis of the carpometacarpal joint of the thumb. *Tokai J Exp Clin Med.* 2000;25(1):15-21.
175. Lanzetta M, Foucher G. A comparison of different surgical techniques in treating degenerative arthrosis of the carpometacarpal joint of the thumb. A retrospective study of 98 cases. *J Hand Surg Br.* 1995;20(1):105-10.
176. Hofamann DY, Ferlic DC, Clayton ML. Arthroplasty of the basal joint of the thumb using a silicone prosthesis. Long-term follow-up. *J Bone Joint Surg Am.* 1987;69(7):993-7.
177. Lovell ME, Nuttall D, Trail IA, Stilwell J, Stanley JK. A patient-reported comparison of trapeziectomy with Swanson Silastic implant or sling ligament reconstruction. *J Hand Surg Br.* 1999;24(4):453-5.
178. Gudmundsson G, Jonsson E, Sigurdsson B. Trapezium replacement arthroplasty. *Acta Orthop Scand.* 1985;56(3):245-8.
179. Braun RM. Stabilization of silastic implant arthroplasty at the trapezometacarpal joint. *Clin Orthop Relat Res.* 1976(121):263-70.
180. Pellegrini Jr VD, Burton RI. Surgical management of basal joint arthritis of the thumb. Part I. Long-term results of silicone implant arthroplasty. *J Hand Surg Am.* 1986;11(3):309-24.
181. Sennwald GR, Segmuller G. The value of scapho-trapezio-trapezoid arthrodesis combined with "de la Caffiniere" arthroplasty for the treatment of pan-trapezial osteoarthritis. *J Hand Surg Br.* 1993;18(4):527-32.

182. Karlsson MK, Necking LE, Redlund-Johnell I. Foreign body reaction after modified silicone rubber arthroplasty of the first carpometacarpal joint. *Scand J Plast Reconstr Surg Hand Surg.* 1992;26(1):101-3.
183. Swanson AB, deGoot Swanson G, Watermeier JJ. Trapezium implant arthroplasty. Long-term evaluation of 150 cases. *J Hand Surg Am.* 1981;6(2):125-41.
184. Creighton Jr JJ, Steichen JB, Strickland JW. Long-term evaluation of Silastic trapezial arthroplasty in patients with osteoarthritis. *J Hand Surg Am.* 1991;16(3):510-9.
185. Regis D, Sandri A, Sambugaro E. Incidence of heterotopic ossification after surface and conventional total hip arthroplasty: a comparative study using anterolateral approach and indomethacin prophylaxis. *BioMed Res Int.* 2013;2013:293528.
186. Jennings CD, Livingstone DP. Convex condylar arthroplasty of the basal joint of the thumb: failure under load. *J Hand Surg Am.* 1990;15(4):573-81.
187. Hay EL, Bomberg BC, Burke C, Misenheimer C. Long-term results of silicone trapezial implant arthroplasty. *J Arthroplasty.* 1988;3(3):215-23.
188. Pellegrini Jr VD. Osteoarthritis at the base of the thumb. *Orthop Clin North Am.* 1992;23(1):83-102.
189. Huang K, Hollevoet N, Giddins G. Thumb carpometacarpal joint total arthroplasty: a systematic review. *J Hand Surg Eur Vol.* 2015;40(4):338-50.
190. Brunton LM, Wilgis EF. A survey to determine current practice patterns in the surgical treatment of advanced thumb carpometacarpal osteoarthrosis. *Hand (NY).* 2010;5(4):415-22.
191. Huang K, Hollevoet N, Giddins G. Thumb carpometacarpal joint total arthroplasty: a systematic review. *J Hand Surg Eur .* 2015;40(4):338-50.
192. Diment LE, Thompson MS, Bergmann JHM. Clinical efficacy and effectiveness of 3D printing: a systematic review. *BMJ open.* 2017;7(12):e016891.
193. Soon DS, Chae MP, Pilgrim CH, Rozen WM, Spychal RT, Hunter-Smith DJ. 3D haptic modelling for preoperative planning of hepatic resection: A systematic review. *Ann Med Surg (Lond).* 2016;10:1-7.
194. Chae MP, Rozen WM, Spychal RT, Hunter-Smith DJ. Breast volumetric analysis for aesthetic planning in breast reconstruction: a literature review of techniques. *Gland surg.* 2016;5(2):212-26.

195. Chae MP, Rozen WM, McMenamin PG, Findlay MW, Spychal RT, Hunter-Smith DJ. Emerging Applications of Bedside 3D Printing in Plastic Surgery. *Front Surg*. 2015;2:25.
196. Honigmann P, Sharma N, Okolo B, Popp U, Msallem B, Thieringer FM. Patient-Specific Surgical Implants Made of 3D Printed PEEK: Material, Technology, and Scope of Surgical Application. *BioMed Res Int*. 2018;2018:4520636.
197. Banks J. Adding value in additive manufacturing: researchers in the United Kingdom and Europe look to 3D printing for customization. *IEEE pulse*. 2013;4(6):22-6.
198. Bauermeister AJ, Zuriarrain A, Newman MI. Three-Dimensional Printing in Plastic and Reconstructive Surgery: A Systematic Review. *Ann Plast Surg*. 2016;77(5):569-76.
199. Xie MM, Tang KL, Yuan CS. 3D printing lunate prosthesis for stage IIIc Kienbock's disease: a case report. *Arch Orthop Trauma Surg*. 2018;138(4):447-51.
200. Fedorov A, Beichel R, Kalpathy-Cramer J, Finet J, Fillion-Robin J-C, Pujol S, et al. 3D Slicer as an Image Computing Platform for the Quantitative Imaging Network. *Magn Reson Imaging*. 2012;30(9):1323-41.
201. Smith EJ, Anstey JA, Venne G, RE Elis. Using additive manufacturing in accuracy evaluation of reconstructions from computed tomography. *Proc Inst Mech Eng*. 2013;227(5):551-9.
202. Koo TK, Li MY. A Guideline of Selecting and Reporting Intraclass Correlation Coefficients for Reliability Research. *J Chiropr Med*. 2016;15(2):155-63.
203. McGraw KO, Wong SP. "Forming inferences about some intraclass correlations coefficients": Correction. *Psychol Methods*. 1996;1(4):390-.
204. Martelli N, Serrano C, van den Brink H, Pineau J, Prognon P, Borget I, et al. Advantages and disadvantages of 3-dimensional printing in surgery: A systematic review. *Surgery*. 2016;159(6):1485-500.
205. McMenamin PG, Quayle MR, McHenry CR, Adams JW. The production of anatomical teaching resources using three-dimensional (3D) printing technology. *Anat Sci Educ*. 2014;7(6):479-86.
206. Cone JA, Martin TM, Marcellin-Little DJ, Harrysson OLA, Griffith EH. Accuracy and repeatability of long-bone replicas of small animals fabricated by use of low-end and high-end commercial three-dimensional printers. *Am J Vet Res*. 2017;78(8):900-5.



207. Khalil W, EzEldeen M, Van De Castele E, Shaheen E, Sun Y, Shahbazian M, et al. Validation of cone beam computed tomography-based tooth printing using different three-dimensional printing technologies. *Oral Surg Oral Med Oral Pathol Oral Radiol*. 2016;121(3):307-15.
208. Maschio F, Pandya M, Olszewski R. Experimental Validation of Plastic Mandible Models Produced by a "Low-Cost" 3-Dimensional Fused Deposition Modeling Printer. *Med Sci Monit*. 2016;22:943-57.
209. Loisel F, Chapuy S, Rey PB, Obert L, Parratte B, Tatu L, et al. Dimensions of the trapezium bone: a cadaver and CT study. *Surg Radiol Anat*. 2015;37(7):787-92.
210. Schneider MT, Zhang J, Crisco JJ, Weiss AP, Ladd AL, Nielsen P, et al. Men and women have similarly shaped carpometacarpal joint bones. *J Biomech*. 2015;48(12):3420-6.
211. Crisco JJ, Coburn JC, Moore DC, Upal MA. Carpal bone size and scaling in men versus in women. *J Hand Surg Am*. 2005;30(1):35-42.
212. Conconi M, Halilaj E, Parenti Castelli V, Crisco JJ. Is early osteoarthritis associated with differences in joint congruence? *J Biomech*. 2014;47(16):3787-93.
213. Xu L, Strauch RJ, Ateshian GA, Pawluk RJ, Mow VC, Rosenwasser MP. Topography of the osteoarthritic thumb carpometacarpal joint and its variations with regard to gender, age, site, and osteoarthritic stage. *J Hand Surg Am*. 1998;23(3):454-64.
214. Marzke MW, Tocheri MW, Marzke RF, Femiani JD. Three-dimensional quantitative comparative analysis of trapezium-metacarpal joint surface curvatures in human populations. *J Hand Surg Am*. 2012;37(1):72-6.
215. Ateshian GA, Rosenwasser MP, Mow VC. Curvature characteristics and congruence of the thumb carpometacarpal joint: differences between female and male joints. *J Biomech*. 1992;25(6):591-607.
216. Pellegrini VD. Comparative pathoanatomy of the Asian and Caucasian trapeziometacarpal joint. *Ann Acad Med Singapore*. 1995;24(4 Suppl):21-5.
217. Nufer P, Goldhahn J, Kohler T, Kuhn V, Muller R, Herren DB. Microstructural adaptation in trapezium bone due to subluxation of the thumb. *J Orthop Res*. 2008;26(2):208-16.
218. Van Nortwick S, Berger A, Cheng R, Lee J, Ladd AL. Trapezium topography in thumb carpometacarpal arthritis. *J Wrist Surg*. 2013;2(3):263-70.

219. Pellegrini VD, Jr. Osteoarthritis of the trapeziometacarpal joint: the pathophysiology of articular cartilage degeneration. I. Anatomy and pathology of the aging joint. *J Hand Surg Am.* 1991;16(6):967-74.
220. Rust PA, Ek ETH, Tham SKY. Assessment of normal trapeziometacarpal joint alignment. *J Hand Surg Eur Vol.* 2017;42(6):605-9.
221. Kurosawa K, Tsuchiya I, Takagishi K. Trapezial-metacarpal joint arthritis: radiographic correlation between first metacarpal articular tilt and dorsal subluxation. *J Hand Surg Am.* 2013;38(2):302-8.
222. Edmunds JO. Current concepts of the anatomy of the thumb trapeziometacarpal joint. *J Hand Surg Am.* 2011;36(1):170-82.
223. Bettinger PC, Smutz WP, Linscheid RL, Cooney WP, 3rd, An KN. Material properties of the trapezial and trapeziometacarpal ligaments. *J Hand Surg Am.* 2000;25(6):1085-95.
224. Pellegrini VD, Jr. The ABJS 2005 Nicolas Andry Award: osteoarthritis and injury at the base of the human thumb: survival of the fittest? *Clin Orthop.* 2005;438:266-76.
225. Eaton RG, Lane LB, Littler JW, Keyser JJ. Ligament reconstruction for the painful thumb carpometacarpal joint: a long-term assessment. *J Hand Surg Am.* 1984;9(5):692-99.
226. Cooney WP, 3rd, Chao EY. Biomechanical analysis of static forces in the thumb during hand function. *J Bone Joint Surg Am.* 1977;59(1):27-36.
227. Moore DC, Crisco JJ, Trafton TG, Leventhal EL. A digital database of wrist bone anatomy and carpal kinematics. *J Biomech.* 2007;40(11):2537-42.
228. Wintman BI, Fowler JL, Baratz ME. Traumatic dislocation of trapezium: case report and review of the literature. *Am J Orthop.* 2000;29(3):229-32.
229. Deutch Z, Niedermeier SR, Awan HM. Surgeon Preference, Influence, and Treatment of Thumb Carpometacarpal Arthritis. *Hand (NY).* 2018;13(4):403-11.
230. Ferreres AR, Patti M. Ethical Issues in the Introduction of New Technologies: From Mis to POEM. *World J Surg.* 2015;39(7):1642-8.
231. Kvarnes L, Reikeras O. Osteoarthritis of the carpometacarpal joint of the thumb. An analysis of operative procedures. *J Hand Surg Br.* 10(1):117-20.

232. Field J, Buchanan D. To suspend or not to suspend: A randomised single blind trial of simple trapeziectomy versus trapeziectomy and flexor carpi radialis suspension. *J Hand Surg Eur Vol* 2007; 32: 462-466.
233. Ritchie JF, Belcher HJ. A comparison of trapeziectomy via anterior and posterior approaches. *J Hand Surg Eur Vol* 2008; 33: 137-143.
234. Raven EE, Kerkhoffs GM, Rutten S, Marsman AJ, Marti RK, Albers GH. Long term results of surgical intervention for osteoarthritis of the trapeziometacarpal joint : Comparison of resection arthroplasty, trapeziectomy with tendon interposition and trapezio-metacarpal arthrodesis. *Int Orthop* 2007; 31: 547-554.
235. Gerwin M, Griffith A, Weiland AJ, Hotchkiss RN, McCormack RR. Ligament reconstruction basal joint arthroplasty without tendon interposition. *Clin Orthop* 1997; 42-45.
236. Hart R, Janeček M, Šiška V, Kučera B, Štipčák V. Interposition suspension arthroplasty according to Epping vs Arthrodesis for trapeziometacarpal osteoarthritis. *Eur Surg* 2006; 38: 433-438.
237. Kriegs-Au G, Petje G, Fojtl E, Ganger R, Zachs I. Ligament reconstruction with or without tendon interposition to treat primary thumb carpometacarpal osteoarthritis. A prospective randomized study. *J Bone Joint Surg Am* 2004; 86-a: 209-218.
238. Nilsson A, Wiig M, Alnehill H et al. The Artelon CMC spacer compared with tendon interposition arthroplasty. *Acta Orthop* 2010; 81: 237-244.
239. Tagil M, Kopylov P. Swanson versus abductor pollicis longus arthroplasty in the treatment of osteoarthritis of the trapeziometacarpal joint: A prospective and randomized study in 26 patients. *J Hand Surg Br* 2002; 27 B: 452-456.
240. Livesey JP, Norris SH, Page RE. First carpometacarpal joint arthritis. A comparison of two arthroplasty techniques. *J Hand Surg Br* 1996; 21B:182–188.
241. García-Mas R, Solé Molins X. Partial trapeziectomy with ligament reconstruction – tendon interposition in thumb carpo-metacarpal osteoarthritis. A study of 112 cases. *Chir Main* 2009; 28: 230-238.

242. Atroshi I, Axelsson G, Nilsson EL. Osteotomy versus tendon arthroplasty in trapeziometacarpal arthrosis: 17 patients followed for 1 year. *Acta Orthop Scand* 1998; 69: 287-290.
243. Mureau MA, Rademaker RP, Verhaar JA, Hovius SE. Tendon interposition arthroplasty versus arthrodesis for the treatment of trapeziometacarpal arthritis: A retrospective comparative follow-up study. *J Hand Surg Am* 2001; 26: 869-876
244. Johnston P, Getgood A, Larson D, Chojnowski AJ, Chakrabarti AJ, Chapman PG. De la Caffiniere thumb trapeziometacarpal joint arthroplasty: 16-26 year follow-up. *J Hand Surg Eur Vol.* 2012; 37: 621-624.
245. De la Caffiniere JY, Aucouturier P. Trapezio-metacarpal arthroplasty by total prosthesis. *Hand* 1979; 11: 41-46.
246. Hansen TB, Stilling M. Equally good fixation of cemented and uncemented cups in total trapeziometacarpal joint prostheses. A randomized clinical RSA study with 2-year follow-up. *Acta Orthop* 2013; 84: 98-105.
247. Howard FM, Simpson LA, Belsole RJ. Silastic condylar arthroplasty. *Clin Orthop* 1985; 144-150.
248. Russo S, Bernasconi A, Busco G, Sadile F. Treatment of the trapeziometacarpal osteoarthritis by arthroplasty with a pyrocarbon implant. *Int Orthop* 2016; 40: 1465-1471.
249. Mariconda M, Russo S, Smeraglia F, Busco G. Partial trapeziectomy and pyrocarbon interpositional arthroplasty for trapeziometacarpal joint osteoarthritis: Results after minimum 2 years of follow-up. *J Hand Surg Eur Vol* 2014; 39: 604-610.
250. Richard MJ, Lunich JA, Correll GR. The use of the Artelon CMC spacer for osteoarthritis of the basal joint of the thumb. *J Hand Ther* 2014; 27: 122-125.
251. Clarke S, Hagberg W, Kaufmann RA, Grand A, Wollstein R. Complications with the use of Artelon in thumb CMC joint arthritis. *Hand* 2011; 6: 282-286.
252. Bell R, Desai S, House H, O'Donovan T, Palmer AK. A retrospective multicenter study of the Artelon carpometacarpal joint implant. *Hand* 2011; 6: 364-372.

253. Jewell DP, Brewster MB, Arafa MA. Outcomes of silastic trapezium replacements. *Hand Surg* 2011; 16: 301-305.
254. Lister GD, Kleinert HE, Kutz JE, Atasoy E. Arthritis of the trapezial articulations treated by prosthetic replacement. *Hand* 1977; 9: 117-129.
255. Ho PK, Jacobs JL, Clark GL. Trapezium implant arthroplasty: Evaluation of a semiconstrained implant. *J Hand Surg Am* 1985; 10: 654-660.
256. Sotereanos DG, Taras J, Urbaniak JR. Niebauer trapeziometacarpal arthroplasty: A long-term follow-up. *J Hand Surg Am* 1993; 18: 560-564.
257. Marzke MW, Tocheri MW, Steinberg B, Femiani JD, Reece SP, Lindcheid RL, Orr CM, Marzke RF. Comparative 3D quantitative analyses of the trapeziometacarpal joint surface curvatures among living catarrhines and fossil hominins.

# Appendix

## Appendix 1

	Authors	Level of evidence	Number of arthroplasties (number of patients)	Mean age at surgery	Mean follow up in months	Total number with revision	Most common complication
<b>Trapeziectomy</b>	De Smet and Sioen <sup>158</sup> , 2007	IV	22(22)	61	34	1	NS <sup>®</sup>
	Field and Buchanan <sup>232</sup> , 2007	I	32(32)	55	12	0	Post op infection
	Salem and Davis <sup>34</sup> , 2012	I	59(59)	NS	75.6	2	Persisting pain
	Belcher and Nicholl <sup>35</sup> , 2000	I	19(19)	63	13	0	Persisting pain, neuroma
	Gangopadhyay et al <sup>51</sup> ., 2012	I	53(53)	57	72	2	Persisting pain
	Belcher and Zic <sup>82</sup> , 2001	I	13(13)	56	6	0	Superficial radial nerve neuropraxia
	(231)Kvarnes and Reikeras <sup>231</sup> , 1985	III	12(12)	56	72	0	NA
	Ritchie and Belcher <sup>233</sup> , 2008	I	43(41)	61	33	0	Post op Infection
	Raven et al <sup>234</sup> ., 2007	III	17(17)	58	156	1	Persisting pain
	<b>Trapeziectomy +/- Ligament reconstruction +/- Tendon interposition</b>	De Smet and Sioen <sup>158</sup> , 2007	I	34 (34)	58	26	0
Field and Buchanan <sup>232</sup> , 2007		I	33(33)	55	12	0	Post op infection, Superficial radial nerve neuropraxia

Salem and Davis <sup>34</sup> , 2012	I	55(55)	NS	75.6	1	Persisting pain
Belcher and Nicholl <sup>35</sup> , 2000	I	23(23)	58	13	1	Persisting pain
Gangopadhyay et al <sup>51</sup> ., 2012	I	100(100)	57	72	2	Persisting pain
Gerwin et al <sup>235</sup> ., 1997	I	20(20)	60.9	23	NS	NS
Hart et al <sup>236</sup> ., 2006	I	20(20)	59	81.6	0	Persisting pain
Kriegs- Au et al <sup>237</sup> ., 2004	I	31(31)	59	46.2,50	0	Superficial radial nerve neuropraxia
(103)Nilsson et al <sup>103</sup> ., 2005	II	5(5)	59	36	0	NS
Nilsson et al <sup>238</sup> ., 2010	I	37(37)	61	12	0	NS
Tagil and Kopylov <sup>239</sup> , 2010	I	13(13)	62	43	0	Persisting Pain
Jorheim et al <sup>41</sup> ., 2009	III	40(40)	58	12	0	EPB tendon rupture
Muermans and Coenen <sup>43</sup> , 1998	III	7(7)	55	32	0	NS
Ulrich-Vinther et al <sup>132</sup> ., 2008	III	70(70)	62	12	0	De Quervains tenosynovitis
Schroder et al <sup>48</sup> ., 2002	II	18(18)	63	42	0	subluxation
Mureau et al <sup>153</sup> ., 2001	III	24(17)	62.8	72	0	NS
Hartigan et al <sup>49</sup> ., 2001	III	49(39)	52	69	0	Persisting pain
Lovell et al <sup>177</sup> ., 1999	III	56(56)	NS	62	2	Persisting pain
Alnot and Muller <sup>136</sup> , 1998	III	25(NS)	60.5	42	0	NS
Lehmann et al <sup>56</sup> ., 1998	III	75(75)	64.8	34	0	Complex regional pain syndrome



	Livesey et al <sup>240</sup> , 1996	III	19(17)	59	29, 22	0	Calcification
	Lanzetta and Foucher <sup>175</sup> , 1995	III	44(NS)	56	60	0	Superficial radial nerve neuropraxia
	Conolly and Lanzetta <sup>52</sup> , 1993	III	15(15)	54.5	51.6	2	Persisting pain, Scapho- metacarpal OA
	Amadio and De Silva <sup>53</sup> , 1990	III	7(7)	55	52.6	0	NS
	Burton <sup>39</sup> , 1986	III	25(25)	56	46.8	0	NS
	Amadio et al <sup>53</sup> , 1982	III	25(24)	NS	37	1	De Quevain's tenosynovitis
	Garcia-Mas and Solé Molins <sup>241</sup> , 2009	III	10(NS)	NS	45	0	Post-surgical neuropathy
	Raven et al <sup>234</sup> , 2007	III	18(18)	65	96	0	Post-surgical neuropathy
	Atroshi et al <sup>242</sup> , 1998	III	10(10)	58	12	0	Persisting pain
<b>Arthrodesis/ Joint fusion</b>	Hart et al <sup>236</sup> , 2006	I	20(NS)	59	81.6	0	Persisting pain
	Schroder et al <sup>48</sup> , 2002	II	18(NS)	61	42	0	Non-union
	Mureau et al <sup>243</sup> , 2001	III	32(26)	61.7	88.8	0	Non-union
	Hartigan et al <sup>49</sup> , 2001	III	58(48)	51	69	0	Non-union
	Conolly and Lanzetta <sup>52</sup> , 1993	III	16(NS)	54.5	51.6	2	Non-union
	Amadio and De Silva <sup>53</sup> , 1990	III	16(12)	55.2	52.6	1	Non-union
	Burton <sup>57</sup> , 1986	III	2(2)	45	46.8	0	NS
	Kvarnes and Reikeras <sup>251</sup> , 1985	III	18(NS)	56	72	0	Fibrous union

Raven et al <sup>234</sup> , 2007	III	28(28)	61	108	3	Persisting pain
--------------------------------------	-----	--------	----	-----	---	--------------------

**Appendix 1. Study Characteristics non-implant arthroplasty literature and main complications**

⊙ Not stated

\* Not applicable1.

## Appendix 2

	<b>Authors</b>	<b>Level of evidence</b>	<b>Number of implant arthroplasties (Number of patients)</b>	<b>Mean age at surgery</b>	<b>Mean follow up in months</b>	<b>Total number with implant failure</b>	<b>Most common complication causing implant revision or failure</b>
<b>Total Joint Replacement</b>							
<b>De la Caffiniere prosthesis</b>	Johnston et al <sup>244</sup> , 2012	IV	39 (26)	57	228	6	Persisting pain
	De Smet and Sioen <sup>158</sup> , 2007	IV	43 (40)	54	26	1	Persisting pain
	Van Cappelle et al <sup>108</sup> ., 1999	IV	77 (63)	62	102	16	Aseptic loosening
	Chakrabarti et al <sup>162</sup> ., 1997	IV	93(71)	57	132	11	Aseptic loosening
	Sennwald and Segmuller <sup>181</sup> , 1993	IV	13 (13)	63	44	2	Aseptic loosening
	Nicholas and Calderwood <sup>110</sup> , 1992	IV	20 (17)	57.25	64.2	2	Dislocation & Persisting pain
	Sondergaard et al <sup>111</sup> ., 1991	IV	25 (23)	60	108	3	Aseptic loosening
	Albertoni et al <sup>112</sup> ., 1992	III	15 (14)	63	88	2	Dislocation
	Boeckstyns et al <sup>113</sup> , 1989	IV	31 (28)	62	48	7	Aseptic loosening
	August et al <sup>114</sup> , 1984	IV	21 (20)	57	15.2	5	Aseptic loosening
	De la Caffiniere and Aucouturier <sup>245</sup> , 1979	IV	34 (29)	59	24	NA	Aseptic loosening

<b>De la Caffiniere prosthesis, Ledoux Prosthesis</b>	Wachtl et al <sup>156</sup> , 1998	III	43(NS),45(NS)	61	63,25	10	Aseptic loosening
<b>Ivory TMC prosthesis</b>	Spaans et al <sup>115</sup> , 2016	IV	20 (20)	60	37	3	Dislocation
	Goubau et al <sup>116</sup> , 2013	IV	22 (22)	66	67	1	Dislocation
<b>ARPE TM prosthesis</b>	Robles-Molina et al <sup>117</sup> , 2017	III	31(31)	56.37	56	3	Dislocation
	Martin-Ferrero <sup>118</sup> , 2014	IV	65(60)	58	120	7	Aseptic loosening
	Apard and Cast <sup>119</sup> , 2009	IV	43(43)	59.4	86	6	Aseptic loosening
	Eecken et al <sup>120</sup> , 2012	IV	49(41)	55	72	6	Dislocation
	Goddard <sup>121</sup> , 2013	IV	227 (202)	58.8	93.6	16	Dislocation, Aseptic loosening
<b>Roseland prosthesis</b>	Semere et al <sup>122</sup> , 2015	IV	64(51)	71.3	150	4	Dislocation
	Zollinger et al <sup>123</sup> , 2008	IV	32(27)	NS	39	3	Dislocation
<b>Moje Acamo CMC1 prosthesis</b>	Kollig et al <sup>166</sup> , 2017	IV	29(28)	62	50	15	Aseptic loosening
	Kaszap et al <sup>124</sup> , 2012	III	12(12)	64	50	5	Aseptic loosening
	Hansen and Vainorius <sup>133</sup> , 2008	IV	9(9)	58.3	12	3	Osteolysis
<b>Rubis II prosthesis</b>	Dehl et al <sup>125</sup> , 2017	IV	115 (95)	61	120	11	Dislocation
<b>Motec titanium CMC prosthesis</b>	Thillemann et al <sup>126</sup> , 2016	IV	42 (40)	59	26	17	Aseptic loosening

<b>Motec titanium CMC prosthesis, Motec PE cemented prosthesis, Elektra PE cemented prosthesis, Elektra bimetal prosthesis, Elektra chrome-cobalt prosthesis</b>	Hansen et al <sup>127</sup> , 2013	III	118(112)	60.8	34.6	28	Aseptic loosening
<b>Elektra PE cemented prosthesis,</b>	Hansen and Stilling <sup>246</sup> , 2013	I	32/(28)	56	24	2	Dislocation
<b>Elektra chrome-cobalt uncemented prosthesis</b>	Klahn et al <sup>130</sup> , 2012	IV	39(37)	56.5	48	17	Aseptic loosening
	Hernandez-Cortes et al <sup>131</sup> , 2012	IV	19(19)	57	29	4	Persisting pain
	Ulrich-Vinther et al <sup>132</sup> , 2008	III	42(42)	62	12	1	Dislocation
	Hansen and Snerum <sup>133</sup> , 2008	IV	17(16)	54	35	5	Aseptic loosening
	Regnard <sup>134</sup> , 2006	IV	100(100)	59	53	19	Aseptic loosening
<b>MAIA prosthesis</b>	Bricout and Rezzouk <sup>128</sup> , 2016	IV	156(139)	62.7	37.8	12	Dislocation

	Toffoli and Teissier <sup>161</sup> , 2017	IV	96(80)	68	76	4	Aseptic loosening
<b>GUEPAR prosthesis</b>	Alnot and Muller <sup>136</sup> , 1998	III	90(90)	60.5	69	3	Aseptic loosening
<b>GUEPAR prosthesis (2nd generation)</b>	Lemoine et al <sup>137</sup> , 2009	IV	72(57)	55	61	1	Persisting pain
<b>Avanta SRTM TMC prosthesis</b>	Van Rinj and Gosens <sup>139</sup> , 2010	IV	15(13)	58	36	2	Peri- prosthetic fracture, infection
	Pendse et al <sup>162</sup> , 2009	IV	62(50)	64.5	36	7	Aseptic loosening
	Perez-Ubeda et al. <sup>138</sup> , 2003	IV	20(19)	65	33	4	Aseptic loosening
<b>Braun- Cutter TM joint prosthesis</b>	Badia <sup>141</sup> , 2006	IV	26(25)	71	59	1	Dislocation
<b>The cementless trapeziometacarpal prosthesis</b>	Hannula and Nahigian <sup>142</sup> , 1999	IV	42(36)	58	47	5	Aseptic loosening
<b>Mayo Implant</b>	Amadio and De Silva <sup>53</sup> , 1990	III	12(10)	55.2	52.6	1	Aseptic loosening
	Cooney et al <sup>226</sup> , 1987	IV	62(57)	62	55.2	12	Aseptic loosening
<b>Steffee Prosthesis</b>	Ferrari and Steffee <sup>145</sup> , 1986	IV	45(38)	61	51	3	Aseptic loosening
<b>Bichat Total Arthroplasty</b>	Alnot and Saint Laurent <sup>144</sup> , 1985	IV	17(15)	56	36	3	Periprosthetic fracture

<b>Hemiarthrop</b>							
<b>lasty</b>							
<b>Pyrohemisph</b>	Stillwater et	IV	31(26)	58	13	1	Subluxation
<b>ere TM</b>	al <sup>146</sup> ., 2017						
<b>prosthesis</b>							
	Martinez de	IV	54(49)	59	20	14	dislocation
	Aragon et						
	al <sup>148</sup> ., 2009						
<b>BioPro</b>	Pritchett and	IV	143(124)	63	72.1	6	Aseptic
<b>Modular</b>	Habryl <sup>150</sup> .,						loosening
<b>thumb</b>	2012						
<b>prosthesis</b>							
<b>Swanson</b>	Phaltankar and	IV	19(18)	59	34	1	Dislocation
<b>titanium</b>	Magnussen <sup>152</sup> ,						
<b>convex</b>	2003						
<b>condylar</b>							
<b>prosthesis</b>							
	Naidu et al <sup>153</sup> .,	IV	20(47)	55	24	10	Persisting
	2006						pain
<b>Silicone</b>	Conolly and	III	32(NS)	54.5	51.6	5	Dislocation
<b>Metatarso-</b>	Lanzetta <sup>52</sup> ,						
<b>phalangeal</b>	1993						
<b>implant</b>							
<b>Convex</b>	Jennings and	III	19(43)	63.3	54	4	Persisting
<b>condylar</b>	Livingstone <sup>186</sup> ,						pain
<b>silicone</b>	1990						
<b>implant</b>							
	Amadio and	III	6(NS)	55.2	52.6	0	Persisting
	De Silva <sup>53</sup> ,						pain, Implant
	1990						fracture
	Howard et	IV	40(30)	62.3	15.5	1	Persisting
	al <sup>247</sup> , 1985						pain
	Swanson et	IV	150(121)	54	28	5	Dislocation
	al <sup>183</sup> , 1981						
	Hook and	IV	7(7)	60	26	1	Dislocation
	Stanley <sup>60</sup> , 1986						
<b>Ascension</b>	Aita et al <sup>149</sup> .,	II	53(45)	63.2	42.1	0	Dislocation
<b>implant</b>	2016						

<b>Interposition</b>							
<b>with partial</b>							
<b>trapezial</b>							
<b>resection</b>							
<b>Pyrocardan Implant</b>	Russo et al <sup>248</sup> , 2016	IV	36(36)	58.5	31.5	2	Dislocation
<b>Pyrocardan Implant, PyroDisk</b>	Odella et al <sup>89</sup> , 2014	IV	59(59)	62	42	4	Persisting pain
<b>PyroDisk</b>	Mariconda et al <sup>249</sup> , 2014	IV	27(25)	63	34	0	Persisting pain
	Barrera-Ochoa et al <sup>90</sup> , 2014	IV	19(19)	61	60	2	Subluxation
<b>Polylactic acid (PLLA) Implant</b>	Pereira et al <sup>99</sup> , 2015	IV	12(12)	60	20	6	Persisting pain
	Diaconu et al <sup>101</sup> , 2011	IV	25(25)	64.5	14	1	Infection
<b>Polyvinyl alcohol (PVA) Implant</b>	Taleb et al <sup>96</sup> , 2014	IV	7(7)	61	30	0	Persisting pain
<b>Artelon spacer</b>	Richard et al <sup>250</sup> , 2014	IV	8(6)	60.8	39.3	4	Osteolysis, foreign body reaction
	Blount et al <sup>102</sup> , 2013	III	32(32)	NS	30	12	Persisting pain
	Clarke et al <sup>251</sup> , 2011	IV	29(29)	51	8	4	Osteolysis
	Bell et al <sup>252</sup> , 2011	IV	49(46)	57.8	48	4	Persisting pain
	Nilsson et al <sup>238</sup> , 2010	I	72(72)	60	12	6	Foreign body reaction, infection, persisting pain
	Jorheim et al <sup>41</sup> , 2009	III	13(13)	54	13	2	Persisting pain



	Nilsson et al <sup>103</sup> , 2005	II	10(15)	60	36	1	Persisting pain
<b>Pyrocarbon Spherical Implant</b>	Bengezi and Vo <sup>91</sup> , 2014	IV	24(23)	56	18.2	0	Persisting pain
<b>Orthrospher e</b>	Adams et al <sup>93</sup> , 2009	IV	50(49)	59	36	3	Persisting pain
	Athwal et al <sup>94</sup> , 2004	IV	7(7)	52	33	5	Implant subsidence
<b>Ashworth Implant</b>	Minami et al <sup>59</sup> , 2005	IV	12(10)	66.2	183	8	Fracture implant
	Oka and Ikeda <sup>174</sup> , 2000	IV	16(16)	59.6	54	2	Fracture implant
	Lanzetta and Foucher <sup>175</sup> , 1995	III	14(NS)	56	60	4	Subluxation
	Karlsson et al <sup>182</sup> , 1992	IV	20(19)	56	54	11	Persisting pain
	Ashworth et al <sup>97</sup> , 1977	IV	49(42)	55	31	2	Fracture implant
<b>Silicone Ball</b>	Nakajima et al <sup>92</sup> , 1996	IV	7(7)	56	30	1	Dislocation
<b>Kessler Implant</b>	Engel et al <sup>98</sup> , 1982	IV	25(23)	59.3	24	0	Subluxation
<b>Proplast stabilised trapezial implant Interposition total trapezial replacement</b>	Kessler et al <sup>95</sup> , 1984	IV	45(40)	40	24.7	4	Dislocation
<b>Pi2</b>	Agout et al <sup>72</sup> , 2016	IV	42(39)	63	125.49	0	Osteolysis
	Szalay et al <sup>75</sup> , 2013	IV	60(60)	58.5	23.6	6	Dislocation
	Maru et al <sup>74</sup> , 2012	III	18(NS)	62	20	6	Dislocation

	Colegate- Stone et al <sup>73</sup> , 2011	III	24(24)	62	12	5	Dislocation
	Ardouin and Bellemère <sup>71</sup> , 2011	IV	42(39)	63	62.4	1	Persisting pain
	Van Aaken et al <sup>76</sup> , 2016	IV	45(41)	60	29	12	Dislocation
<b>Tie-In trapezial Implant</b>	Avisar et al <sup>67</sup> , 2015	IV	28(22)	66	18	2	Dislocation
<b>Polyethylene mesh Implant</b>	Spaans et al <sup>77</sup> , 2014	IV	70(66)	NS	18	8	Foreign body reaction
<b>Swanson Trapezium Implant</b>	Jewell et al <sup>253</sup> , 2011	IV	86(63)	66	46	1	Dislocation
	Taylor et al <sup>114</sup> , 2005	III	22(NS)	66	42	1	Dislocation
	MacDermid et al <sup>170</sup> , 2003	IV	30(25)	64	78	6	Fracture implant
	Tagil and Kopylov <sup>239</sup> , 2002	I	13(13)	62	41	1	Dislocation
	Bezwada et al <sup>58</sup> , 2002	IV	62(58)	NS	196	4	Fracture implant
	van Cappelle et al <sup>164</sup> , 2001	IV	45(35)	61	165.6	12	Dislocation
	Lovell et al <sup>177</sup> , 1999	III	58(NS)	NS	62	4	Subluxation
	Lehmann et al <sup>56</sup> , 1998	III	27(NS)	65.4	67	NA	NA
	Lanzetta and Foucher <sup>175</sup> , 1995	III	39(NS)	56	60	4	Fracture implant
	Freeman and Homer <sup>112</sup> , 1992	IV	43(37)	60.5	66	4	Foreign body reaction

	Creighton Jr et al <sup>184</sup> , 1991	IV	151(124)	62	51	2	Osteolysis
	Sollerman et al <sup>193</sup> , 1988	IV	39(33)	58	144	NS	Subluxation
	Hay et al <sup>187</sup> , 1988	IV	64(52)	58	52.8	5	Subluxation
	Amadio et al <sup>53</sup> , 1982	III	25(21)	57	31	0	Subluxation
	Lister et al <sup>255</sup> , 1977	IV	36(31)	NS	27.4	6	Subluxation
	Gudmundsson et al <sup>178</sup> , 1985	IV	34	59	78	0	Fracture implant
<b>Swanson Trapezial Implant, Niebauer Implant, Kessler implant</b>	Hofamann et al <sup>176</sup> , 1987	IV	20(18)	61	97.2	1	Subluxation
<b>Swanson Trapezial Implant, Eaton Trapezial Implant</b>	Ho et al <sup>155</sup> , 1985	IV	29(25)	62	31	2	Dislocation
<b>Eaton Trapezial Implant</b>	Eaton <sup>62</sup> , 1979	IV	50(46)	55	20.9	2	Dislocation
<b>Gelfoam Spacer</b>	Nusem and Goodwin <sup>79</sup> , 2003	IV	35(30)	60	60	0	Persisting pain
	Schacherer and Schneider <sup>78</sup> , 1991	IV	66(66)	55	48	1	Infection
<b>Helal Prosthesis</b>	O'Leary et al <sup>70</sup> , 2002	IV	26(23)	63	59	1	Persisting pain
	Grange and Helal <sup>68</sup> , 1983	IV	25(22)	56.8	13.6	7	Subluxation

	Helal and McPherson <sup>69</sup> , 1989	IV	40(31)	55.4	32	4	Persisting pain
<b>Permacol Implant</b>	Belcher and Zic <sup>82</sup> , 2001	I	13(13)	59	6	3	Persisting pain
<b>Gore-Tex</b>	Greenberg et al <sup>83</sup> , 1997	IV	34(31)	57	42	1	Infection
<b>Gore-Tex, Marlex</b>	Muermans and Coenen <sup>43</sup> , 1998	III	19(NS)	55	32	3	Foreign body reaction
<b>Niebauer Implant</b>	Sotereanos et al <sup>256</sup> , 1993	IV	30(27)	61	108	2	Dislocation
	Adams et al <sup>65</sup> , 1990	IV	22(18)	NS	28.8	3	Dislocation
	Rajan et al <sup>66</sup> , 1982	IV	16(16)	58	13	1	Subluxation
	Poppen and Niebauer <sup>64</sup> , 1978	IV	20(15)	58.5	48	3	Foreign body reaction
<b>Tecoflex Polyurethane Implant</b>	Sollerman et al <sup>61</sup> , 1993	IV	25(25)	61	36	3	Dislocation
<b>Silicone Trapezium Implant</b>	Conolly and Lanzetta <sup>52</sup> , 1993	IV	53(NS)	54.4	51.6	8	Dislocation
<b>Acellular dermal allograft (GraftJacket )</b>	Kokkalis et al <sup>87</sup> , 2009	IV	100(89)	57	30	2	Persisting pain
<b>Dow Corning Silastic Trapezium Implant Interposition with no trapezium resection</b>	Hook and Stanley <sup>60</sup> , 1986	IV	13(13)	58	10	0	Persisting pain

<b>Articulinx</b>	van der Veen	IV	8(8)	56	24	2	Dislocation.
<b>Intermetacarpal Cushion</b>	et al <sup>105</sup> , 2013						Persisting pain
<b>Silicone rubber sponge interposition arthroplasty</b>	Dickson <sup>106</sup> , 1976	IV	16(12)	NS	38.4	1	Persisting pain

**Appendix 2: Study Characteristics implant arthroplasty literature and main implant related complications**

© Not stated

\* Not applicable

